

Peripheral limb ischaemia from peripherally inserted central catheter (PICC) line insertion in an extreme preterm neonate – Case report

James Mackintosh¹, Cyra Asher², Puneet Nath³

¹Warwick Medical School, Coventry, UK

²University of Oxford, Oxford, UK

³University Hospital Coventry and Warwickshire, Coventry, UK

Abstract

Background: There is extensive literature on incorrect positioning of peripherally inserted central catheter (PICC) line tips, particularly concerning advancement into the right atrium causing cardiac tamponade. However, there is little literature concerning inadvertent arterial cannulation as a complication of PICC insertion and what steps could be taken to prevent it.

Case presentation: An extreme preterm neonate had a PICC line inserted into the left arm to provide central venous access for parenteral nutrition. Following the insertion, an anteroposterior chest X-ray was used to confirm positioning and was deemed acceptable. It was reviewed by a consultant radiologist the next day. Fifteen hours after insertion, the nursing staff raised concerns that the fingertips on the neonate's left hand appeared dusky and were getting progressively darker. Upon removal of the PICC line, an upper limb Doppler was performed, showing severe stenosis of the brachial artery with no flow distally in the radial or ulnar arteries.

Conclusions: This case demonstrates that glyceryl trinitrate (GTN) patches can be used to reverse peripheral ischaemia in neonates with good effect. After reflecting on the case, we decided that monitoring distal limb colour and perfusion should be part of observations in neonates with central venous lines *in situ* and documentation should reflect this. Furthermore, when concerns are raised about distal perfusion in a limb with lines *in situ*, all lines should be removed immediately. We would like to emphasise that it is of vital importance to promote a culture of openness where all team members are empowered to raise concerns about patient safety.

Keywords

Neonatal, PICC lines, peripheral ischaemia, GTN, case report.

Corresponding author

Dr James Mackintosh, Warwick Medical School, Gibbet Hill Rd, CV4 7AL, Coventry, UK; email: james.mackintosh3@nhs.net.

How to cite

Mackintosh J, Asher C, Nath P. Peripheral limb ischaemia from peripherally inserted central catheter (PICC) line insertion in an extreme preterm neonate – Case report. *J Pediatr Neonat Individual Med.* 2022;11(2):e110225. doi: 10.7363/110225.

Introduction

Peripherally inserted central catheter (PICC) lines are peripherally inserted via an upper or lower limb vein and then threaded to the vena cava [1]. They are used in extreme preterm and extremely low birth weight neonates for central venous access for parenteral nutrition, fluids and medications.

Literature suggests that determining the positioning of the tip of a PICC line is difficult [2, 3]. As of 2017, 83% of Neonatal Units in England and Wales use PICC lines. Of these, all Units use plain film radiographs to determine tip position. Only 35% of the Units use contrast [4]. Evidence suggests that using contrast improves the accuracy of tip position assessment [3, 5]. If the PICC line is placed incorrectly, it can cause pericardial effusions, cardiac tamponade, and vascular compromise [1, 6-10].

There is limited literature about cases of PICC lines inserted into arteries. However, given the poor accuracy for determining the positioning of PICC lines, it is clearly an issue that clinicians need to be aware of and it may be currently underreported. Inadvertent medication administration or total parenteral nutrition (TPN) infusion into the artery can cause acute ischaemia and digital gangrene [11].

Case presentation

A preterm baby was born at 25⁺⁰ weeks via emergency lower segment c-section due to cord prolapse. The baby was born in poor condition and required stabilisation and ventilation support. The

Apgar score at 1 minute was 3, this improved to 7 and 8 at 5 and 10 minutes, respectively. The baby was transferred to the Neonatal Unit and was commenced on nasal continuous positive airway pressure (nCPAP). The neonate had umbilical venous and arterial lines inserted for fluids, parenteral nutrition and medications. The neonate required parenteral nutrition over enteral due to their gestational age. The UK National Institute for Health and Care Excellence (NICE) recommends giving parenteral nutrition to neonates before 31⁺⁰ weeks [12].

It is usual practice to insert a PICC line to replace the umbilical venous catheter (UVC) as soon as practical. The decision was made to do this on day 6 of life in this case.

At 21:00 hours the PICC line was inserted into the left arm at the antecubital fossa using sterile technique. The PICC line threaded well, but the insertion site bled for 10-15 mins. Pressure was applied to stop the bleeding and during this time the arm and fingers were visualised to ensure that they were pink and well perfused. It was confirmed that there was no blanching. Once the bleeding had stopped, the insertion site was dressed, a chest X-ray was requested, and the Local Safety Standards for Invasive Procedures (LocSSIP) checklist was completed. At this time there was a discussion about the cause of the prolonged bleeding. It was suggested that it could be due to thrombocytopenia. However, the neonate's platelet count (72 x 10⁹/L) was not sufficiently low to cause this type of bleeding. Reduced platelet counts are somewhat common in babies in the Neonatal Intensive Care Unit (NICU). One review found that between 22-35% of babies admitted to NICUs were thrombocytopenic and 6% of premature neonates admitted had a severe thrombocytopenia (platelet count < 50 x 10⁹/L) [13]. However, it would require platelet levels < 25 x 10⁹/L to cause the type of prolonged bleeding witnessed in this case.

On review of chest X-ray, the PICC line position appeared to be in an acceptable place, with the tip at the midline of T2 over the left brachiocephalic vein (**Fig. 1**). The line passed from the left limb, through the axilla and into the thorax. There were no kinks or deviations in the line. Upper limb PICC line tips should be above T4 and not over the cardiac shadow [14]. The UVC was removed and the PICC was used to infuse TPN. Medications were not administered through the PICC line.

The next day, 15 hours after the PICC line insertion, concerns were raised by nursing staff that the fingers on the left hand appeared dusky. The

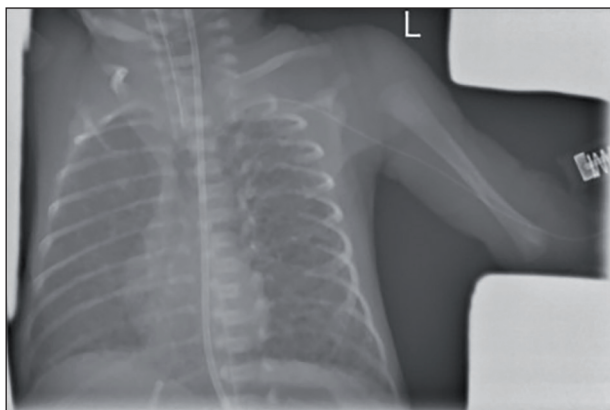


Figure 1. Chest X-ray: showing position of peripherally inserted central catheter (PICC) line.

neonate's left arm was reviewed by an advanced neonatal nurse practitioner (ANNP) and neonatal consultant. The fingers appeared pink with the fingertips looking dusky. The fingers were noted to be warm. The decision was made to review again and continue monitoring the affected hand. The baby had a peripheral cannula and the PICC line *in situ* in their left arm.

A further review was conducted 1 hour later, the fingers continued to look dusky. The X-ray was reviewed to check the PICC line position. It was felt that the X-ray showed that the PICC line appeared to be in the correct place. The report from radiology stated that the tip of the left arm long line is projected over the left brachiocephalic vein. It was thought that the duskiness could be due to the intravenous cannula dressing, as such the peripheral cannula was removed from the left hand. The team continued to closely monitor the situation.

An hour later the ANNP and consultant reviewed the hand again and found no change. They requested another consultant review. A glyceryl trinitrate (GTN) patch was suggested, but not administered.

The neonate was reviewed on the evening handover, 3 hours after the previous review. There was an increased dusky appearance to all fingertips on the left hand and had clearly worsened since the review (**Fig. 2**). The team decided to remove the PICC line, commence a GTN patch and re-obtain venous access. Over 20 hours after insertion, at 17:25 hours, the PICC line was removed.

The neonate's mother was initially updated by a nurse over the phone regarding the PICC line removal. The consultant had a discussion with her the following day when she visited, and duty of candour was performed.

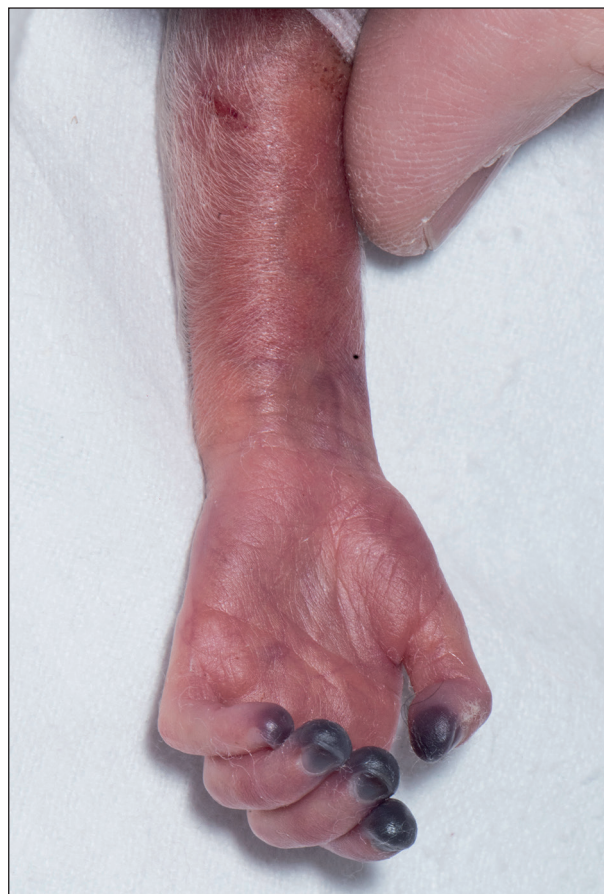

Figure 2. Ventral left forearm and hand.

An upper limb Doppler and medical photography were requested and were performed the next day. The case was reported to the Serious Incident Group for investigation. The neonatal team reviewed the case and made an action plan to prevent future incidents.

Unfortunately, the neonate continued to have issues with vascular access and a subsequent PICC line extravasated and had to be removed. This caused significant anxiety for the neonate's mother.

Diagnostic assessment

A plain radiograph was used to assess the positioning of the PICC line. Plain film radiographs are used to determine the correct depth and ensure that it is in a central location. However, it cannot determine whether the line is in the venous or arterial circulation [15].

X-ray is shown in **Fig. 1**.

Assessing the placement of a PICC line using plain radiographs alone has been shown to be unreliable. In one study, neonatologists only agreed on the positioning of PICC lines on

radiographs 62% of the time and disagreed with their own assessment 27% of the time when shown an identical radiograph [2]. Studies have shown improved accuracy if using contrast to enhance plain film radiographs when determining PICC line tip positioning [3, 5]. However, even with contrast, it can be difficult to identify this in smaller infants [3, 16]. The use of contrast does not aid differentiation between line placement in veins or arteries.

Guidelines from another UK Neonatal Operational Delivery Network state that venous upper limb left sided PICC lines should cross the midline [16]. The tip of the PICC line shown on the chest X-ray in **Fig. 1** does not appear to cross the midline. However, the chest X-ray in question was reported as rotated. This reduces the accuracy of determining the location of the PICC line tip [16].

An upper limb Doppler of arteries in the left limb was performed the day after removing the PICC line. In the brachial artery, the proximal to middle segments were patent with high resistance flow waveform suggesting distal severe stenosis or occlusion. Flow in the distal segment could not be seen, suggesting that it was likely occluded. No flow could be seen in the radial and ulnar arteries. This indicates that the PICC line had been inserted arterially and was responsible for the reduction in perfusion to the digits of the left hand.

Therapeutic intervention

The initial treatment was removing the line to prevent further damage. After this a GTN patch was administered to treat the peripheral ischaemia. There have been numerous case reports recommending the use of GTN patches to reverse peripheral ischaemia in neonates, sometimes with much success [17-23]. However, there are no trials published and it is not licenced for this use in the British National Formulary (BNF). Despite this, there are recommendations for its use in a number of UK Local Trust guidelines [24-25].

Follow-up and outcome

The colour of the digits of the left hand improved steadily after the PICC line was removed and GTN was started (**Fig. 3** and **Fig. 4**). The neonate was transferred to another hospital and returned to the base hospital after 6 weeks. When reviewed, only the tip of the index finger remained black (**Fig. 5**).

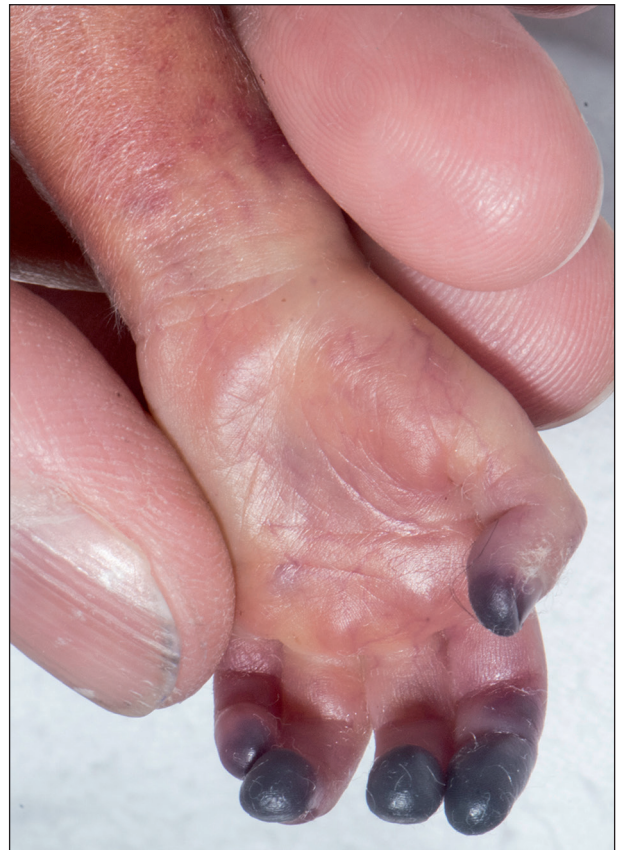

Figure 3. Palmar left hand.

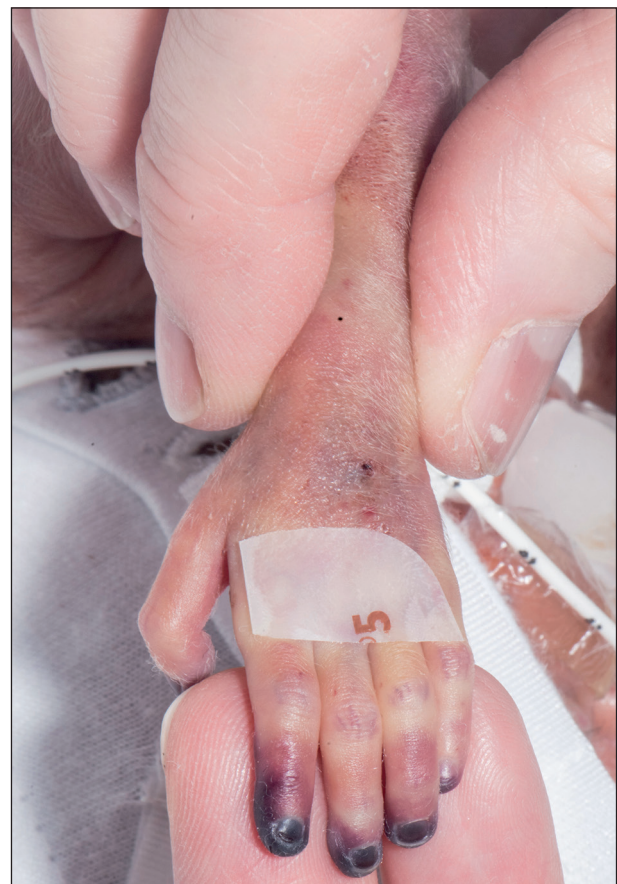

Figure 4. Dorsal left hand.

A repeat Doppler of the upper limb was performed 10 weeks after the PICC insertion. The brachial, radial and ulnar arteries were clear with good triphasic flow throughout. This was consistent with the clinical improvement in the colour of the digits. Eventually, the distal 2 mm of the index fingertip was lost (**Fig. 6**). The long-term effect of this has yet to be seen. However, the outcome appears to be good given the nature of the injury and range of possible outcomes and amount of tissue lost.

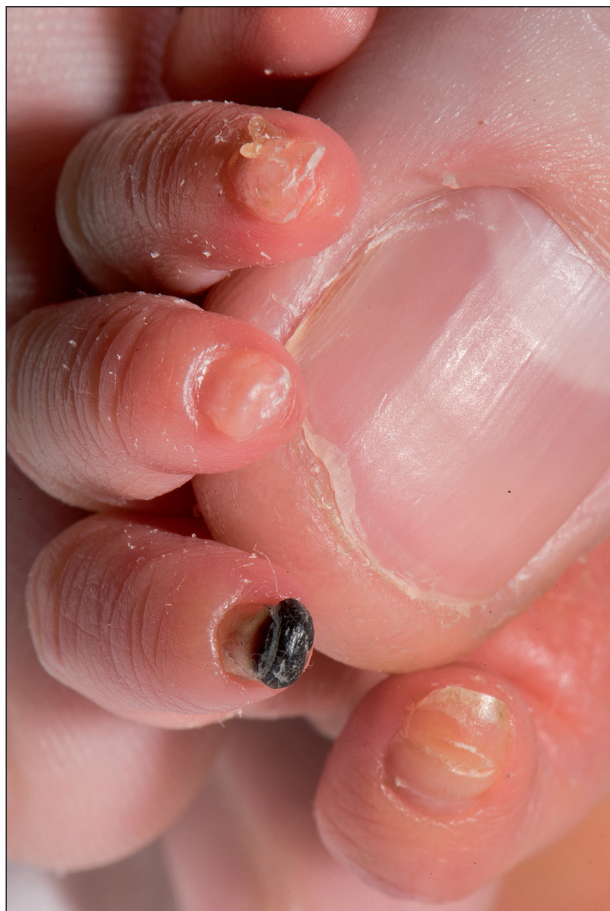

Figure 5. Follow-up left hand: black fingertip.

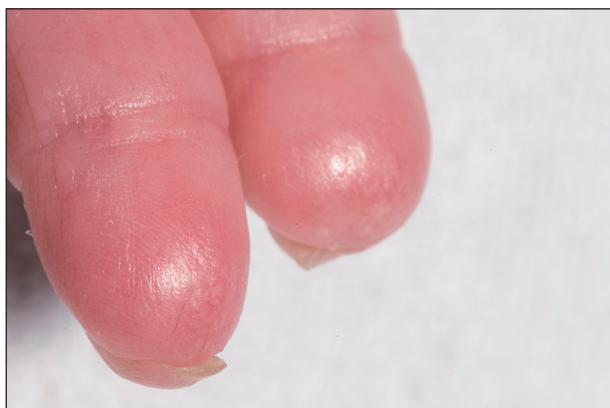

Figure 6. Follow-up left hand: lost fingertip.

Discussion

The first reported case of inadvertent arterial cannulation with a PICC line in a neonate was published in 2015 [26]. There have been a handful of similar cases reported since [21-23].

There are several locations for PICC line insertion where arteries lie in close proximity to the veins. In the antecubital fossa the brachial artery lies between the basilic and cephalic veins [14]. In the anatomical snuffbox the cephalic vein runs alongside the radial artery, and in the first webspace the princeps pollicis artery runs with the vein. This increases the chance of accidental arterial cannulation. While extensive knowledge of the relevant anatomy is paramount to understanding the risks of inadvertent arterial cannulation, it must be noted that abnormal vasculature and anatomical variants are possible. As such it is important to recognise the clinical signs of incorrect positioning. Signs of inadvertent arterial cannulation include pulsation in the line or introducer, blanching of the skin around the insertion point or limb distally, and arterialised blood in the needle or line, which can be determined by colour or blood gas testing [14]. However, visible pulsations are less easily seen in unwell patients such as this neonate. In this case blanching of the skin was looked for and was not observed.

Blood gas testing on blood in the needle or line is not routinely performed during PICC insertion. However, it may be a simple and inexpensive method for detecting inadvertent arterial cannulation. Doppler ultrasound can also be used to accurately determine whether the vessel used for access is venous or arterial [27]. The use of ultrasound requires a suitably trained operator. It does not expose the neonate to radiation and can be done quickly at the bedside. Literature from centres that routinely use periprocedural ultrasound during PICC placement suggest that its use makes misplacing an upper limb line into the brachial artery a rare occurrence [28].

Guidelines from another Neonatal Operational Delivery Network state that possible signs of mistaken arterial insertion of a PICC line include bleeding excessively at insertion site and digits becoming pale or dusky after starting the infusion [16]. There is little literature on the subject. Further research confirming that prolonged bleeding is highly predictive of incorrectly inserting the line into an artery could be useful in informing future

practice. However, more common causes of prolonged bleeding would need to be ruled out first. These include coagulopathies, vitamin K deficiency and thrombocytopenia [29].

The neonatal team has discussed the case following serious incident reporting. The outcomes were presented at a Quality Innovation Productivity and Prevention (QIPP) meeting. In future, the condition of the limb will be documented on the LocSSIP for bruising, perfusion and colour before inserting a central catheter. The LocSSIP form has been appropriately updated to facilitate this. The limb condition will be monitored on the observation chart for all central venous and arterial catheters to ensure that there are no changes in colour or perfusion. If identified, there should be immediate escalation to members of the team and removal of the line.

In hindsight it would have been more appropriate to remove the PICC line along with the peripheral cannula when an issue had been identified. The team discussed this, and it has been decided that all lines will be removed from a limb when there are clinical signs of peripheral ischemia. This should allow for the source of any issue, whether it be perfusion, swelling or inflammation, to be corrected immediately after identification. The challenges of obtaining access in premature infants can encourage clinicians to persevere with the access that has already been obtained rather than immediately remove it.

At the QIPP meeting it was agreed that the team already has an open culture, good work environment and everyone is happy to ask and challenge when they have concerns. However, this is a useful opportunity to reinforce this message and foster good practice.

Patient's perspective

“They initially told me that the fingers had gone dusky, then they said that they were blue. I was shocked when I saw that they were jet black. I think if I'd have been told that they were turning black I would have thought frostbite and losing fingers right away. I think they downplayed how serious it was. It would have been a nasty shock at some point no matter how they told me, but the experience made me trust the team less.

I was angry. I think it could have been prevented and they should have acted quicker when the fingers started getting dusky. I wouldn't let them anywhere near him with a needle. After a while I became less

angry, and I was able to think it through and see that due to his size getting the line in the right place was difficult.

It's really important to me that something positive comes from this bad experience. It's good to see that because of what happened to him they've changed things. It means that it won't happen to someone else's baby. When he's older I want to show him this, so he can see the positive changes that came from what happened to him.”
– Patient's mother

Abbreviations

| | |
|----------|---|
| ANNP: | advanced neonatal nurse practitioner |
| BNF: | British National Formulary |
| GTN: | glyceryl trinitrate |
| LocSSIP: | Local Safety Standards for Invasive Procedures |
| nCPAP: | nasal continuous positive airway pressure |
| NICE: | National Institute for Health and Care Excellence |
| NICU: | Neonatal Intensive Care Unit |
| PICC: | peripherally inserted central catheter |
| QIPP: | Quality Innovation Productivity and Prevention |
| TPN: | total parenteral nutrition |
| UVC: | umbilical venous catheter |

Ethical approval

This work complies with the declaration of Helsinki and written consent has been obtained.

Declaration of interest

The Authors declare that there is no conflicts of interest to disclose.

References

1. Thames Valley Neonatal Operational Delivery Network, Quality Care Group. Nursing care of neonatal central lines. Available at: <https://southodns.nhs.uk/wp-content/uploads/2019/12/CVL-guideline-Dec-2019-Final.pdf>, last review: September 2019, last access: June 2021.
2. Odd D, Battin M, Kuschel C. Variation in identifying neonatal percutaneous central venous line position. *J Paediatr Child Health*. 2004;40(9-10):540-3.
3. Odd DE, Page B, Battin MR, Harding JE. Does radio-opaque contrast improve radiographic localisation of percutaneous central venous lines? *Arch Dis Child Fetal Neonatal Ed*. 2004;89(1):F41-3.
4. Arunoday A, Zipitis C. Confirming PICC line position in neonates – Survey of practice in England and Wales. *World J Clin Pediatr*. 2017;6(3):149-53.
5. Reece A, Ubhi T, Craig AR, Newell SJ. Positioning long lines: contrast versus plain radiography. *Arch Dis Child Fetal Neonatal Ed*. 2001;84(2):F129-30.

6. Fioravanti J, Buzzard C, Harris J. Pericardial effusion and tamponade as a result of percutaneous silastic catheter use. *Neonatal Netw.* 1998;17:39-42.
7. Beattie P, Kuschel C, Harding J. Pericardial effusion complicating a percutaneous central venous line in a neonate. *Acta Paediatr.* 1993;82:105-7.
8. Aiken G, Porteous L, Tracy M, Richardson V. Cardiac tamponade from a fine silastic central venous catheter in a premature infant. *J Paediatr Child Health.* 1992;28:325-7.
9. Nadroo AM, Lin J, Green RS, Magid MS, Holzman IR. Death as a complication of peripherally inserted central catheters in neonates. *J Pediatr.* 2001;138:599-601.
10. Garg M, Chang C, Merritt R. An unusual case presentation: pericardial tamponade complicating central venous catheter. *J Perinatol.* 1989;9:456-7.
11. Rai K, Rao K, Maudar K. Accidental intra-arterial drug injection: a case report. *Med J Armed Forces India.* 1997;53(2):137-9.
12. National Institute for Health and Care Excellence (NICE). Neonatal Parenteral Nutrition. Guideline. Draft for consultation. Available at: <https://www.nice.org.uk/guidance/ng154/documents/draft-guideline>, date of publication: September 2019, last access: May 2022.
13. Roberts I, Murray NA. Neonatal thrombocytopenia: causes and management. *Arch Dis Child Fetal Neonatal Ed.* 2003;88:F359-64.
14. Powls A; NHS Greater Glasgow and Clyde, West of Scotland Neonatology Managed Clinical Network. Peripherally inserted central catheters (PICC Lines) – Neonatology guideline. Available at: <https://www.clinicalguidelines.scot.nhs.uk/nhsggc-paediatric-clinical-guidelines/nhsggc-guidelines/neonatology/peripherally-inserted-central-catheters-picc-lines-neonatology-guideline/>, last revision: April 2018, last access: April 2018.
15. Qadir S, Alvi N, Zeglen A, Jagannathan A, Abraham RZ. The Enigma of a Misplaced Peripherally Inserted Central Catheter. *Am J Respir Crit Care Med.* 2020;201:A7061.
16. Pilling E; the Yorkshire and Humber Neonatal Operational Delivery Network. Long line or PICC (peripherally inserted central catheter) – indications, insertion, accessing, care of. Yorkshire and Humber Neonatal ODN (South) Clinical Guideline. Available at: <https://www.networks.nhs.uk/nhs-networks/yorkshire-humber-neonatal-odn/guidelines-1/guidelines-new/surgical-procedures/long-line>, date of publication: 2011, last access: June 2021.
17. Baserga M, Puri A, Sola A. The use of topical nitroglycerin ointment to treat peripheral tissue ischemia secondary to arterial line complications in neonates. *J Perinatol.* 2002;22(5):416-9.
18. Mosalli R, Elbaz M, Paes B. Topical Nitroglycerine for Neonatal Arterial Associated Peripheral Ischemia following Cannulation: A Case Report and Comprehensive Literature Review. *Case Rep Pediatr.* 2013;2013:608516.
19. Sushko K, Litalien C, Ferruccio L, Gilpin A, Mazer-Amirshahi M, Chan AK, van den Anker J, Lacaze-Masmonteil T, Samiee-Zafarghandy S. Topical nitroglycerin ointment as salvage therapy for peripheral tissue ischemia in newborns: a systematic review. *CMAJ Open.* 2021;9(1):E252-60.
20. Samiee-Zafarghandy S, van den Anker J, Ben Fadel N. Topical nitroglycerin in neonates with tissue injury: A case report and review of the literature. *Paediatr Child Health.* 2014;19(1):9-12.
21. Vivar del Hoyo P, Sánchez Ruiz P, Ludeña del Río M, López-Menchero Oliva JC, García Cabezas MA. [Use of topical nitroglycerin in newborns with ischaemic injuries after vascular cannulation]. [Article in Spanish]. *An Pediatr (Barc).* 2016;85:155-6.
22. Maffei G, Rinaldi M, Rinaldi G. Resolution of peripheral tissue ischemia secondary to arterial vasospasm following treatment with a topical nitroglycerin device in two newborns: case reports. *J Perinat Med.* 2006;34(3):252.
23. Huang YF, Hu YL, Wan XL, Cheng H, Wu YH, Yang XY, Shi J. Arterial embolism caused by a peripherally inserted central catheter in a very premature infant: A case report and literature review. *World J Clin Cases.* 2020;8(18):4259-65.
24. Royal Wolverhampton Hospital Trust. Vascular Spasm and Thrombosis in the Neonatal period. Available at: https://www.networks.nhs.uk/nhs-networks/staffordshire-shropshire-and-black-country-newborn/documents/Neonatal_arterial_thrombosisFINAL-1.pdf, last review: 2014, last access: June 2021.
25. Women and Newborn Health Service, North Metropolitan Health Service, Government of Western Australia. Neonatal Medication Guideline. Glyceryl Trinitrate (Topical). Available at: <https://kemh.health.wa.gov.au/~media/HSPs/NMHS/Hospitals/WNHS/Documents/Clinical-guidelines/Neonatal-MPs/Glyceryl-Trinitrate.pdf>, last access: June 2021.
26. Teo MC, Shah VA. Digital ischaemia following inadvertent arterial cannulation of a peripherally inserted central catheter in a very low birth weight infant. *Singapore Med J.* 2015;56(8):482-3.
27. Fraga MV, Stoller JZ, Glau CL, De Luca D, Rempell RG, Wenger JL, Yek Kee C, Muhly WT, Boretsky K, Conlon TW. Seeing Is Believing: Ultrasound in Pediatric Procedural Performance. *Pediatrics.* 2019;144(5):e20191401.
28. Obert LC, Wolujewicz M, Vu DN, Ristagno RL. Stroke by PICC: Which patient is at risk? *Applied Radiology.* 2013;12:23-5.
29. McMillan D, Wu J. Approach to the bleeding newborn. *Paediatr Child Health.* 1998;3(6):399-401.