

# Conservative management of giant omphalocele: 20-year experience from a tertiary care center in North India

Kamal Nain Rattan<sup>1</sup>, Jasbir Singh<sup>2</sup>, Poonam Dalal<sup>2</sup>, Ravi Rohilla<sup>3</sup>

<sup>1</sup>Department of Pediatric Surgery, PGIMS, Rohtak, Haryana, India

<sup>2</sup>Department of Pediatrics, PGIMS, Rohtak, Haryana, India

<sup>3</sup>Department of Community Medicine, Government Medical College & Hospital, Chandigarh (UT), India

## Abstract

Despite significant advances, the management of giant omphalocele (GO) still remains a challenging job for neonatologists and pediatric surgeons. Early surgical treatment of GO may not be undertaken in every patient due to the risk of fatal hemodynamic and respiratory compromise and associated congenital malformations. We analyzed the profile and outcome of patients with GO who were managed conservatively using povidone-iodine as escharotic agent. A total of 27 neonates with GO were managed conservatively during the study interval (1998-2016). Mean gestational age among survivors and expired group was  $37.5 \pm 1.5$  weeks and  $35.0 \pm 1.0$  weeks, respectively. Mean birth weight was  $2,950 \pm 500$  g in the survivor group and  $2,300 \pm 450$  g in the expired group. Prenatal diagnosis was available in eight patients (29.6%). Twenty-three (85.2%) neonates were born with vaginal delivery. Associated congenital malformations were present in 37% (10/27) patients. The mean duration of complete epithelialization of sac was  $10.0 \pm 2.5$  weeks. Surgical intervention was done at 4-9 months of age. Eight (29.6%) patients expired during the study period. We observed prematurity, low birth weight, associated congenital anomalies and sepsis as risk factors associated with increased mortality.

## Keywords

Escharotics, neonate, omphalocele major, outcome.

## Corresponding author

Jasbir Singh, Senior Resident, Department of Pediatrics, PGIMS, Rohtak, Haryana, India 124001; email: jasbir2001@gmail.com.

## How to cite

Rattan KN, Singh J, Dalal P, Rohilla R. Conservative management of giant omphalocele: 20-year experience from a tertiary care center in North India. *J Pediatr Neonat Individual Med.* 2020;9(1):e090105. doi: 10.7363/090105.

## Introduction

Due to the availability of better perinatal care, Neonatal Intensive Care Units (NICUs) and surgical facilities, the survival rate among neonates with giant omphalocele (GO) had been improved considerably in developed countries [1]. However, the management of GO still remains an issue of debate. Primary closure, staged closure and delayed repair had been described as management strategies with variable success rates. The early surgical treatment of GO sometimes may not be possible due to the risk of fatal hemodynamic and respiratory compromise and associated congenital malformations [2]. However, the delayed management of GO with topical escharotics agents allows secondary wound healing resulting in a ventral hernia, which is repaired later. This method had the advantage of avoiding fatal complications such as abdominal compartment syndrome, wound dehiscence, intestinal obstruction and perforation [3]. In the present study, we are describing our experience with conservative treatment of GO in neonates using topical povidone-iodine as escharotic agent.

## Material and methods

This was a retrospective analysis of medical records of neonates with GO who were treated by conservative methods at our center. The study period spanned over 20 years (1998-2016). Data was extracted from medical records of neonates admitted during the study period. Information regarding sex, gestational age, mode of delivery, associated anomalies, length of initial hospital stay, time taken

for full epithelialization of sac membrane, time of definite surgery, and postoperative complications, final outcome either discharged or died was collected. The patients were divided into two groups as survivor and expired for comparison of various characteristics (**Tab. 1**).

The lesion was termed as GO when primary closure of defect could not be performed due to significant visceros-abdominal disproportion. A detailed clinical examination, radiological (X-rays and ultrasound) and hematological (CBC, serum electrolytes and sugar levels) investigations were carried out in each neonate. A gauze soaked with povidone-iodine was applied to the sac membrane. The frequency of application was once a day initially, which was changed to every other day with evidence of epithelialization of sac. The hemodynamic and biochemical parameters (sugar levels, serum electrolytes) were monitored. Once the neonate had passed meconium, oral feeds were started. Discharge from the hospital was planned when the baby was tolerating oral feeds. Danger signs were explained to parents and they were advised to report immediately if any of them develop. The follow-up visits were planned twice weekly; the neonate was assessed for feed acceptance, weight gain, status of epithelialization. After complete epithelialization of the sac, the delayed repair was performed at a variable period of 4-9 months.

## Results

A total of 27 neonates with GO were managed conservatively during study interval (**Tab. 1**). Mean gestational age among survivors and

**Table 1.** Clinical profile of neonates with giant omphalocele (GO) among survivor and expired group.

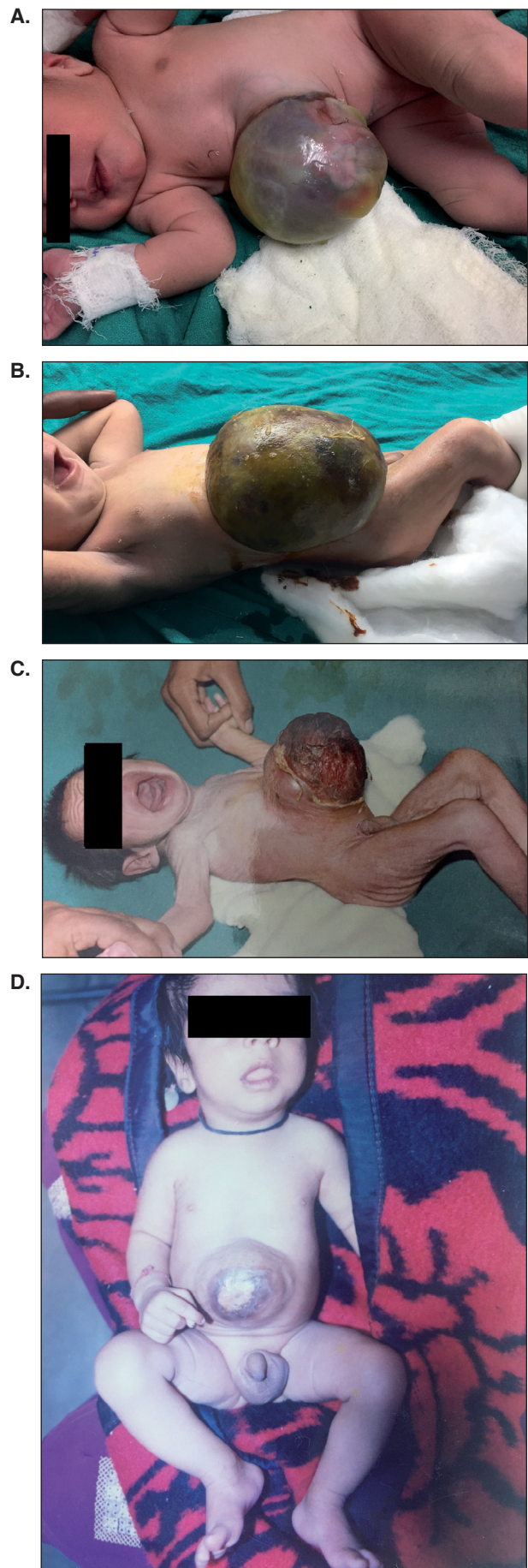
Characteristics		Survivors (n = 19)	Expired (n = 8)
Male		14	3
Mean birth weight		2,950 ± 500 g	2,300 ± 450 g
Mean gestational age		37.5 ± 1.5 weeks	35.0 ± 1.0 weeks
Associated congenital malformations	Congenital heart diseases	1	3
	Skeletal malformations	1	-
	Heteropagus parasite	-	1
	Beckwith-Wiedemann syndrome	1	-
	Trisomy 21	1	-
	Meningomyelocele	-	1
Teratoma of sac		-	1
Sepsis		1	2
Mean duration of hospital stay		16.4 ± 2.5 days	19.5 ± 3.5 days

expired group was  $37.5 \pm 1.5$  weeks and  $35.0 \pm 1.0$  weeks, respectively. Mean birth weight was  $2,950 \pm 500$  grams in the survivor group and  $2,300 \pm 450$  g in the expired group. Prenatal diagnosis was available in eight patients, all in the last 10 years of study interval. Twenty-three neonates were born with vaginal delivery. Associated congenital malformations were present in 37% (10/27) patients. Fifteen babies were referred from peripheral hospitals within 24 hours of birth. Eight neonates were having evidence of sepsis on admission at our center. The pictures of four cases are presented in **Fig. 1**.

After a detailed investigational workup, conservative treatment with application of povidone-iodine was started. The mean duration of first hospital stay was  $10.4 \pm 1.5$  days and after discharge every neonate was called in outdoor unit twice a week. During follow-up, four patients were readmitted due to sepsis and managed with appropriate antibiotics. The patients with congenital heart diseases (serial ECHO) and Beckwith-Wiedemann syndrome were managed conservatively (renal functions, sugar level, and ultrasound scan). The mean duration of complete epithelialization of the sac was  $10.0 \pm 2.5$  weeks. Surgical intervention was done at 4-9 months of age. In postoperative morbidity, three neonates had sepsis, which was managed conservatively with intravenous antibiotics. Eight (29.6%) patients expired during the study period, all except one before surgery. In one neonate with GO, sac ruptured during conservative treatment and emergency surgery was performed. This patient expired in the postoperative period due to sepsis. In three patients, there was a larger disproportion between herniated viscera and size of abdominal cavity than others. They were readmitted during follow up with abdominal distension. With malrotation of gut ruled out in all of them, bowel vascular catastrophe was thought to be underlying etiology. In our series, we observed prematurity, low birth weight, associated congenital anomalies and sepsis as risk factors associated with increased mortality.

## Discussion

Conservative management in GO was described first by Ahlfeld in 1899 using alcohol as an escharotics agent [4]. To date, depending upon local availability, many escharotics agents had been tried with different success rates and adverse effects [5-9]. Even topical application



**Figure 1.** The pictures of four cases are presented.



of povidone-iodine has been associated with a known risk of transient hypothyroidism, possibly due to the Wolff-Chaikoff effect [10]. Recently, successful use of honey and a plant derivative *Acacia nilotica* paste as escharotics agent had been reported by Nicoara et al. and Eltayeb and Mostafa, respectively [11, 12]. The choice of an escharotic agent depends upon the local availability, cost, ease of application and, most importantly, low risk of adverse effects. In the present cohort, none of the patients required thyroid hormone supplementation during follow-up.

As compared to other studies, the prenatal diagnosis was available in very few patients (29.6%) in the present study [13]. This may be due to the lack of advanced diagnostic facilities and poor socio-economic conditions of patients. In our study, the majority of neonates (85.2%) were born vaginally, so, size of omphalocele may not have any effect on the mode of delivery and cesarean section should be performed only for obstetric indications. Habou et al. had reported similar findings in their review with 13 patients [14]. The good quality care provided in the early neonatal period may be a determining factor for a favorable outcome. In developing countries, as most of the pediatric surgical units are located far away in metropolitan cities, the conservative management of GO may be of good advantage. The importance of simple measures like sterile dressing of the sac, preventing hypothermia and minimizing insensible fluid loss, insertion of an orogastric tube to decompress the stomach and maintaining adequate hydration should be emphasized among peripheral health workers. After the initial workup and starting escharotics therapy at tertiary care centers, the neonate can be referred back and the peripheral health workers can be trained in conservative management (like topical application of escharotics agent and weekly monitoring) till the definitive repair can be planned. This approach has the advantage of potential use for the high-risk infants with GO like in extremely premature, or neonates with congenital heart disease who cannot tolerate the early surgery. However, the conservative approach had the disadvantage of missing the malrotation of the gut. If a neonate presents with recurrent vomiting and abdominal distension, then further investigations (e.g., ultrasound and GI contrast study) should be performed to rule out malrotation.

Overall mortality was 29.6% (8/27) in the present cohort, which was similar to the one reported in

other studies using conservative methods [11, 15]. We had observed that prematurity, associated congenital malformations and sepsis were the important factors associated with poor outcome. Pandey et al. and Habou et al., in their reviews, had also reported the above factors are associated with increased mortality [14, 16].

## Conclusion

In resource-limited settings, the conservative management of GO with povidone-iodine solution dressing can be used successfully once associated malformations are ruled out. This procedure is easy, less expensive and does not require special equipment, so it can be used in remote areas with the training of health workers at peripheral NICUs in developing countries.

## Declaration of interest

The Authors declare that there is no conflict of interest.

## References

1. Abdur-Rahman LO, Abdulrasheed NA, Adeniran JO. Challenges and outcomes of management of anterior abdominal wall defects in a Nigerian tertiary hospital. *Afr J Paediatr Surg.* 2011;8(2):159-63.
2. Osifo OD, Efobi AC. Challenges of giant ventral hernia repair in children in an African tertiary care centre with limited resource. *Hernia.* 2009;13(2):143-7.
3. Ekot EA, Emordi VC, Osifo DO. Does omphalocele major undergo spontaneous closure? *J Surg Case Rep.* 2017;(8):rjx156.
4. Kouame BD, Odehouri Koudou TH, Yaokreh JB, Sounkera M, Tembely S, Yapo K, Boka R, Koffi M, Dieth AG, Ouattara O, da Silva A, Dick R. Outcomes of conservative treatment of giant omphaloceles with dissodic 2% aqueous eosin: 15 years' experience. *Afr J Paediatr Surg.* 2014;11(2):170-3.
5. Wakhlu A, Wakhlu AK. The management of exomphalos. *J Pediatr Surg.* 2000;35(1):73-6.
6. Mullins ME, Horowitz BZ. Iatrogenic neonatal mercury poisoning from Mercurochrome treatment of a large omphalocele. *Clin Pediatr (Phila).* 1999;38(2):111-2.
7. Gough DC, Auldred AW. Giant exomphalos – Conservative or operative treatment? *Arch Dis Child.* 1979;54(6):441-4.
8. Festen C, Severijnen RS, vd Staak FH. Nonsurgical (conservative) treatment of giant omphalocele. A report of 10 cases. *Clin Pediatr (Phila).* 1987;26(1):35-9.
9. Lewis N, Kolimarala V, Lander A. Conservative management of exomphalos major with silver dressings: Are they safe? *J Pediatr Surg.* 2010;45(12):2438-9.
10. Whitehouse JS, Gourlay DM, Masonbrink AR, Aiken JJ, Calkins CM, Sato TT, Arca MJ. Conservative management of giant

- omphalocele with topical povidone-iodine and its effect on thyroid function. *J Pediatr Surg.* 2010;45(6):1192-7.
11. Nicoara C, Singh M, Jester I, Reda B, Parikh DH. Medicated manuka honey in conservative management of exomphalos major. *Pediatr Surg Int.* 2015;30(5):515-20.
  12. Eltayeb AA, Mostafa MM. Topical treatment of major omphalocele: *Acacia nilotica* versus povidone-iodine: A randomised controlled study. *Afr J Paediatr Surg.* 2015;12(4):241-6.
  13. Liang YL, Kang L, Tsai PY, Cheng YC, Ko HC, Chang CH, Chang FM. Prenatal diagnosis of fetal omphalocele by ultrasound: a comparison of two centuries. *Taiwan J Obstet Gynecol.* 2013;52(2):258-63.
  14. Habou O, Adamou H, Magagi IA, Ali OM, Magagi A, Moustapha H, Saboe R, Abarchid H. The conservative treatment of giant omphalocele by tanning with povidone iodine and aqueous 2% eosin solutions. *Ann Pediatr Surg.* 2017;13:125-8.
  15. Ein SH, Langer JC. Delayed management of giant omphalocele using silver sulfadiazine cream: An 18-year experience. *J Pediatr Surg.* 2012;47(3):494-500.
  16. Pandey V, Gangopadhyay AN, Gupta DK, Sharma SP, Kumar V. Non-operative management of giant omphalocele with topical povidone-iodine and powdered antibiotic combination: early experience from a tertiary centre. *Pediatr Surg Int.* 2014;30(4):407-11.