

Unusual site for iatrogenic esophageal perforation in a premature neonate

Maria Lithoxopoulou¹, Anastasia Gkampeta¹, Evgeniya Babatseva¹, Elpida Simeoforidou¹, Efthymia Chatzitoliou¹, Parthena Georgiadou¹, Kleanthis Anastasiadis², Christos Kaselas², Chrysostomos Kepertis², Ioannis Spyridakis², Vasiliki Soubasi¹

¹2nd Neonatal Department and Neonatal Intensive Care Unit, Aristotle University, Papageorgiou General Hospital, Thessaloniki, Greece

²2nd Department of Pediatric Surgery, Aristotle University of Thessaloniki, Papageorgiou General Hospital, Thessaloniki, Greece

Abstract

Esophageal perforation in the neonate period is uncommon and often iatrogenic in origin, requiring a prompt diagnosis in order to prevent further complications. We present a case of iatrogenic esophageal perforation in a premature neonate following orogastric tube placement. Findings on plain film radiograph were consistent with thoracic esophageal perforation. Due to the patient's hemodynamic stability, the patient was treated nonoperatively with favorable results. We also discuss the cause, clinical clues to the diagnosis and treatment in cases with esophageal perforation.

Keywords

Neonatal, esophageal, perforation.

Corresponding author

Anastasia Gkampeta, ²2nd Neonatal Department and Neonatal Intensive Care Unit, Aristotle University, Papageorgiou General Hospital, Thessaloniki, Greece; email: anastagab@yahoo.gr.

How to cite

Lithoxopoulou M, Gkampeta A, Babatseva E, Simeoforidou E, Chatzitoliou E, Georgiadou P, Anastasiadis K, Kaselas Ch, Kepertis Ch, Spyridakis I, Soubasi V. Unusual site for iatrogenic esophageal perforation in a premature neonate. *J Pediatr Neonat Individual Med.* 2019;8(1):e080113. doi: 10.7363/080113.

Introduction

The first report of neonatal esophageal perforation by James Fryfogle in 1952 was spontaneous in origin, while the first case of traumatic perforation secondary to esophageal instrumentation was reported nine years later by Warden and Mucha [1].

Esophageal perforation is a rare but potentially fatal event in the neonatal period with high mortality rates up to 28% [2]. Most of deaths are related to comorbidities such as intraventricular hemorrhage, necrotizing enterocolitis, sepsis and/or congenital cardiopathies. Premature and low birth weight neonates are more vulnerable to traumatic esophageal perforation which is mainly caused by multiple intubation attempts, oropharyngeal suctioning, nasogastric or orogastric tube insertion [3]. According to the literature, gastric tube insertion, esophagoscopy and attempted endotracheal tube intubation account for 71-84% of perforations. The prevalence of misplaced nasogastric or orogastric tubes in children has been reported to be as high as 21-43.5% [4]. Recent reports demonstrate an incidence of esophageal perforation in the neonatal intensive care unit (NICU) of 0.4-0.5%, increasing ten-fold in infants weighing lower than 750 g [3]. The diagnosis of esophageal perforation should be suspected in any infant presenting with hypersalivation, choking, coughing, or cyanosis after repeated or difficult endotracheal or enterogastric intubation. Blood or coffee ground aspirate from nasogastric or orogastric tube is suggestive of esophageal perforation.

Esophageal perforation is uncommon in the neonatal period and can be spontaneous or traumatic. Spontaneous perforations are rare, usually occurring in term neonates and commonly involve the lower esophagus (3-5 cm from the gastroesophageal junction). It is called Boerhaave Syndrome: the perforation of the esophagus is generally in the right part, because it is protected by the aorta in the left. They have been attributed to the increased abdominal pressure during delivery, perinatal hypoxia, esophagitis or gastroesophageal reflux. On the other hand, traumatic perforations occur more often in premature and low birth weight neonates who underwent resuscitation or instrumentation of the airway or pharynx [5]. The perforation is more frequent in the pharyngo-esophageal region. In these cases, hurried or inexperienced manipulation with the laryngoscope blade, repetitive placement of orogastric and nasogastric tubes or repetitive pharyngeal suctioning may cause spasm of the

cricopharyngeal muscle resulting in closure of the esophageal lumen and traumatic esophageal perforation. Another cause is the hyperextension of the head, that can cause a compression of the esophagus against the vertebrae and favor the perforation. Cervical perforation is less severe because the esophagus in that part is adherent to the prevertebral fascia: this prevents inflammation, the dissemination of eventual infections and mediastinal contamination.

In contrast with adult patients in whom surgical closure of the defect is preferred, nonoperative treatment has become a common therapeutic approach for esophageal perforation in neonates and children. This case report describes a premature neonate with traumatic esophageal perforation following orogastric tube placement and discusses the cause, clinical clues to the diagnosis and treatment in such cases.

Case presentation

A premature male neonate was delivered at 27⁺⁵ weeks of gestation by cesarean section due to immaturity and premature rupture of membranes (26 days before delivery) weighing 1,230 g, without clinical signs and symptoms and laboratory findings of chorioamnionitis. The baby cried immediately after birth with spontaneous respirations. Apgar scores were 7 and 8 at 1 and 5 minutes, respectively. Pregnancy had been uncomplicated with normal prenatal ultrasound examinations. Within 30 minutes of life, the baby developed respiratory distress and an increasing oxygen requirement and was referred to our NICU at the 6th hour of life for further management. Neonatal co-morbidities included a patent ductus arteriosus and bilateral intraventricular hemorrhage (grade II).

Due to significant respiratory distress, the neonate was started on non-invasive ventilation with synchronized nasal intermittent positive-pressure ventilation (SNIPPV) and antibiotic therapy with ampicillin and gentamicin was initiated. A 6 French orogastric tube was inserted and suction catheters regularly used as part of routine care. A chest radiogram showed a right-sided pneumothorax, so the neonate underwent immediate chest tube placement.

Suddenly, soon after feeding through a newly placed orogastric tube the neonate's condition worsened with recurrent episodes of apnea with bradycardia requiring intubation. Bloody aspirate was found in the orogastric tube and the oropharynx.

A subsequent chest radiograph with water-soluble contrast showed the orogastric tube in the right pleural cavity with a right-sided pleural effusion and pneumomediastinum, indicating a perforation of the thoracic esophagus (**Fig. 1**). On all previous radiographs, the orogastric tube had been properly positioned and tube replacement was routinely performed every 3-5 days.

With the orogastric tube in its place, a nasogastric one was inserted additionally and positioned appropriately, confirmed both clinically and radiologically (**Fig. 2**). Given the neonate's hemodynamic stability, he was treated nonoperatively. Empirical management included intravenous antibiotic therapy for 10 days (vancomycin: 15 mg/kg every 18 h, meropenem: 40 mg/kg/dose every 8 hours), total parenteral nutrition for 10 days, adequate fluid resuscitation, chest closed-tube drainage of pleural effusion, analgesics (paracetamol: 7.5 mg/kg/dose), respiratory support, minimal oropharynx suctioning and intensive care monitoring. The further hospital course of the baby was uneventful.

An esophagographic study on the 12th day confirmed a fully healed esophagus, and the baby was gradually weaned off respiratory support. Enteral feeding through the orogastric tube was restarted and gradually increased, which were well tolerated, and the neonate was discharged.

Discussion

The management of neonates with traumatic esophageal perforation depends on the severity

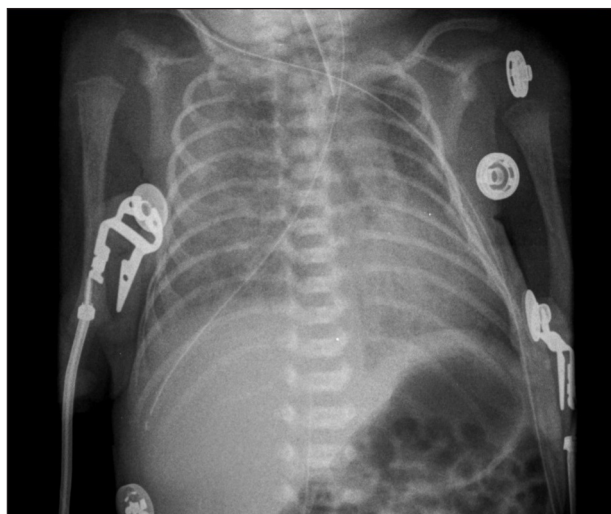


Figure 1. Chest radiograph revealing a feeding tube in the right pleural cavity, indicating a perforation of the thoracic esophagus.

of each individual case (size of perforation, its location and the neonate's general condition). Most cases are treated conservatively although surgical intervention may be required for patients whose condition deteriorates or for misdiagnosed cases. There is no difference in the reported rate of survival when treated conservatively versus surgically. In our case, conservative management was successful. Nonoperative treatment consists of intravenous broad-spectrum antibiotic therapy (7 days median duration), parenteral nutrition (median duration 8 days), adequate fluid resuscitation, chest closed-tube drainage of pleural effusion, analgesics, respiratory support when indicated, and intensive care monitoring [4, 6]. Recent reports support the conservative approach, with excellent results [7]. In a very recent study, Hesketh et al. describe 7 patients diagnosed with esophageal perforation resulting from endotracheal or enterogastric intubation, all managed nonoperatively with excellent outcome [3]. In a more recent study, Onwuka et al. report the largest sample of neonates (25 neonates) treated successfully nonoperatively [7]. Due to our patient's hemodynamic stability, he was treated nonoperatively with favorable results.

In conclusion, esophageal perforation is not uncommon in premature infants during nasogastric

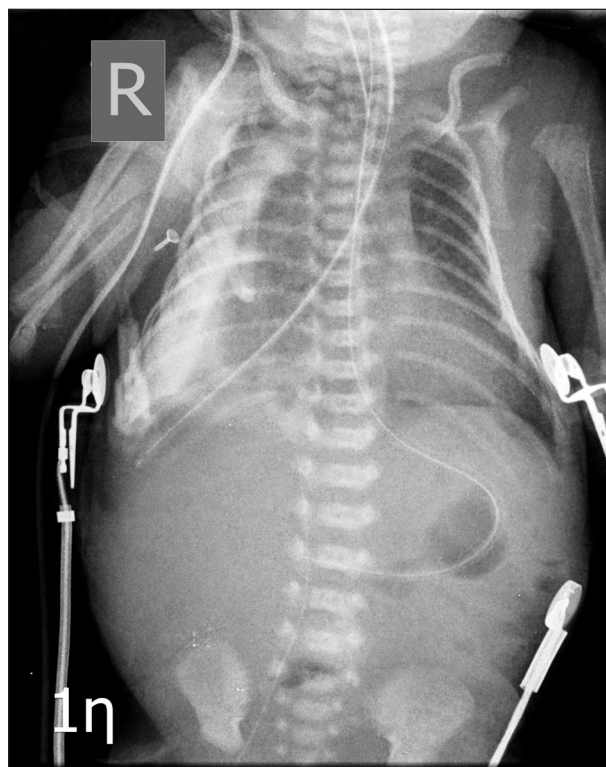

Figure 2. Chest radiograph showing the orogastric tube in its place, while a nasogastric one was inserted additionally and positioned appropriately.

or orogastric intubation in NICUs, associated with significant morbidity or mortality. The perforation is more frequent in the pharyngo-esophageal region, while in our case the perforation's site was unusual (perforation of the thoracic esophagus). Intubation should be performed by experienced physicians in a gentle manner using compliant tubes and avoiding force and blind intubations. Preventive strategies include gentle manipulation, softening of orogastric tubes, use of lubricants, verification prior to feeding, and prolonged intervals for replacement. Early suspicion and diagnosis of esophageal perforation are important because appropriate treatment usually ensures an excellent outcome, preventing further complications such as mediastinitis, empyema, sepsis, and multi-organ failure [4, 8, 9]. A high index of suspicion is warranted in infants with a sudden deterioration of respiratory status or in the presence of bloody aspirate following difficult intubation or orogastric tube insertion.

Declaration of interest

The Authors declare that there is no conflict of interest. The Authors received no financial support for the research, authorship, and/or publication of this article.

References

1. Warden HD, Mucha SJ. Esophageal perforation due to trauma in the newborn. A case report. *Arch Surg.* 1961;83:813.
2. Gander JW, Berdon WE, Cowles RA. Iatrogenic esophageal perforation in children. *Pediatr Surg Int.* 2009;25:395-401.
3. Hesketh AJ, Behr CA, Soffer SZ, Hong AR, Glick RD. Neonatal esophageal perforation: nonoperative management. *J Surg Res.* 2015;198(1):1-6.
4. Sticco A, Khettry A, Aldape C, Tortolani A, Velcek F. Iatrogenic esophageal perforation in a premature neonate: A current nonoperative approach to management. *J Ped Surg Case Reports.* 2014;2:37-9.
5. Modi A, Mathur NB, Sarin YK. Spontaneous neonatal esophageal perforation. *Indian Pediatr.* 2000;37(8):901-3.
6. Suryawanshi P, Dahat A, Nagpal R, Malshe N, Kalrao V. A rare case of accidental esophageal perforation in an extremely low birth weight neonate. *J Clin Diagn Res.* 2014;8(6):PD01-2.
7. Onwuka EA, Saadai P, Boomer LA, Nwomeh BC. Nonoperative management of esophageal perforations in the newborn. *J Surg Res.* 2016;205(1):102-7.
8. Yong SB, Ma JS, Chen FS, Chung MY, Yang KD. Nasogastric Tube Placement and Esophageal Perforation in Extremely Low Birth Weight Infants. *Pediatr Neonatol.* 2016;57(5):427-30.
9. Rentea RM, St Peter SD. Neonatal and pediatric esophageal perforation. *Semin Pediatr Surg.* 2017;26(2):87-94.