

# Successful treatment of *Staphylococcus haemolyticus* endocarditis in extremely premature baby with daptomycin

Suzan Suhail Asfour<sup>1</sup>, Fahad Aljobair<sup>2</sup>, Ibrahim Hammami<sup>3</sup>, Adli Abdelrahim<sup>4</sup>, Mountasser M. Al-Mouqdad<sup>4</sup>

<sup>1</sup>Clinical Pharmacy Department, Pharmacy Department, King Saud Medical City, Riyadh, Saudi Arabia

<sup>2</sup>Infectious Disease Department, Hospital of Pediatrics, King Saud Medical City, Riyadh, Saudi Arabia

<sup>3</sup>Pediatric Pharmacy, Pharmacy Department, King Saud Medical City, Riyadh, Saudi Arabia

<sup>4</sup>Neonatology, Hospital of Pediatrics, King Saud Medical City, Riyadh, Saudi Arabia

## Abstract

Daptomycin is a novel lipopeptide antibiotic with rapid activity against Gram-positive bacteria including methicillin-resistant *Staphylococcus aureus*, coagulase-negative *Staphylococci*, and *Enterococci*. We are reporting the first case of successfully using daptomycin to treat infective endocarditis in an extremely premature baby.

## Keywords

Endocarditis, daptomycin, neonate, premature, *Staphylococcus haemolyticus*, sepsis.

## Corresponding author

Suzan Suhail Asfour, Clinical Pharmacy Department, Pharmacy Department, King Saud Medical City, Riyadh, Saudi Arabia; tel: 00966114355555 – ext: 506; mobile: 00966560889737; fax: 00966114634457; postal code: 11461; email: asfsuzan@gmail.com.

## How to cite

Asfour SS, Aljobair F, Hammami I, Abdelrahim A, Al-Mouqdad MM. Successful treatment of *Staphylococcus haemolyticus* endocarditis in extremely premature baby with daptomycin. J Pediatr Neonat Individual Med. 2019;8(1):e080109. doi: 10.7363/080109.

## Introduction

Daptomycin is a lipopeptide antibiotic with bactericidal effect. Daptomycin acts rapidly against Gram-positive organisms including methicillin-resistant *Staphylococcus aureus* (MRSA), coagulase-negative *Staphylococci*, and *Enterococci* [1]. Daptomycin is excreted renally, largely unchanged in the urine [1]. Experience with daptomycin in neonates and infants regarding the appropriate dose and adjustment in renal dysfunction is very limited [2-5]. Here is the first case of using daptomycin to treat infective endocarditis in an extremely premature baby (26 weeks gestational age).

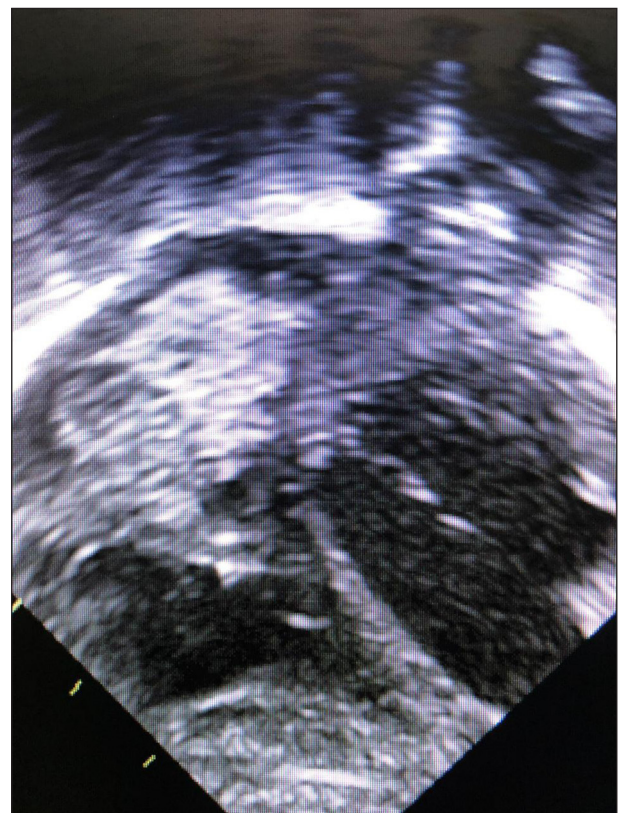
## Case report

A male infant with birth weight 960 grams was born at the 26<sup>th</sup> week of gestation, delivered by normal spontaneous vaginal delivery with an Apgar score of 2 and 7 at 1 and 5 minutes, respectively. The baby was admitted to the neonatal intensive care unit, intubated and given surfactant for respiratory distress syndrome. An umbilical venous catheter was inserted, and ampicillin and gentamicin were started. Antibiotics were discontinued on the 3<sup>rd</sup> day of life after negative blood culture result. The transthoracic echocardiogram (ECHO) was done on the 3<sup>rd</sup> day of life and showed small atrial septal defect secundum, small ventricular septal defect, and mild interventricular septum hypertrophy with no patent ductus arteriosus. Brain ultrasound also was done and showed grade III of intraventricular hemorrhage. On the 12<sup>th</sup> day of life, the baby was started on vancomycin as he developed *Staphylococcus haemolyticus* bacteremia that was sensitive to vancomycin, trimethoprim/sulfamethoxazole, rifampicin, and linezolid while it was resistant to oxacillin. The culture was repeated at the age of 13, 15, 20, and 22 days of life showing persistently positive blood cultures with *Staphylococcus haemolyticus*. The cultures remained positive despite treatment with an appropriate dose of vancomycin and with normal trough level. Vancomycin minimum inhibitory concentration was 1.0 µg/ml at the start of therapy and rose to 2.0 µg/ml on therapy. Therefore, vancomycin was changed to linezolid plus rifampicin, the umbilical venous catheter was removed and a peripherally inserted central catheter line was inserted. On the 27<sup>th</sup> day of life

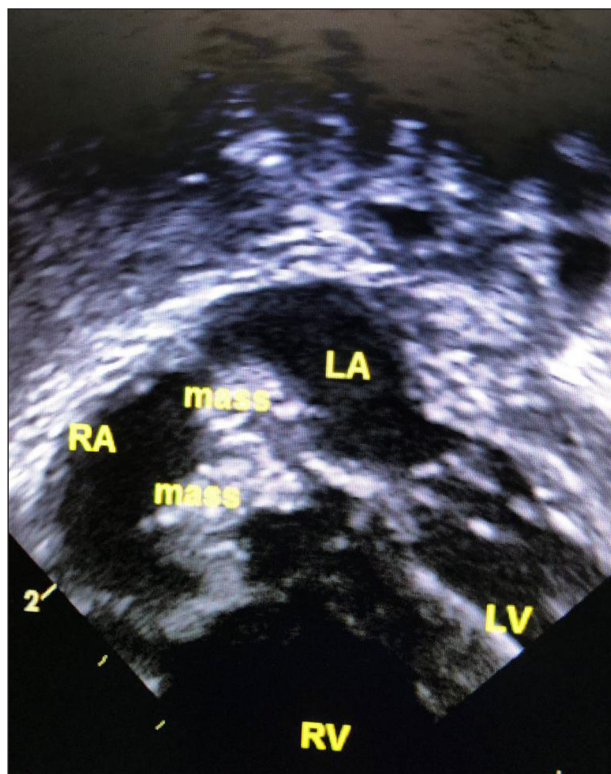
the blood culture became negative; however, the baby remained unwell. ECHO was repeated and revealed developing of two large vegetations, the first one (9 x 10 mm) was in the inferior vena cava reaching interatrial septum, and the second one (9 x 10 mm) was in the tricuspid valve with inflow obstruction (**Fig. 1**). Therefore, the peripherally inserted central catheter line was removed and linezolid was switched to daptomycin 10 mg/kg/dose intravenously every 24 hours, and rifampicin 10 mg/kg/dose intravenously every 12 hours. Baby improved clinically and subsequent blood cultures remained negative. A serial ECHO was repeated and displayed a significant regressing in the vegetation size (2 x 2 mm) (**Fig. 2**). Daptomycin continued for a total of 6 weeks duration. The baby was discharged at the corrected age of 39 weeks with a weight of 2.26 kilograms.

## Discussion

We report the first case of using daptomycin in an extremely preterm neonate with infective



**Figure 1.** ECHO was repeated and revealed developing of two large vegetations, the first one (9 x 10 mm) was in the inferior vena cava reaching interatrial septum, and the second one (9 x 10 mm) was in the tricuspid valve with inflow obstruction.



**Figure 2.** A serial ECHO was repeated and displayed a significant regressing in the vegetation size (2 x 2 mm).

endocarditis. Initially, our patient had persistence positive blood culture with *Staphylococcus haemolyticus* that was refractory to vancomycin treatment. The blood culture became sterile after initiation of linezolid and rifampicin. Linezolid is approved for use in the neonate with vancomycin-resistant *Enterococci* and MRSA [6]. Due to the lack of clinical improvement and bacteriostatic effect of linezolid, it was switched to daptomycin.

Daptomycin acts rapidly against Gram-positive organisms including MRSA, coagulase-negative *Staphylococci*, and *Enterococci* [1]. It is a new semi-synthetic lipopeptide antibiotic that binds the bacterial cell wall membrane forming pores, followed by a calcium-dependent action to increase the membrane potential and finally bacterial cell death [1, 6]. Furthermore, it has a bactericidal effect and a concentration-dependent activity [1]. Reports of experience with daptomycin use in infants and children are limited. Atkins et al. reported that a 13-year-old male with post bone marrow transplant for aplastic anemia was treated with daptomycin for vancomycin-resistant *Enterococci* endocarditis at a dose of 8 mg/kg once daily [7]. Most of the case reports in neonates have used doses of 6 mg/kg/dose intravenously every 12 hours in infants with normal kidney function

[3, 8, 9]. Hussain et al. used 10 mg/kg/dose intravenously every 24 hours for a premature baby (27<sup>+</sup> weeks' gestation) at the postnatal age of 28 days for MRSA bacteremia [5].

The appropriate dose for this case is still unclear. Daptomycin successfully treated the endocarditis with greater improvement in the size of the vegetations.

Daptomycin is excreted largely unchanged through the kidneys. Pharmacokinetic studies in adults demonstrate linear clearance. Therefore, infants with normal renal function might require higher doses compared with pediatrics and adults [1]. Our patient had normal kidney function test; so, we decided to give 10 mg/kg/dose intravenously every 24 hours with monitoring of kidney function test and creatine kinase (CK). In addition to acute renal failure, daptomycin may increase CK, and cause rhabdomyolysis. These adverse effects are reversible once the drug is discontinued. In adult patients receiving daptomycin, CK monitoring is recommended at the start of therapy and at least weekly thereafter. More frequent CK monitoring is indicated in patients with baseline renal dysfunction [10]. Our patient had normal CK during the course of treatment.

We did not measure the serum daptomycin concentrations as the reagent was not available in our laboratory. In addition, serum drug levels are not routinely monitored in clinical practice. There were no adverse effects observed in our patient during treatment or after completion of therapy.

## Conclusion

As a conclusion, daptomycin with dose 10 mg/kg/dose intravenously every 24 hours appears to be a safe and effective alternative therapy in neonates with resistant infections caused by Gram-positive cocci, including endocarditis, although further studies are warranted to determine the appropriate dose and adverse effects of daptomycin in neonates.

## Acknowledgements

We would like to thank the Pediatric Cardiology Department at King Saud Medical City.

## Declaration of interest

All Authors have no things to disclose. This is a case report, did not receive any specific grant from any funding agency in the public, commercial or not-for-profit sector

## References

1. Benvenuto M, Benziger DP, Yankelev S, Vigliani G. Pharmacokinetics and tolerability of daptomycin at doses up to 12 milligrams per kilogram of body weight once daily in healthy volunteers. *Antimicrob Agents Chemother.* 2006;50(10):3245-9.
2. Ardura MI, Mejías A, Katz KS, Revell P, McCracken GH Jr, Sánchez PJ. Daptomycin therapy for invasive Gram-positive bacterial infections in children. *Pediatr Infect Dis J.* 2007;26(12):1128-32.
3. Cohen-Wolkowicz M, Smith PB, Benjamin DK Jr, Fowler VG Jr, Wade KC. Daptomycin use in infants: report of two cases with peak and trough drug concentrations. *J Perinatol.* 2008;28(3):233-4.
4. Beneri CA, Nicolau DP, Seiden HS, Rubin LG. Successful treatment of a neonate with persistent vancomycin-resistant enterococcal bacteremia with a daptomycin-containing regimen. *Infect Drug Resist.* 2008;1:9-11.
5. Hussain A, Kairamkonda V, Jenkins DR. Successful treatment of methicillin-resistant *Staphylococcus aureus* bacteraemia in a neonate using daptomycin. *J Med Microbiol.* 2011;60(Pt 3):381-3.
6. Gostelow M, Gonzalez D, Smith PB, Cohen-Wolkowicz M. Pharmacokinetics and safety of recently approved drugs used to treat methicillin-resistant *Staphylococcus aureus* infections in infants, children, and adults. *Expert Rev Clin Pharmacol.* 2014;7(3):327-40.
7. Atkins, RL, Haase MR, Levy EN. Pharmacokinetics of daptomycin in a critically ill adolescent with vancomycin-resistant enterococcal endocarditis. *Pharmacotherapy.* 2006;26:694-8.
8. Sarafidis K, Iosifidis E, Gikas E, Tsivitanidou M, Drossou-Agakidou V, Roilides E. Daptomycin use in a neonate: serum level monitoring and outcome. *Am J Perinatol.* 2010;27(5):421-4.
9. Bradley JS, Benziger D, Bokesch P, Jacobs R. Single-dose pharmacokinetics of daptomycin in pediatric patients 3-24 months of age. *Pediatr Infect Dis J.* 2014;33(9):936-9.
10. Bhavnani SM, Rubino CM, Ambrose PG, Drusano GL. Daptomycin exposure and the probability of elevations in the creatine phosphokinase level: data from a randomized trial of patients with bacteremia and endocarditis. *Clin Infect Dis.* 2010;50(12):1568-74.