

Pharmacological treatment of ceftriaxone-related cholelithiasis in children: is it worthwhile?

Anna Maria Oggiano¹, Maria Grazia Clemente¹, Laura Cuzzolin², Cristian Locci¹, Claudia Maria Piredda¹, Kathleen B. Schwarz³, Roberto Antonucci¹

¹Pediatric Clinic, Department of Clinical and Experimental Medicine, University of Sassari, Sassari, Italy

²Department of Diagnostics & Public Health-Section of Pharmacology, University of Verona, Verona, Italy

³Pediatric Liver Center, Division of Pediatric Gastroenterology, Hepatology, and Nutrition, Johns Hopkins University School of Medicine, Baltimore, MD, USA

Abstract

Ceftriaxone treatment of bacterial infections can be associated with biliary complications, more commonly in children than adults, in a dose-dependent manner. This study describes a clinical case series of children with ceftriaxone-related cholelithiasis.

We performed a retrospective analysis of cases of ceftriaxone-related biliary complications admitted to the Pediatric Clinic, Department of Clinical and Experimental Medicine, University of Sassari, Italy, during the period 2005-2015.

Four children with cholelithiasis occurring during, or soon after, the treatment with ceftriaxone are reported. Case 1 (6-month-old), case 2 (9-year-old) and case 4 (10-year-old) were symptomatic, while case 3 (3-year-old) was asymptomatic. After the ultrasonographic diagnosis of gallstones (cases 1 and 2) or biliary sludge (cases 3 and 4), ceftriaxone treatment was withdrawn, and ursodeoxycholic acid (UDCA) was started in cases 1 and 2. A complete recovery was observed in all but case 1, in whom cholelithiasis was still detectable at one-year follow-up by ultrasonography. This case underwent a triple antibiotic protocol for bacterial meningitis. The protocol included rifampicin, which is known to have an effect in decreasing hepatic concentration of bile salts. Therefore, in this case, both rifampicin and UDCA were of no benefit in preventing or treating ceftriaxone biliary complications.

The current pharmacological approach for the treatment of ceftriaxone-related cholelithiasis seems to be ineffective, likely due to the high calcium content of gallstones. Therefore, the best strategy of intervention for ceftriaxone biliary complications in children remains the prevention of the risk factors.

Keywords

Biliary sludge, children, gallstones, pseudo-cholelithiasis, rifampicin, ursodeoxycholic acid.

Corresponding author

Prof. Roberto Antonucci, Pediatric Clinic, Department of Clinical and Experimental Medicine, University of Sassari, Sassari, Italy; tel.: +39 079 228239; e-mail: rantonucci@uniss.it.

How to cite

Oggiano AM, Clemente MG, Cuzzolin L, Locci C, Piredda CM, Schwarz KB, Antonucci R. Pharmacological treatment of ceftriaxone-related cholelithiasis in children: is it worthwhile? *J Pediatr Neonat Individual Med.* 2019;8(1):e080108. doi: 10.7363/080108.

Introduction

Cholelithiasis and biliary sludge (BS) are two uncommon conditions in childhood, even though the identification of these disorders has increased in the last decades [1-6].

Ceftriaxone, a semi-synthetic third-generation cephalosporin, is the principal causative agent of drug-induced cholelithiasis in pediatric practice [7, 8]. Following administration by parenteral route, preferably intravenously, it is widely distributed in most body tissues and fluids. Unlike most other cephalosporins (excluding cefotaxime), ceftriaxone penetrates the meninges, particularly when they are inflamed. Partially metabolized, it is mainly excreted through the urine (60-70%), and to a lesser extent in the bile (40%), where it can achieve concentrations 20- to 150-fold higher than in the blood, possibly resulting in the precipitation of ceftriaxone-calcium salts [9].

Ceftriaxone has a long half-life ranging from 9 to 15 hours in the neonatal period, while is about 8 hours at older ages. For this reason, it can be administered once daily for most infections except meningitis, where an every 12-hour regimen is required [10]. Depending on the severity of the disease, ceftriaxone dosage ranges from 50 to 100 mg/kg/day in children up to 12 years old, and 1 to 2 g/day in children aged 12 years or older.

As regards tolerability, the most common adverse effects of ceftriaxone are gastrointestinal and cutaneous [11, 12]. Systemic anaphylaxis is very uncommon, with an estimated risk of 0.0001% to 0.1%. Thrombocytosis, leukopenia and liver function test alterations may be observed

in less than 5% [11]. Among the adverse effects of ceftriaxone are cholelithiasis and BS [12], and more rarely also self-limited nephrolithiasis [13, 14], all favored by its excretion at high concentrations.

Ceftriaxone can interact with calcium leading to calcium-ceftriaxone precipitation [15], in preterm and term neonates resulting in severe reactions, including death [16, 17].

Cholelithiasis ceftriaxone-associated is usually defined as “biliary pseudolithiasis” (BP) or “reversible cholelithiasis” because it is a transient condition, which resolves after discontinuation of treatment. The incidence of this condition is variable, ranging between 8.6% and 57.5% in the pediatric population [3-5, 9, 12, 13], attributable to multiple factors that may influence the onset of this condition. The BS is more common among younger patients, and seems to be dose-dependent, as it is more frequent in children who receive a higher weight-dosage than adults, and favored by a high infusion rate: a short bolus infusion over 3-5 minutes is associated with a higher incidence compared to the administration in 30 minutes [12]. Restriction of oral intake and fasting are other risk factors for BP in children, because of their capacity to cause gallbladder dysfunction and biliary stasis. According to Shiffman et al. [18], a high dosage of ceftriaxone can result in BS in children with impaired gallbladder emptying.

All conditions able to interfere with bile flow (fasting, total parenteral nutrition, etc.) or with ceftriaxone excretion (renal failure, high dose or long-term treatment, surgery) might lead to an abnormal concentration of this medication in the biliary tract resulting in an increased risk of developing BS or BP.

The BS and BP occur within 2-9 days after initiation of therapy and usually resolve within 8-23 days after therapy discontinuation [19].

Currently, no clear recommendations are available concerning the management of pediatric ceftriaxone-related BP [3]. In this article, we performed a retrospective analysis of children with ceftriaxone-related biliary complications admitted to the Pediatric Clinic, Department of Clinical and Experimental Medicine, University of Sassari, Italy, during the period 2005-2015.

Clinical cases

Four cases of ceftriaxone-associated cholelithiasis and/or BS were identified during the study period. Demographic characteristics, dosage

and duration of ceftriaxone treatment, and biliary complications are summarized in **Tab. 1**, while **Tab. 2** shows the ultrasonographic features and pharmacological treatment of ceftriaxone-induced cholelithiasis at the diagnosis and during the follow-up.

Case 1

A 6-month-old boy was admitted to hospital for acute meningococcal meningitis and started therapy with high dose i.v. ceftriaxone (100 mg/kg/day), i.v. vancomycin (40 mg/kg/day), and oral rifampicin (20 mg/kg/day).

During hospitalization, abdominal ultrasounds (US) evaluation, performed due to the persistence of emesis, showed a regular gallbladder with thickened walls and the presence of at least two gallstones of 7 and 9 mm, respectively. At the 12th day of treatment, ceftriaxone was discontinued and ursodeoxycholic acid (UDCA) was started and maintained for 6 months at the dose of 10 mg/kg/day. At 1-year follow-up, the child appeared in good general health, and the ultrasonography showed only one small gallstone of 3.7 mm located at the infundibulum, despite UDCA treatment.

Case 2

A 9-year-old girl was admitted to hospital for suspected adenomesenteritis with upper airways bacterial infection. On admission, laboratory and

instrumental examinations (abdominal US) were normal (**Fig. 1A**). Because of the worsening of abdominal pain, antibiotic therapy with ceftriaxone was undertaken and fasting was started. After an initial improvement of symptoms abdominal pain recurred, therefore laboratory tests and abdominal US were repeated, revealing consistent with acute cholecystitis. Ceftriaxone was replaced by piperacillin, and ranitidine and paracetamol were started. A gradual clinical improvement was observed until complete resolution of symptoms. After 2 days of ceftriaxone discontinuation, US examination showed the presence of gallstones and BS (**Fig. 1B** and **Fig. 1C**). For this reason, UDCA therapy was maintained for 3 months. After 1 month, US imaging showed a complete resolution of BP.

Case 3

A 3-year-old girl came to our observation for Influenza B infection complicated by acute otitis media and severe gastroenteritis. Intravenous fluid therapy was started with little benefit, as anorexia, vomiting and diarrhea did not improve. For this reason, ceftriaxone treatment was started on the 9th day of hospitalization. Laboratory examinations showed high γ -glutamyl transferase serum levels (5 times upper normal level) with mild hypertransaminasemia (both AST and ALT 1.5 times upper normal levels). Abdominal US demonstrated the presence of BS (**Fig. 1D**).

Table 1. Main demographic characteristics, ceftriaxone treatment and biliary complications in the 4 patients.

Case	Age	Sex	Ceftriaxone therapy		Biliary complications		
			Dose (mg/kg)	Duration (days)	Onset	Symptoms	Type
1	6 months	M	100	12	Not known	Vomiting	Gallstones
2	9 years	F	65	3	2 nd day	Abdominal pain and nausea	Gallstones
3	3 years	F	70	4	Not known	None	BS
4	10 years	M	50	6	1 week after	Heartburn (with irradiation to right shoulder) and nausea	BS

BS: biliary sludge.

Table 2. Ultrasonographic features and pharmacological treatment of ceftriaxone-induced cholelithiasis at the diagnosis and at follow-up.

Case	Abdominal US at the diagnosis	Pharmacological treatment	Abdominal US at follow-up
1	Thickened gallbladder walls and gallstones of 7-9 mm	Oral UDCA (10 mg/kg/day) Oral rifampicin ^a (20 mg/kg/day)	Reduction of gallstones number and size (3.7 mm) 1 year later
2	Gallstones of about 2-5 mm	Oral UDCA (10 mg/kg/day)	No gallstones at 3-month follow-up
3	BS	None	Not performed
4	BS	None	No gallstones at 10-day follow-up

US: ultrasounds; UDCA: ursodeoxycholic acid; BS: biliary sludge.

^a Prescribed for the treatment of bacterial meningitis.

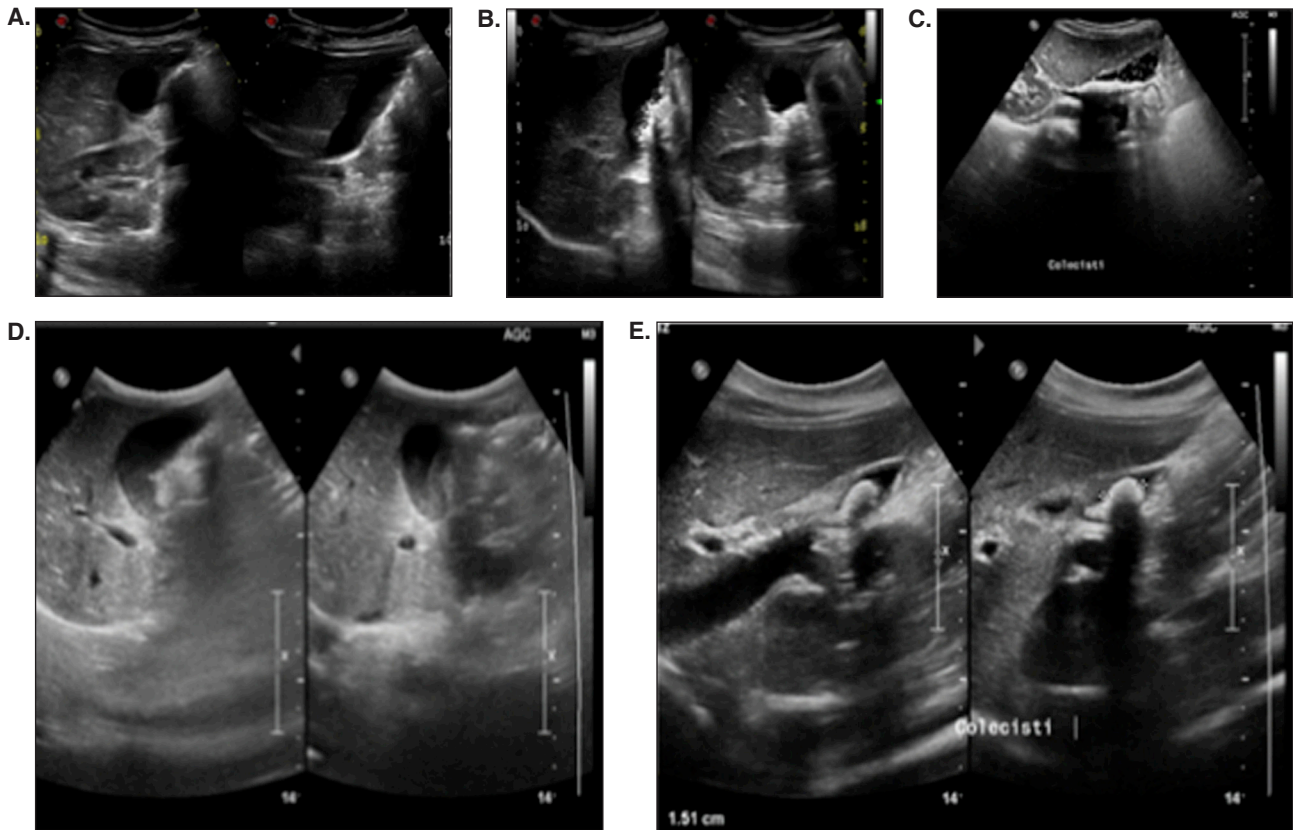


Figure 1. **A.** Case 2: abdominal ultrasounds (US) at hospital admission (before ceftriaxone treatment) shows a normal gallbladder. **B-C.** Case 2: abdominal US during ceftriaxone treatment shows gallstones of about 2 and 5 mm (**B**) and biliary sludge (BS) (**C**), respectively. **D.** Case 3: BS. **E.** Case 4: BS.

Therefore, ceftriaxone therapy was discontinued while the infusion support was maintained. In the following days, resumption of appetite and complete clinical recovery were observed.

Case 4

A 10-year-old boy was admitted to hospital for profuse diarrhea, severe abdominal pain associated with bacterial tonsillitis. On admission, the patient presented with dehydration and a mild increase in serum total bilirubin (2.1 mg/dl). Molecular analysis of the *UGT1A1* gene revealed a homozygous genotype compatible with Gilbert's syndrome [20]. Treatment consisted of i.v. fluid support and antibiotic therapy with ceftriaxone. The patient was discharged on the 6th day of hospitalization. During the follow-up, heartburn with right shoulder irradiation and nausea were reported. Abdominal US scan revealed the presence of BS (**Fig. 1E**), while laboratory tests showed reduced serum total bilirubin (1.2 mg/dl), hypertransaminasemia (AST 1.5 times upper normal level; ALT 5 times upper normal level) and increased serum levels of γ -glutamyl transferase

(1.5 times upper normal level). Ten days later, a subsequent US scan showed the disappearance of BS along with the resolution of associated symptoms.

Discussion

Ceftriaxone is a cephalosporin extensively used in daily practice, especially in childhood, due to its efficacy, safety and long half-life. Ceftriaxone-related BP is an important cause of abdominal pain in children undergoing such therapy.

It has been shown that ceftriaxone-related cholelithiasis is a condition benign and reversible with discontinuation of therapy, within 15 days on average [12]. If this complication is suspected, an abdominal US should be performed. A conservative approach is advocated and surgery is usually not necessary [3].

In our clinical case series, the youngest patient, aged 6 months, was under triple-antibiotic therapy for bacterial meningitis while the other 3 children were treated with ceftriaxone for less severe bacterial infections. Ceftriaxone therapy was given at high doses in all patients, and the length of

treatment ranged from 3 to 12 days. Three children complained cholelithiasis clinical symptoms, while one was asymptomatic. Therefore, both symptomatic and asymptomatic presentations were observed, as reported by other authors [3-6]. In the only asymptomatic patient, laboratory findings of elevated liver enzymes led to further investigation by abdominal US. In all cases, abdominal US revealed BP or BS, and thus ceftriaxone therapy was promptly discontinued. Two patients (cases 1 and 2) received UDCA for a period of 6 and 3 months, respectively. The complete recovery after therapy withdrawal was observed in all but one case. In this latter case, cholelithiasis developed during ceftriaxone treatment, with a subsequent reduction but not a complete clearance at 1-year follow-up.

By chance, one of our cases underwent the combined use of rifampicin, prescribed as part of the triple antibiotic protocol for bacterial meningitis treatment, along with UDCA. Rifampicin is known to have an effect in decreasing hepatic concentration of bile salts [21]. In this child, cholelithiasis, even if reduced, was still detectable at US at 1-year follow-up, despite rifampicin and UDCA treatment. Combined use of rifampicin and UDCA has been recently proposed for the treatment of advanced cholestatic liver disease: their mechanisms of action have been described to be independent and complementary [22], but without synergic effects on the hepatobiliary system [23]. In pediatric cholestasis, rifampicin has application mainly as anti-pruritic agent [21]. This mechanism of action is exerted: (1) by enhancing bilirubin elimination at the canalicular membrane and at the intestinal mucosa; (2) by stimulating the hepatic detoxification CYP-3A4 and UGT1A1 enzymes [22]. In contrast, UDCA acts mostly on the expression of hepato-biliary ABC transporter proteins [22]. Moreover, higher UDCA concentration in the bile would determine a significant reduction of bile lithogenic index [22]. Based on our results, the efficacy of UDCA for the treatment of ceftriaxone-related BP is questionable and not predictable. The high content of calcium is likely the reason for the lack of efficacy of current pharmacological approach for the treatment of this condition.

Conclusions

Ceftriaxone is an important causative agent of BP and BS in pediatric practice. These adverse effects are dose-dependent and result from the biliary drug excretion at high concentrations.

The current pharmacological approach for the treatment of ceftriaxone-related cholelithiasis seems to be ineffective, likely due to the high calcium content of gallstones. Therefore, the best strategy of intervention for ceftriaxone hepato-biliary complications in children remains the prevention of the risk factors.

Abbreviations

ABC: ATP binding cassette
 BP: biliary pseudolithiasis
 BS: biliary sludge
 i.v.: intravenous therapy
 UDCA: ursodeoxycholic acid
 UGT: UDP-glucuronosyltransferase
 US: ultrasounds

Declaration of interest

All Authors have declared that no potential conflicts of interest that are relevant to the manuscript exist and all the Authors have nothing to disclose.

References

1. Wesdorp I, Bosman D, de Graaff A, Aronson D, van der Blij F, Taminiau J. Clinical presentations and predisposing factors of cholelithiasis and sludge in children. *J Pediatr Gastroenterol Nutr.* 2000;31(4):411-7.
2. Palasciano G, Portincasa P, Vinciguerra V, Velardi A, Tardi S, Baldassarre G, Albano O. Gallstone prevalence and gallbladder volume in children and adolescents: an epidemiological ultrasonography survey and relationship to body mass index. *Am J Gastroenterol.* 1989;84:1378-82.
3. Della Corte C, Falchetti D, Nebbia G, Calacoci M, Pastore M, Francavilla R, Marcellini M, Vajro P, Iorio R. Management of cholelithiasis in Italian children: a national multicenter study. *World J Gastroenterol.* 2008;14(9):1383-88.
4. Gökçe S, Yıldırım M, Erdoğan D. A retrospective review of children with gallstone: single-center experience from Central Anatolia. *Turk J Gastroenterol.* 2014;25(1):46-53.
5. Serdaroglu F, Koca YS, Saltık F, Koca T, Dereci S, Akcam M, Akcam FZ. Gallstones in childhood: etiology, clinical features, and prognosis. *Eur J Gastroenterol Hepatol.* 2016;28(12):1468-72.
6. Tuna Kirsaclioglu C, Çuhacı Çakır B, Bayram G, Akbıyık F, Işık P, Tunç B. Risk factors, complications and outcome of cholelithiasis in children: A retrospective, single-centre review. *J Paed Child Health.* 2016;52(10):944-9.
7. Poddar U. Gallstones disease in children. *Indian Pediatr.* 2010;47(11):945-53.
8. Schweizer P, Lenz MP, Kirschner HJ. Pathogenesis and symptomatology of cholelithiasis in childhood. *Dig Surg.* 2000;17:459-67.

9. von Martels JZH, Van de Meeberg EK, Holman M, Ligtenberg JJ, Ter Maaten JC. Pseudolithiasis after recent use of ceftriaxone: an unexpected diagnosis in a child with abdominal pain. *Am J Emerg Med.* 2013;31(8):1294.e5-6
10. Yaffe SJ, Aranda JV. *Neonatal and Pediatric Pharmacology: Therapeutic Principles in Practice.* 4th edition. Philadelphia: Lippincott Williams & Wilkins, 2010.
11. Ozturk A, Kaya M, Zeyrek D, Ozturk E, Kat N, Ziylan SZ. Ultrasonographic findings in ceftriaxone-associated biliary sludge and pseudolithiasis in children. *Acta Radiologica.* 2005;46(1):112-16.
12. Schaad UB, Wedgwood-Krucko J, Tschaeppler H. Reversible ceftriaxone-associated biliary pseudolithiasis in children. *Lancet.* 1988;2(8625):1411-3.
13. Ustyol L, Bulut MD, Agengin K, Bala KA, Yavuz A, Bora A, Demiroren K, Dogan M. Comparative evaluation of ceftriaxone- and cefotaxime-induced biliary pseudolithiasis or nephrolithiasis: A prospective study in 154 children. *Hum Exp Toxicol.* 2017;36(6):547-53.
14. Mohkam M, Karimi A, Gharib A, Daneshmand H, Khatami A, Ghojevand N. Ceftriaxone associated nephrolithiasis: a prospective study in 284 children. *Pediatr Nephrol.* 2007;22(5):690-4.
15. Schmutz HR, Detampel P, Bühler T, Büttler A, Gygax B, Huwyler J. In vitro assessment of the formation of ceftriaxone-calcium precipitates in human plasma. *J Pharm Sci.* 2011;100(6):2300-10.
16. Bradley JS, Wassel RT, Lee L, Nambiar S. Intravenous ceftriaxone and calcium in the neonate: assessing the risk for cardiopulmonary adverse events. *Pediatrics.* 2009;123(4):e609-13.
17. Donnelly PC, Sutich RM, Easton R, Adejumo OA, Lee TA, Logan LK. Ceftriaxone-Associated Biliary and Cardiopulmonary Adverse Events in Neonates: A Systematic Review of the Literature. *Pediatr Drugs.* 2017;19(1):21-34.
18. Shiffman ML, Keith FB, Moore EW. Pathogenesis of ceftriaxone-associated biliary sludge. In vitro studies of calcium-ceftriaxone binding and solubility. *Gastroenterology.* 1990;99(6):1772-8.
19. Papadopoulou F, Efremidis S, Karyda S, Badouraki M, Karatza E, Panteliadis C, Malaka, K. Incidence of ceftriaxone associated gallbladder pseudolithiasis. *Acta Paediatrica.* 1999;88(12):1352-5.
20. Fretzayas A, Liapi O, Papadopoulou A, Nicolaidou P, Stamoulakatou A. Is ceftriaxone-induced biliary pseudolithiasis influenced by UDP-glucuronosyltransferase 1A1 gene polymorphisms? *Case Rep Med.* 2011;2011:730250.
21. Clemente MG, Schwarz K. Hepatitis: General principles. *Pediatr Rev.* 2011;32(8):333-40.
22. Marschall HU, Wagner M, Zollner G, Fickert P, Diczfalusy U, Gumhold J, Silbert D, Fuchsichler A, Benthin L, Grundström R, Gustafsson U, Sahlin S, Einarsson C, Trauner M. Complementary Stimulation of Hepatobiliary Transport and Detoxification Systems by Rifampicin and Ursodeoxycholic Acid in Humans. *Gastroenterology.* 2005;129(2):476-85.
23. Marschall HU, Wagner M, Zollner G, Fickert P, Silbert D, Gustafsson U, Sahlin S, Trauner M. Combined rifampicin and ursodeoxycholic acid treatment does not amplify rifampicin effects on hepatic detoxification and transport systems in humans. *Digestion.* 2012;86(3):244-9.