

Selected Abstracts of the 8th International Congress of UENPS

• Session “Perinatal neurologic disorders and their long-term impact on development. Ethical issues”

BUCHAREST (ROMANIA) • OCTOBER 3RD-5TH 2018

The Congress has been organized by the Union of European Neonatal and Perinatal Societies (UENPS).

PRESIDENTS

Manuel Sánchez Luna, UENPS President
Silvia Maria Stoicescu, UENPS 8th Congress President

UENPS EXECUTIVE COMMITTEE

President: Manuel Sánchez Luna; **Vice President:** Corrado Moretti; **General Secretary:** Artur Beke; **Treasurer:** Gabriel Dimitriou; **Members:** Rosalina Barroso, Rasa Tameliene, Heili Varendi; **Supervisory Committee:** Giuseppe Buonocore, Boris Filipovic-Grcic, Nelly Jekova; **Executive Committee:** Maria Livia Ognean

SCIENTIFIC COMMITTEE

Manuel Sánchez Luna, Silvia Maria Stoicescu, Corrado Moretti, Artur Beke, Gabriel Dimitriou, Rosalina Barroso, Rasa Tameliene, Heili Varendi, Giuseppe Buonocore, Boris Filipovic-Grcic, Nelly Jekova, Maria Livia Ognean

MEMBERS OF UENPS

Association of Neonatologists of Georgia; Association of Neonatologists of Ukraine; Bulgarian Neonatology Association; Croatian Association for Neonatology and Neonatal Intensive Care; Croatian Association of Perinatal Medicine; Czech Neonatology Society; Estonian Perinatal Society; French Society of Neonatology; Hellenic Neonatal Society; Hungarian Society of Perinatology and Obstetric Anesthesiology; Irish Neonatal Society; Israeli Neonatal Association; Italian Neonatal Society; Italian Society of Perinatal Medicine; Latvian Neonatal Society; Lithuanian Neonatal Association; Macedonian Association of Perinatal Medicine; Neonatal Society of Bosnia and Herzegovina; Polish Neonatal Society; Portuguese Neonatal Society; Romanian Association of Neonatology; Romanian Society of Perinatal Medicine; Russian Neonatal Society; Serbian Association of Neonatal Medicine; Slovakian Paediatrics Society; Slovenian Neonatal Society; Spanish Society of Neonatology; The Finnish Society of Perinatology; Turkish Neonatal Society



Union of European
Neonatal & Perinatal
Societies

Organizing secretariat



How to cite

[Abstract's authors]. [Abstract's title]. In: Selected Abstracts of the 8th International Congress of UENPS; Bucharest (Romania); October 3rd-5th 2018; Session "Perinatal neurologic disorders and their long-term impact on development. Ethical issues". J Pediatr Neonat Individual Med. 2018;7(2):e070234. doi: 10.7363/070234.

ABS 1

QUALITATIVE CEREBRAL ABNORMALITIES AT TERM MRI IN THE PREMATURE INFANT AND CORRELATION WITH PREVIOUS CUS FINDINGS AND NEURODEVELOPMENTAL OUTCOME COMPONENTS AT 24 MONTHS OF CORRECTED GESTATIONAL AGE

K. Chatzidimitriou, A. Chebsey, D. Odd, M. El Brookle, M. Likeman, A. Heep

Neonatal Intensive Care Unit, Southmead Hospital, Bristol, UK

Imaging Department, Southmead Hospital, Bristol, UK

Neonatal Neurology Group, School of Clinical Sciences, University of Bristol, Bristol, UK

BACKGROUND

Preterm birth is associated with a variety of white matter injury (WMI) and sub-optimal neurodevelopment.

Cranial ultrasound (CUS) seems less sensitive for subtle brain damage in very preterm infants. MRI at term equivalent, being more sensitive in revealing subtle brain changes, is frequently used in order to overcome this gap.

OBJECTIVE

To describe the incidences of subtle brain abnormalities in MRI in very preterm infants. To compare MRI findings with CUS performed at day 7 and to find a possible predictive value for neurodevelopmental outcome at 24 months of corrected gestational age.

MATERIALS AND METHODS

Design

Retrospective observational study in a single Level III neonatal intensive care unit.

Patients

From the initial cohort of 128 infants, born at less than 28 weeks of gestation in 2 years (2013-2014), 33 infants were eligible and subjected to statistical analyses. Mean gestational age was 26 (23.4-28, SD 1.32). Mean birth weight 778.8 g (453-1,216 g, SD 233.5), 16 (48.5%) males and 17 (51.5%) females.

Methods

CUS at day 7 and MRI at term were performed according to standard protocols.

CUS intraventricular hemorrhage (IVH) classification was based on that of Papile, whereas WMI in MRI was classified using the extent of injury in T1/T2 sequences and the presence of WM volume loss, cysts, thinning of the corpus callosum and ventriculomegaly (VM).

Bayley was classified using composite scores (cutoff value 85) and months of developmental delay.

SPSS® version 20 was used for statistical analyses.

RESULTS

Mean gestational age at MRI was 40 (34.1-50.5, SD 3.8).

WMI was found in 13 infants (36.4%), whereas grey matter injury (GMI) in 6 (18.2%) and VM in 16 (48.4%).

IVH was present in 14 babies (42.4%), PVL in 3 (9.1%), WM loss in 5 (15.2%) and cerebellar and subarachnoid space changes in 6 (18.2%).

Myelin damage was found in 2 infants (6.1%).

When comparing with CUS brain injury at day 7, IVH, parenchymal injury (PI) and VM at day 7 correlated significantly with VM, WM haemorrhage, IVH, WM loss and WMI in MRI (**Tab. 1**).

CUS IVH was linked to myelin damage in MRI ($p = 0.026$) but did not correlate with WM loss ($p = 0.088$) or cPVL ($p = 0.862$).

PI was additionally a good predictor of GMI in MRI ($p = 0.008$).

When comparing MRI findings with Bayley outcome at 24 months, only VM ($p = 0.029$) and cPVL ($p = 0.001$) correlated with general delay, whereas cerebellar damage was linked to motor composites < 85 ($p = 0.028$) (**Tab. 1**).

Cognitive outcome correlated with GMI ($p = 0.049$), whereas the speech component tended to correlate with both GMI and WM loss ($p = 0.067$).

CONCLUSION

MRI detects a host of subtle brain changes.

CUS at day 7 predicted most brain damages seen in MRI. cPVL and VM in MRI can have a predictive value for general neurodevelopmental delay at 24 months.

GMI is associated with poor cognitive outcome, whereas cerebellar damage with poor motor outcome.

Early detection in CUS using mastoid view may favor early intervention.

Table 1 (ABS 1). Cranial ultrasound (CUS) findings at day 7 and subtle changes in MRI.

			CUS findings day 7			Bayley 24 m	Motor component < 85 at 24 m
			IVH (1-4)	VM CUS day 7 (yes)	PI at CUS day 7 (yes)		
			0: 20 (60.6%) I: 4 (12.1%) II: 3 (9.1%) III: 2 (6.1%) IV: 4 (12.1%)	8 (24.2%)	5 (15.2%)	Normal: 12 (36.4%) Mild: 5 (15.2%) Moderate: 1 (3%) Severe: 2 (6.1%) Missed: 13 (39.4%)	Yes: 4 (12.1%) Missing: 13 (39.4%)
Subtle changes in MRI	VM MRI	16 (48.5%)	0.033	0.001	0.012	0.029	0.110
	WM haemorrhage	9 (27.3%)	0.011	0.01	0.004	0.639	0.780
	Myeline damage	2 (6.1%)	0.026	0.38	0.538	0.513	0.246
	Cerebellar damage	6 (18.2%)	0.217	0.104	0.909	0.629	0.028
	Subarachnoid space enlargement	6 (18.2%)	0.843	0.632	0.909	0.203	0.348
	WM loss	5 (15.2%)	0.088	0.043	0.002	0.402	0.264
	WMI	13 (39.4%)	0.035	0.009	0.033	0.857	0.752
	GMI	6 (18.2%)	0.217	0.104	0.008	0.629	0.53
	IVH MRI	14 (42.4%)	0.029	0.003	0.005	0.755	0.639
	cPVL	3 (9.1%)	0.862	0.177	0.609	0.000	0.741

CUS: cranial ultrasound; IVH: intraventricular hemorrhage; VM: ventriculomegaly; PI: parenchymal injury; WMI: white matter injury; GMI: grey matter injury.

ABS 2

ASSOCIATION OF IUGR AND OTHER BASELINE CHARACTERISTICS WITH BRAIN INJURY AND NEURODEVELOPMENTAL OUTCOME AT 24 MONTHS OF CORRECTED GESTATIONAL AGE IN A PREMATURE INFANT COHORT

K. Chatzidimitriou, A. Chebsey, D. Odd, M. El Brookle, M. Likeman, A. Heep

Neonatal Intensive Care Unit, Southmead Hospital, Bristol, UK

Imaging Department, Southmead Hospital, Bristol, UK

Neonatal Neurology Group, School of Clinical Sciences, University of Bristol, Bristol, UK

INTRODUCTION

Brain injury is frequently seen in preterm infants and is linked with suboptimal neurodevelopment. Cranial ultrasound (CUS) identifies reliably intraventricular hemorrhage (IVH), ventriculomegaly (VM) and parenchymal injury. MRI at term is increasingly performed to study subtle injury.

OBJECTIVE

To associate baseline traits with brain injuries, detected by CUS at day 7 and MRI at term, in preterm infants born at less than 28 weeks of gestational age

(GA). Second, to detect possible correlations with neurodevelopmental (ND) outcome (Bayley III) at 12 and 24 months of life.

METHODS

Retrospective observational cohort study in a single Level III neonatal intensive care unit. All infants admitted at less than 28 weeks of gestation to a single tertiary neonatal intensive care unit between 2013-2014 were eligible for the study (n = 128). Mean GA was 25.8 (23-28, SD 1.32). Baseline traits: Mean birth weight (BW) 785.8 g (437-1,268 g, SD 205.7), 71 (55.5%) were male and 15 (11.7%) IUGR. 15 babies were ureaplasma positive (11.7%) CUS at day 7 and MRI at term were performed according to clinical protocols. CUS IVH classification was based on that of Papile. White matter injury (WMI) in MRI was classified based on the extent of injury in T1/T2 sequences and the presence of WM volume loss, cysts, thinning of the corpus callosum and VM. Bayley was classified using months of ND delay. SPSS® version 20 was used for statistical analyses (chi-square).

RESULTS

In CUS, 13 neonates had IVH at day 54 (42.2%), 33 (25.8%) were stage 1-2, whereas 23 (28%) stage 3-4. Parenchymal injury was found in 16 patients (12.5%) and VM in 8 (28%). MRI at term showed WMI in

16 infants (12.5%) and GMI (grey matter injury) in 7 (5.5%). 3 patients (2.3%) had cPVL in MRI. Using the chi square test, GA was associated with IVH at day 7 ($p = 0.023$), grade of IVH ($p = 0.016$), WMI in MRI ($p = 0.05$), Bailey score at 12 months ($p = 0.000$) but not with Bailey at 24 months ($p = 0.270$). There was no gender difference in CUS brain lesions and Bailey score, but WMI in MRI was linked to males ($p = 0.003$). IUGR did not correlate with a higher incidence of any brain injury or Bailey score performed at 12 months, but a tendency to poor ND outcome at 24 months was noted ($p = 0.071$). Ureaplasma infection was not associated with any brain injury, detected early (CUS) or late (MRI), or poor ND outcome.

CONCLUSION

As reported in the literature, GA is an important factor for both early and late detected brain damage and is associated with poor ND outcome at 12 months, but interestingly not with the Bailey score at 24 months. Males are likely to suffer more often from WMI, otherwise there are no gender differences in brain injuries or ND outcome. Ureaplasma infection plays no role in brain injuries of prematurity or ND outcome. On the other hand, IUGR tends to link only with poor ND outcome at 24 months of age, but there is no association with early or late brain damage in premature babies of less than 28 weeks of GA.

ABS 3

NEONATAL SEIZURES: A RETROSPECTIVE STUDY OF 146 CASES IN A NICU IN TUNISIA

H. Ben Hamida¹, F.Z. Chioukh¹, T. Khemis¹, N. Djobbi¹, K. Ben Ameer¹, C. Hafsa², M. Doggui³, M. Bizid¹, K. Monastiri¹

¹Intensive Care and Neonatal Medicine Department, Teaching Hospital of Monastir, University of Monastir, Monastir, Tunisia

²Department of Radiology B, Teaching Hospital of Monastir, University of Monastir, Monastir, Tunisia

³Department of Neurophysiology, Sahloul Teaching Hospital, Sousse, Tunisia

INTRODUCTION

Neonatal seizures are one of the most common neonatal neurological issues. This is a diagnostic and therapeutic emergency considering the vital and functional risks.

AIM

To study the epidemiological, clinical, etiological and outcome aspects of neonatal seizures in the short, medium and long term.

POPULATION AND METHODS

This is a retrospective study based on all newborns that had seizures and were managed in the NICU and neonatal medicine department of the Teaching hospital of Monastir during the study period (June 12, 2009 to December 31, 2015) (6.5 years). The diagnosis was made clinically, and patients received EEG, MRI and specific exams when needed.

RESULTS

146 cases of seizures were identified. The incidence of neonatal seizures was 3.7‰ and the frequency was 0.88% of all hospitalization. Sex-ratio was 1.35. Term newborns accounted for 87% of cases and SGA occurred in 14.4% of cases. An Apgar score of less than 7 in the fifth minute was noted in 26% of cases. Half of the newborns had seizures in their first 24 hours of life. The seizures lasted less than 2 min in 90% of cases. Nearly half of the newborns (52%) had a single, non-recurring seizure with a maximum of twice repeated in 35% of cases. The seizures were essentially generalized (65%): clonic (39%) and tonic (30%) seizures. A status epilepticus occurred in 20 newborns (13.7%). The first-line treatment was phenobarbital (82%) then the use of clonazepam (11%), midazolam (4 cases) and vitamin B6 in 2 cases. Perinatal asphyxia was the most common cause of seizures (52 cases) followed by hypocalcaemia (12 cases), cerebral haemorrhage (11 cases), inherited metabolic diseases (10 cases), bacterial meningitis (8 cases) and brain malformations (9 cases). Outcomes were marked by the recurrence of seizures in 37% of cases (54 cases), death in 33% of cases (48 cases), global development delay in 24% of cases (19 cases), epilepsy in 14.3% of cases (14 cases), neuro-sensory sequelae in 19% of cases (19 cases) and cerebral palsy in 11% of cases (11 cases).

CONCLUSION

Seizures are a common and serious incident in the neonatal period. The prognosis remains severe with a high risk of sequelae. This justifies urgent care and etiological investigation to avoid recurrence; prognosis depends on the cause.

ABS 4

ANTENATAL AND POSTNATAL RISK FACTORS IN NEONATAL SEIZURES

F. Doandes^{1,2}, A. Manea¹, O. Costescu^{1,2}, D. Cioboata², N. Lungu², M. Boia¹

¹Neonatology Department, “Victor Babes” University of Medicine and Pharmacy, Timisoara, Romania

²Premature-Neonatology Department, “Louis Turcanu” Children’s Emergency Hospital, Timisoara, Romania

INTRODUCTION

Seizures are frequent manifestations in neonatal pathology. Identifying and avoiding risks for neonatal seizures may lead to lower infant neurological morbidity and mortality.

AIMS

The authors intend to study the antenatal and postnatal risk factors of neonatal seizures and the associated pathology of seizures.

MATERIAL AND METHODS

A 2-year prospective study in the Preterms and Neonatology Department of the “Louis Turcanu” Children’s Emergency Hospital, Timisoara, on a group of 80 patients, term and preterm neonates. We included in the study newborns with onset of seizures in the first 28 days of life.

RESULTS

The most common antenatal risk factors associated with neonatal seizures were: urinary and vaginal infections (17.5%), preeclampsia (10%), delivery \geq 42 weeks (10%), diabetes mellitus (5%), placenta previa (2.5%) and uncontrolled pregnancies. Neonatal pathologies associated with convulsive syndrome, with slow and serious evolution were: neonatal sepsis (17.5%), respiratory distress syndrome (12.5%), congenital pneumonia (5%), pulmonary air leak (5%), and congenital heart malformations (2.5%). Mortality in the study group was 2.5% in severe forms of disease, with severe associated pathology.

CONCLUSIONS

Prenatal risk factors most often involved were urogenital infections, followed by delivery after 42 weeks of gestational age and preeclampsia. Neonatal respiratory distress syndrome and neonatal sepsis were the most often associated diseases.

ABS 5

CHANGES IN MORTALITY AMONG EXTREMELY PRETERM INFANTS IN THE SOUTH OF THAILAND: A 15-YEAR EXPERIENCE

W. Janjindamai, B. Thirapaleka, A. Thatrimontrichai, G. Maneenil, S. Dissaneevate

Department of Pediatrics, Faculty of Medicine, Prince of Songkla University, Hat Yai, Thailand

INTRODUCTION

The perception in neonatal care over the last few decades is that there has been a significant reduction in mortality and morbidity for extremely preterm infants (gestational age < 29 weeks). There have also been changes in the prenatal use of glucocorticoids and antibiotic agents, use of surfactants and ventilation strategies. However, it remains unclear whether or not these advances have resulted in better outcomes for extremely preterm infants. Understanding the timing and causes of death in extremely preterm infants may guide us in counseling the families. The primary objectives of this study were to evaluate pre-discharge neonatal mortality, morbidity and associated risk factors in a 15-year experience of extremely preterm infants at the Songklanagarind Hospital in Thailand.

MATERIALS AND METHODS

This was a retrospective cohort study of extremely preterm infants of gestational age < 29 weeks, who were born and admitted to the neonatal intensive care unit between January 2001 and December 2015. The study was divided into two periods: 2001-2009 and 2010-2015. The mortality rates by gestational age were compared by survival analysis using the Kaplan-Meier method. A p-value < 0.05 was considered statistically significant.

RESULTS

After excluding 2 infants due to congenital anomalies, a total of 133 extremely preterm infants were enrolled. Seventy-eight infants (58%) were female. The overall mortality rate was 49/133 (36.8%) and was significantly higher in the lower gestational age infants ($p < 0.05$). The mortality rate between 2004-2009 and 2010-2015 decreased from 44% to 32.5% but this was not statistically significant ($p = 0.253$). The most common cause of death in the first period was respiratory distress syndrome (41%). However, in the second period, neonatal sepsis (46%) was the common cause of death. Multivariate analysis showed perinatal risk factors of mortality rate were lower gestation age and birth weight less than 750 grams (odds ratio = 6.8, 95% CI 0.9-0.9, $p = 0.001$) (Fig. 1).

CONCLUSIONS

Although there was no significant trend in neonatal survival or composite morbidity over the decade, improvement in survival was demonstrated with increasing gestational age and birth weight of more than 750 grams.

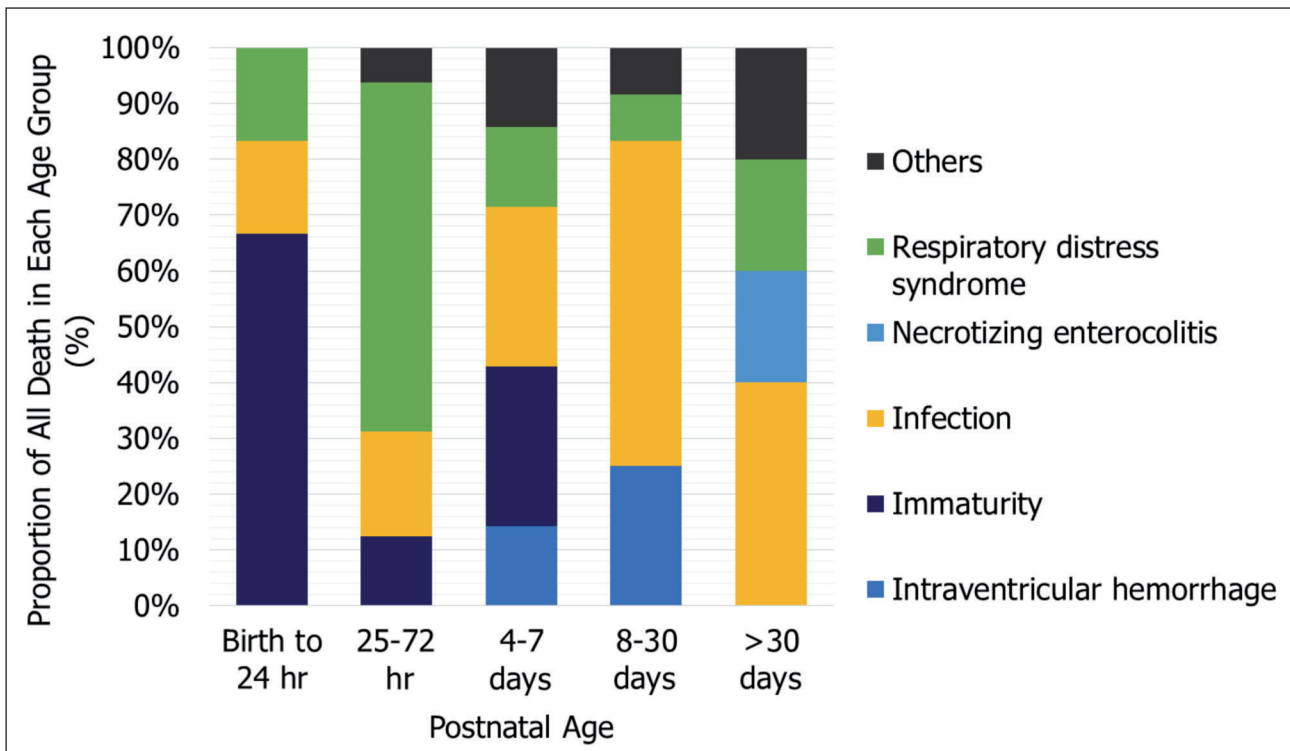


Figure 1 (ABS 5). Proportionate mortality for major causes of death, according to postnatal age.

ABS 6

INTRAVENTRICULAR HEMORRHAGE: RISK FACTORS AND PROGNOSIS IN VERY PRETERM INFANTS

A. Bezzine, R. Boukhris, Y. Mesbahi, B. Rabii, E. Ben Hamida, Z. Marrakchi

Neonatology Department, Charles Nicolle University Hospital of Tunis, Tunis, Tunisia

INTRODUCTION

Intraventricular hemorrhage (IVH) is still a health problem particularly in very premature infants. We sought to determine risk factors and prognosis for this population in a Tunisian third level NICU.

METHODS

We conducted a retrospective study, at the NICU of the Charles Nicolle Hospital of Tunis (Tunisia), from June 2016 to December 2017. We included all very preterm infants (less than 33 GW) born in our maternity facility.

RESULTS

A total of 4,770 infants were born. Premature infants (less than 37 GW) were 487 (10.2%). Very preterm infants were 115 (2.4%), of these, 22 infants were extremely preterm. Gestational age was 30 ± 2 GW. The prematurity was spontaneous in 51.8% of cases.

Antenatal corticosteroids had been administered in 89.5% pregnancies. Cranial ultrasound discovered IVH in 38 infants (33.3%): grade 1: 32.4%, grade 2: 13.5%, grade 3: 16.5% and grade 4: 2.7%. The diagnosis was made in the first three days in 54.7% of cases and the first week in 88.6%. The occurrence of toxemic gravid and perinatal asphyxia had odds of 1.2 and 3.6 respectively. Resuscitation in the delivery room was associated with higher odds of IVH (OR 2.34). Infants' characteristics and initial morbidities associated with odds of IVH were respectively: small for gestational age (OR 3.9), very small for gestational age (OR 2.7), respiratory distress syndrome (OR 3.3), patent ductus arteriosus (OR 8.6) and the use of synchronized intermittent mandatory ventilation (OR 13.8) and high frequency ventilation (OR 4.7). Other statistically significant risk factors during the evolution were respectively: hemodynamic issues (OR 3.7), nosocomial infection (OR 4.9), early onset infection (OR 5.3), necrotizing enterocolitis (OR 3), hyperglycemia (OR 8.4), disseminated intravascular coagulation (OR 8.3), use of vasopressors drugs (OR 3.9). The occurrence of anemia and thrombocytopenia had high odds (OR 15.7 and 4.7, respectively). The use of phototherapy had higher adjusted odds (OR 4.7). The need for red blood cells transfusion was also associated with high odds (OR 9.8). The onset of abnormal movement was present in 19 infants

(16.7%). IVH was complicated by hydrocephaly in 7 cases and by porencephaly in 1 case. Cerebral abnormalities in MRI were seen in 86.6% of the infants. Electroencephalography abnormalities was noted in 12.5% of the infants. Ophthalmologic disabilities were diagnosed in 16.7% of the infants. Higher adjusted odds of mortality death incidence was 27.2% (OR 2.7).

CONCLUSION

IVH leads to lifelong neurodevelopmental disabilities. Early bedside detection of IVH is crucial to enable timely intervention.

ABS 7

NEONATAL ARTERIAL ISCHEMIC STROKE: A STUDY OF 14 CASES

A. Ben Thabet¹, F. Charfi¹, A. Ben Hamad¹, M. Charfi¹, Ch. Regaieg¹, N. Hamida¹, F. Kammoun², Ch. Triki², R. Regaieg¹, A. Bouraoui¹, A. Gargouri¹

¹Department of Neonatology, Hedi Chaker University Hospital, Sfax, Tunisia

²Department of Neuropediatrics, Hedi Chaker University Hospital, Sfax, Tunisia

INTRODUCTION

The frequency of neonatal arterial ischemic stroke (NAIS) is about 1/2,500 to 1/5,000 in term neonates. It is a cause of perinatal brain injury, cerebral palsy, and lifelong disability. The pathogenesis is poorly understood, which limits the development of treatment and prevention strategies.

METHODS

This is a retrospective study carried out from 2013 to 2018, including 14 neonates with acute symptomatic NAIS, who were admitted to the Neonatology Department of the Hedi Chaker University Hospital in Sfax, Tunisia.

RESULTS

The average term was 39 weeks. There were 3 twin pregnancies and 2 were complicated by intrauterine fetal death. Apgar scores were normal in all patients. The first symptoms appeared most frequently during the first three days of life. The most common signs were early seizures (8 patients) and focal neurological deficit. Four patients had hypotonia. In one case, the diagnosis was confirmed by cranial ultrasonography in a patient with repeated apnea. Cranial ultrasonography was performed on all patients and cerebral MRI on only 7 babies. Supra aortic trunk ultrasonography showed carotid dissection in one patient. Echocardiography was

normal in all newborns. Electroencephalogram was pathological for all the newborns. The stroke was single in 11 cases (located in the middle or anterior cerebral artery) and multiple in 3 patients. Strokes were more commonly left sided (9 patients) whereas bilateral lesions occurred in 2 cases. Thrombophilia screening was performed in all cases. Factor V Leiden mutation was found in 2 newborns and MTHFR mutation in one. All patients received antiepileptic drugs from the first week of life. One patient received antithrombotic medication. The average duration of hospital stay was 7 days. Neurological deficits at discharge were documented only in 3 newborns without any seizure recurrence. Long-term outcome at an average age of 4 years revealed 2 epileptic patients with severe mental and physical disabilities, 5 patients with spastic hemiplegia, 3 with spastic tetraparesis and only one patient with normal neurological evaluation despite the recurrence of some seizures.

CONCLUSION

NAIS is the second commonest cause of neonatal seizures after hypoxic-ischaemic encephalopathy. The middle cerebral artery is most commonly involved and neuromotor outcome is best predicted by the extent of the lesion. The neuro-anatomical extent of the lesion is best determined by neuro-imaging with MRI and MRA/V. The treatment is essentially supportive and there is currently no evidence to support the use of anticoagulants. Cognitive and behavioral outcomes appear more variable and less readily predicted.

ABS 8

NEONATAL THERAPEUTIC HYPOTHERMIA IN LATVIA

S. Stanke, A. Jurasa, S. Laktina

Neonatal Clinic, Children Clinical University Hospital, Riga, Latvia

BACKGROUND AND AIMS

Usage of neonatal therapeutic hypothermia in Latvia was started in 2012. Three hospitals in Latvia perform therapeutic hypothermia: selective head cooling ("Cool Cap") at the Riga Maternity hospital and whole-body hypothermia ("Thecoterm") at the University Children's Hospital and at the P. Stradina Clinical University Hospital. The authors report on their experience and results with the use of therapeutic hypothermia from August 2012 to December 2017.

METHODS

A total of 150 newborns with moderate and severe hypoxic-ischemic encephalopathy received therapeutic hypothermia in all three hospitals. The authors analysed:

1. Start-up time of active therapeutic cooling;
2. Causes of perinatal events;
3. Mortality rates;
4. Results of cerebral magnetic resonance imaging (MRI);
5. Neurodevelopmental status by the Hammer-smith Infant Neurological examination scale and Munich Functional Developmental Diagnostics scale at the age of 2 years.

RESULTS

1. Mean start-up time was 3.5 hours, in line with the internationally accepted guidelines.
2. Known cause of perinatal event – 60% (90/150).
3. The mortality rate, at 14% (21/150), is comparable with other European studies.
4. MRI data in surviving patients (129/150):
 - Normal MRI findings – 72 (56%);
 - Minimal changes in basal ganglia-thalamus region – 8 (6.2%);
 - Moderate changes in basal ganglia-thalamus region – 5 (3.9%);
 - Severe injury in basal ganglia-thalamus, internal capsule and cerebral cortex – 15 (11.6%);
 - Watershed predominant pattern – 15 (11.6%);
 - Various: including white matter, corpus callosum, cerebellum hypoxic ischemic damage – 14 (10.8%).
5. 68 out of 128 survivors (53%) underwent neurodevelopmental examination at the age of 2 years. One death occurred at three months.
 - 43 (63%) have normal neurological development;
 - 1 (1.5%) hemiparesis;
 - 4 (5.8%) mild cognitive, speech, motor development retardation;
 - 9 (13.2%) spastic tetraparesis and seizures;
 - 3 (4.4%) moderate cognitive, speech retardation;
 - 8 (11.7%) speech retardation;
 - None had hearing impairment.

CONCLUSIONS

Patients after therapeutic hypothermia need sustained multidisciplinary follow up, and especially careful monitoring of speech and cognitive development.

ABS 9

OUTCOME OF PYRIDOXINE-DEPENDENT EPILEPSY: A 14-CASE STUDY

A. Ben Thabet¹, F. Charfi¹, A. Ben Hamad¹, M. Charfi¹, Ch. Regaieg¹, N. Hamida¹, F. Kammoun², Ch. Triki², R. Regaieg¹, A. Bouraoui¹, A. Gargouri¹

¹Department of Neonatology Hedi Chaker University Hospital, Sfax, Tunisia

²Department of Neuropediatrics Hedi Chaker University Hospital, Sfax, Tunisia

INTRODUCTION

Pyridoxine-dependent seizure is a rare form of drug-resistant epileptic encephalopathy. The treatment consists in the administration of large daily supplements of pyridoxine (vitamin B6). If left untreated, infants with this condition can develop severe encephalopathy.

METHODS

This is a retrospective study carried out during a period of 12 years (from 1 January 2004 to 31 December 2015) including 14 newborns with pyridoxine-dependent seizures. They were admitted to the neonatology department of the Hedi Chaker university hospital in Sfax, Tunisia. These patients had regular clinical follow-up by a neonatologist and a neuropediatrician. The aim of this study was to assess the long-term outcome of these infants.

RESULTS

There were 13 boys and 1 girl. Parental consanguinity was found in 12 cases. The seizure occurred before the 15th hour of life in all patients. A brain MRI showed imaging abnormalities in 9 cases. Only 2 infants had primary response to classic anti-epileptic drugs (until day 4 and day 8 of life). All seizures ceased immediately after pyridoxine administration. A Tunisian characteristic mutation responsible for this condition was identified in all patients. It was a missense mutation: c.1364T>C, (p.Leu 455Pro) of ALDH7A1 gene. The long-term outcome (age between 2 and 12 years) showed controlled seizures with daily pyridoxine monotherapy in pharmacologic doses for 13 patients except for one patient who needed the association of another antiepileptic drug (valproic acid). This patient had hypoxic encephalopathy in addition to pyridoxine dependence. Ten patients received physical therapy because of tone abnormalities and 8 had persistent fine motor deficiencies. Neuropsychological assessment was performed in 9 cases and showed severe intellectual disabilities

in 2 infants. Learning difficulties were present in the majority of the patients: there were memory, concentration and language difficulties. Speech therapy and psychotherapy improved their school grades. Five patients had satisfactory results.

CONCLUSION

Pyridoxine-dependent epilepsy is a rare neurometabolic disease. The use of pyridoxine is recommended in all seizures persisting after classic anti-epileptic administration. Despite treatment, children may have intellectual deficits or developmental delays, especially if abnormalities in brain development are associated.

ABS 10

PERINATAL BRAIN INJURY AND DYNAMICS OF CLINICAL SYMPTOMATOLOGY

D. Šumanović-Glamuzina, M. Karlović, M. Jerković-Raguž, A. Mustapić

Clinic for Child Diseases, University Hospital Mostar, Mostar, Bosnia and Herzegovina

INTRODUCTION

Perinatal brain injury is still a very serious cause of perinatal morbidity and mortality. Hemorrhagic (H) or hypoxic-ischemic (HI) brain damage mostly depends on gestational age. Duration of acute neurological symptomatology could be a good predictor of the seriousness of neurophysiological disabilities. We analyzed symptomatology (H or HI) and its duration through the first few weeks of illness and subsequent neurological outcome (at 12 months of age).

METHODS

In a retrospective study at the Neonatology Department of University Hospital Mostar, we recorded infants with the diagnosis of perinatal hypoxia and brain symptomatology over the period 2013-2015. We analyzed acute clinical symptomatology and its dynamics due to maturity, perinatal history and severity of the manifested encephalopathy according to the Sarnat/Sarnat method.

RESULTS

The prevalence of PBI was 25.8/1,000 per births. Intra-cranial hemorrhage was higher in the group of premature infants. Hypoxic encephalopathy was higher in the group of mature infants with brain edema pathology. Mortality was 17.9%. The most common clinical manifestation in the first eight days

was moderate encephalopathy. Encephalopathy with duration of more than 8 days resulted in significant neurological disorder at 12 months of age.

CONCLUSION

Our prevalence of PBI is higher than in other parts of Europe. Clinical symptomatology depends on gestational age and severity of perinatal history. Most of the infants with encephalopathy lasting less than 8 days were cured.

ABS 11

THE ROLE OF RED BLOOD CELL TRANSFUSIONS IN THE PREVENTION OF SEVERE INTRA/PERIVENTRICULAR HEMORRHAGE

M. Boia¹, A. Manea¹, D. Cioboata², O. Costescu², F. Doandes², A. Hudisteanu²

¹Neonatology Department, "Victor Babes" University of Medicine and Pharmacy, Timisoara, Romania

²Neonatology Department, "Louis Turcanu" Children's Emergency Hospital, Timisoara, Romania

INTRODUCTION

Intra/periventricular hemorrhage, despite medical progress over the past decade, remains a major cause of neonatal morbidity and mortality in premature infants. The prevalence of severe forms of the disease has increased slightly due to the recovery of newborns at lower gestational ages. The germinal matrix, the starting point of this condition, is the more vulnerable the lower the gestational age. Red blood cell transfusions during the early neonatal period may contribute to an increase in the incidence of severe forms of hemorrhage.

OBJECTIVES

The authors propose an analysis of the risk factors associated with severe intra/periventricular hemorrhage and especially of the involvement of red blood cell transfusions in the onset and worsening of the condition.

MATERIALS AND METHODS

The study was conducted over a 2-year period, including 48 preterm infants with gestational age < 32 weeks and birth weight < 1,500 g hospitalized in the Neonatal Intensive Care Unit, who received red blood cell transfusions. In the control group, 52 patients were included. The exclusion criteria were: cerebral malformations, coagulopathies and meningitis.

RESULTS

Newborns requiring red blood cell transfusions in the first week of life developed intra/periventricular

hemorrhage (23%) with ventriculomegaly (18%) and hydrocephalus (8%), especially ELBW (700-900 g). The most commonly associated pathologies were: maternal-fetal infection (23%), intra/periventricular leukomalacia (16%), respiratory distress syndrome (74%) and pneumothorax (4%). The patients included in the study did not benefit from milking of the umbilical cord at birth.

CONCLUSIONS

Red blood cell transfusions in infants with low gestational age contribute to the onset of hemorrhage and also to worsening of the severe forms of the disease. Milking of the umbilical cord can contribute to decreasing the incidence of red blood cell transfusions, reducing severe forms hemorrhage and thus decreasing neurological sequelae.

ABS 12

PHENOTYPIC VARIABILITY OF CONGENITAL MYOTONIC DYSTROPHY: REPORT OF TWO CASES

A. Vontzalidis¹, K. Karachristou¹, E. Yatrakou¹, K. Kosma², K. Kekou², G.K. Papadimas³, K. Katexi¹, A. Moutafi¹, V. Galiaki¹

¹First Neonatal Intensive Care Unit, Aghia Sofia Children's Hospital, Athens, Greece

²Department of Medical Genetics, University of Athens, School of Medicine, Aghia Sophia Children's Hospital, Athens, Greece

³First Department of Neurology, University of Athens, Medical School, Aeginition Hospital, Athens, Greece

INTRODUCTION

Myotonic dystrophy (DM) is an autosomal dominant multisystem disorder of variable expression and a large range in age of onset and rate of progression. Two loci for the disease have been found and are characterized as DM1 and DM2. The genetic basis for DM1 is an expansion of CTG repeats in the myotonic dystrophy protein kinase (DMPK) gene on chromosome 19q13.3. Congenital myotonic dystrophy is the earliest presenting form of DM1. Clinical features of the disease include hypotonia, diffuse weakness, hyporeflexia or areflexia, facial diplegia, bilateral fixed ankle contractures, cataracts and cardiac conduction abnormalities. We report the cases of two neonates with congenital myotonic dystrophy, with variable clinical course of the disease.

CASE REPORTS

The first patient was a male baby born to a 41-year-old third gravida mother at 34^{3/7} weeks gestation by

normal vaginal delivery. The mother's pregnancy was complicated by polyhydramnios. At birth, the infant had Apgar scores of 1 and 5 at 1 and 5 minutes, respectively and required resuscitation. Mechanical ventilation was initiated in the delivery room due to respiratory failure. Generalized weakness and hypotonia were profound, with facial diplegia, absent deep tendon reflexes, joint contractures and cataracts. Complete blood count, acid base levels and metabolic profile were normal. Brain MRI revealed white matter abnormalities in the periventricular regions of the cerebrum and findings consistent with hypoxic-ischemic encephalopathy. Muscle biopsy histological and histochemical features were suggestive of DM1 with a marked increase in internally located nuclei, fiber size variability and type 1 fiber atrophy. DMPK gene analysis confirmed the diagnosis of DM1 (expansion of CTG repeats > 150). The newborn's clinical condition gradually deteriorated until the 20th day of life, when he died while still under mechanical support. The second patient was a male baby born to a primigravida mother at a gestational age of 31^{5/7} weeks by cesarean section. At birth, the infant also required resuscitation, having Apgar scores of 2 and 4 at 1 and 5 minutes, respectively. The baby was admitted to our hospital at 35 weeks' post-conception age for further evaluation. Similar white matter abnormalities were present on brain MRI. The diagnosis of DM1 was also confirmed by genetic testing. The infant had a better clinical course as hypotonia and weakness gradually improved. He was extubated after two months and discharged from the hospital on full enteral feeding at a corrected age of three months. Follow-up evaluation at corrected age of six months revealed global developmental delay. Hypotonia and weakness were evident.

CONCLUSIONS

Congenital myotonic dystrophy is a severe disease characterized by phenotypic variability. Early diagnosis is important for determining therapy, prognosis and genetic counseling of the family.

ABS 13

A CASE OF SEVERE NEUROMORBIDITY OF SURVIVOR TWIN AFTER INTRAUTERINE DEATH OF A CO-TWIN

M. Starcevic, N. Sindicic Dessardo, M. Ilijic Krpan

Division of Neonatology, Department of Obstetrics and Gynecology, Clinical Hospital Center Zagreb, Zagreb, Croatia

INTRODUCTION

Monochorionic twins have higher rates of growth discordance, fetal loss, extreme prematurity and neonatal morbidity. Fetal death of a co-twin increases the risk of cerebral injury and lifelong neurological disability in the surviving twin.

CASE REPORT

Case presentation of neurological consequences of intrauterine death of a co-twin on the surviving twin. This was the first, twin, naturally conceived pregnancy of a healthy 31-year-old mother. An isolated discordant growth of monochorionic male twins was observed at 24 weeks of gestation. No other pathological ultrasound findings were recorded, and the course of pregnancy was otherwise normal. Growth discordance was accompanied by discordant amniotic fluid volumes, with a decreased amount in the smaller twin at 31 weeks of gestation, but the suspicion of twin-to-twin transfusion syndrome was not confirmed. Pregnancy was terminated at 32 weeks of gestation by an emergency cesarean section because of sonographically verified intrauterine death of the growth-restricted twin and suspected placental abruption. The survivor twin was born vital (Apgar score 10.10), birth weight was 2,010 g, no clinical or laboratory criteria for birth asphyxia were detected (arterial blood cord pH 7.25). During his short (one week) hospitalisation in the Neonatal intensive care unit, erythrocyte transfusion was indicated because of lower blood count values (E $3.18 \times 10^9/L$, Hb 120 g/L), otherwise the clinical course was uneventful. However, routine brain ultrasound examinations in the first days of life showed severe hypoxic-ischaemic brain injury with wide areas of complete parenchymal loss and disrupted brain morphology. The extension of brain damage was confirmed by magnetic resonance imaging. The neonate was discharged home at 38 days of life, continuing the early intervention program started during his hospital stay.

CONCLUSION

In the case of a surviving twin after intrauterine death of a co-twin, severe neurological consequences and poor long-term neurological outcome can be expected. Monochorionicity and selective growth restriction were confirmed as the most important risk factors for fetal loss and neurological damage in the case presented.

ABS 14

COMPLICATIONS OF EXTERNAL VENTRICULAR DRAINAGE AND VENTRICULO-PERITONEAL

SHUNT INSERTION IN POST-HEMORRHAGIC HYDROCEPHALUS

O. Costescu^{1,2}, A. Manea¹, F. Doandes^{1,2}, D. Cioboata², N. Lungu², M. Boia¹

¹Neonatology Department, "Victor Babes" University of Medicine and Pharmacy, Timisoara, Romania

²Premature-Neonatology Department, "Louis Turcanu" Children's Emergency Hospital, Timisoara, Romania

INTRODUCTION

Intraventricular haemorrhage is a cause of neonatal morbidity and mortality and is strongly associated with adverse neurological outcomes. Post-hemorrhagic hydrocephalus is a complication of intraventricular hemorrhage in neonates, especially preterm. Optimal timing of external ventricular drainage and ventriculo-peritoneal shunt insertion to reduce long-term neurological sequelae remains a controversial topic. The aim of the study was to analyze the incidence of intraventricular hemorrhage in ELBW and VLBW newborns and the complications of external drainage and ventriculo-peritoneal shunt.

MATERIALS AND METHODS

Retrospective study over a period of 2 years (2016-2018) of a group of premature newborns with gestational age < 32 weeks and birth weight of < 1,500 grams, admitted to the Neonatology-Premature Clinic of the "Louis Turcanu" Hospital Timisoara and diagnosed with intraventricular post-hemorrhage hydrocephalus that required neurosurgery. The evolution of hydrocephalus as well as complications related to external drainage or ventriculo-peritoneal shunt were monitored by transfontanelle ultrasound, CT or magnetic resonance imaging.

RESULTS

14 premature infants were included in the study. Of these, 9 cases were VLBW (64.29%) and 5 were ELBW (35.71%). An increased incidence of severe (grade 3-4) intraventricular hemorrhage was observed in VLBW newborns compared with ELBW newborns. Due to the rapid evolution of hydrocephalus with the increase of the cranial perimeter and intracranial pressures, neurosurgical intervention was decided between the 28th and the 75th day of life. In 10 cases surgery was necessary for insertion of external drainage with its later internalization, and in the remaining cases the procedure was temporarily suspended. In the study group 3 cases presented shunt infections, and 5

cases showed mechanical defects of the shunt; in both cases (57.14%) neurosurgical re-intervention was necessary.

CONCLUSIONS

Hydrocephalus is a complication of a neurological injury, particularly affecting preterm newborns, especially those with very low or extremely low birth weight. Neurological development is not affected by the complications given by shunt, but by the degree of prematurity and the onset and rapid progression of hydrocephalus.

ABS 15

FETAL ANEUPLOIDY: ETHICAL ISSUES AND MANAGEMENT OPTIONS IN ONE OF THE FRATERNAL TWINS

M. Anciu¹, D.C. Rac¹, M.C. Cucerea^{1,3}, C. Bănescu^{2,3}

¹Department of Neonatology, Emergency Clinical County Hospital of Țirgu Mureș, Țirgu Mureș, Romania

²Department of Genetics, Emergency Clinical County Hospital of Țirgu Mureș, Țirgu Mureș, Romania

³University of Medicine and Pharmacy Țirgu Mureș, Țirgu Mureș, Romania

INTRODUCTION

Trisomy 18, also called Edwards syndrome, is a chromosomal condition associated with abnormalities in many parts of the body. Due to the presence of several life-threatening medical problems, many individuals with trisomy 18 die before birth or within their first month of life. Five to 10 percent of children with this condition live past their first year, and these children often have severe intellectual disability.

MATERIAL AND METHODS

This investigation presents the case of a neonate from an unplanned out-of-hospital birth in February 2018, assessed at the local hospital and later sent to the Emergency Clinical County of Țirgu Mureș Maternity.

RESULTS AND DISCUSSION

The neonate was a late preterm, born to a 27-year-old female at 35 weeks gestation and weighing 1,100 grams. The mother's twin pregnancy was unmonitored, with a personal history of gravida VI, para V. Spontaneous labor was followed by uncomplicated natural delivery in cranial presentation of twin A, a girl with a normal weight and then of twin B, a male infant with postpartum adaptation with respiratory distress

and without effective spontaneous breathing. After transfer to the Neonatal Intensive Care Unit (NICU), clinical examination showed evidence of polymorphic syndrome in accordance with phenotypic appearance: microcephaly accompanied by a prominent occiput, low-set, malformed ears, cleft lip and palate, upturned ocular hypertelorism, malformed hands and clubfoot and undescended testicles; genetic counseling was thus provided. Quantitative fluorescence polymerase chain reaction (QF-PCR) of the peripheral blood cells using the kit Elucigene QST*Rplusv2 from GeneProbe detected the presence of an aneuploidy that is of interest to chromosome 18, that is Trisomy 18. Cytogenetic analysis was performed and confirmed the aneuploidy, a homogeneous trisomy 18, 47,XY,+18. Despite appropriate therapeutic management by adapted mechanical ventilation every day, due to the association of severe respiratory failure and cardiovascular pathology, such as congenital heart defects and pulmonary hypertension, the child died at the age of 78 days. Comparison of these twin siblings dramatically demonstrated the devastating effect of autosomal trisomy on intrauterine growth. Despite targeted management, newborns with trisomy 18 have poor prognosis. Moreover, the development of multidisciplinary principles raises arguments about the option for a non-interventionist approach with accompanying comfort care and with respect for the family's choice.

CONCLUSION

This case illustrates the multiple decision points and ethical challenges of an infant born with a fatal diagnosis. The complexity and the severity of the clinical presentation at birth and the mortality rate make the management of babies with Edwards Syndrome particularly controversial and unique among other congenital syndromes.

ABS 16

VESICULAR ERUPTION IN NEONATES: DIAGNOSTIC CHALLENGES

A. Hosu^{1,2}, S. Andreica^{1,3}, I. Ioana¹, M. Matyas^{1,3}, M. Hasmasanu^{1,3}, D. Rusu¹, S. Cotutiu¹, D. Morar-Huniadi¹, A. Baican^{1,3}, G. Zaharie^{1,3}

¹Neonatology Department, Cluj County Clinical Emergency Hospital, Cluj-Napoca, Cluj, Romania

²Emergency Children Hospital, Cluj-Napoca, Cluj, Romania

³University of Medicine and Pharmacy "Iuliu Hatieganu", Cluj-Napoca, Cluj, Romania

INTRODUCTION

Vesicular eruptions represent a frequent diagnostic challenge in neonates. Even though the lesions are mostly found in benign and infectious diseases, they require differential diagnosis with respect to autoimmune or genetic disorders. We present the case of a term neonate with a polymorphic eruption from the first day of life, associated with neurological impairment. The particularity of the case consists in the difficulty of identifying the etiology. Eventually, a genetic disease was diagnosed – incontinentia pigmenti.

CASE REPORT

A 3-day-old term neonate (39 WG), born by caesarean section, was transferred from a level I hospital, presenting a systemic polymorphic eruption and partial seizures in the legs. Skin lesions were noticed to be of a linear pattern, mostly on the limbs, and they developed increasingly in the first week of life, despite antiviral and antibiotic treatment. Laboratory tests revealed no abnormalities in whole blood count, C-reactive protein, serum electrolytes and glucose, although the eosinophil count was

high. Viral infections (TORCH, Herpes Simplex, Varicella) and *Treponema* were ruled out. MRI showed extended lesions in the white matter of the left hemisphere. No ocular anomalies were found. Histopathology of a skin biopsy showed dermatitis with intraepidermal and dermal eosinophilia in the presence of pustulae with neutrophilia and eosinophilia and necrotic keratinocytes. Based on the finding, the diagnosis of incontinentia pigmenti was made.

CONCLUSION

Incontinentia pigmenti is a rare x-linked genetic disease, with progressive cutaneous manifestations as its main clinical feature and classically it evolves through 4 stages. However, there are no standardized diagnostic criteria for incontinentia pigmenti as yet. The diagnosis relies mostly on the characteristic skin lesions and other clinical findings. Skin biopsy and molecular genetic testing of the NEMO gene may help to confirm the disease. When faced with a neonate with a polymorphic skin eruption, differential diagnosis with genetic disorders should not be discounted.