

Pediatric ileal intussusception due to Peutz Jeghers syndrome: a rare case report

Alessandro Pane, Luigi Mascia

Division of Pediatric Surgery, AO Brotzu, Cagliari, Italy

Abstract

We report an unusual case of ileal intussusception in a 7-year-old girl affected by Peutz Jeghers syndrome, characterized by a very misleading clinical presentation, resembling chronic constipation. Correct diagnosis was guided through appropriate knowledge of inherited condition and cautious ultrasound monitoring. Confirmation was achieved by a timely surgical intervention and subsequent pathologic examination.

Keywords

Peutz Jeghers syndrome, familial polyposis, intussusception, small bowel occlusion, small bowel bleeding, pediatric surgery.

Corresponding author

Alessandro Pane, Division of Pediatric Surgery, AO Brotzu, Cagliari, Italy; email: alessandro.pane@gmail.com.

How to cite

Pane A, Mascia L. Pediatric ileal intussusception due to Peutz Jeghers syndrome: a rare case report. J Pediatr Neonat Individual Med. 2018;7(2):e070220. doi: 10.7363/070220.

Introduction

Peutz Jeghers syndrome (PJS) is a hereditary, autosomic dominant disease; it is characterized by hamartomatous polyposis (typically in the small bowel) and mucocutaneous pigmentation. Prevalence is variously estimated: it ranges from 1:8,300 to 1:280,000 according to single case series; the mostly probable prevalence is around 1:100,000 people [1]. PJS has very variable penetrance, varying from hyperpigmentation alone to whole signs, even within members of the same family. Hamartomatous polyps usually are characterized by abnormal tissue architecture, while not exhibiting clear neoplastic growth; on the other hand, larger hamartomas may contain adenomatous tissue, so

malignancy cannot be surely ruled out and has been previously described. Moreover, PJS-related genetic mutations are related to increased risk of gastrointestinal and extraintestinal neoplasm, although direct transformation of hamartomatous polyp is extremely rare. Intussusception is a frequent complication, up to 47% of cases in natural history [2], but diagnosis may be very insidious: usually small bowel intussusception is intermittent and hard to be imaged by ultrasound until it is firmly established.

Case report

We observed a 7-year-old girl, diagnosed with PJS 3 years before and regularly undergoing upper gastrointestinal follow-up (negative until this time), with a subacute, periumbilical abdominal pain in the last 2 weeks, associated with constipation and rare vomiting. She didn't have typical mucocutaneous lesions nor previously diagnosed polyps; PJS diagnosis was genetically achieved, because her mother was known to be PJS affected after intussusception in infancy. At the time of surgical evaluation, the girl was in good conditions, with satisfactory nutritional status; no sign of anemia or flogosis was evidenced in laboratory study. The mother reported that her daughter had progressive constipation in last months, thought to be related to poor fibre dietary intake. Severe worsening of abdominal pain in last 24 hours led to hospital admission. We performed abdominal US scan: initially we were unable to find any obstruction sign; we planned to repeat US every 24 hours. Suddenly, after 2 days, the girl presented acute wine-stained rectal bleeding, associated to intermittent acute pain. Urgent US re-evaluation finally evidenced typical intussusception sign (target US sign) in mesogastrium (**Fig. 1**). During emergency laparotomy, an ileal intussusception was found (**Fig. 2**); after reduction, longitudinal enterotomy showed presence of large sessile polyp (**Fig. 3**) as leading point. A 10-centimeter ileal resection and anastomosis were performed. Postoperative recovery was uneventful and quick.

Discussion

Isolated polyps in PJS are a rare condition, especially if associate with intussusception [3, 4]. Typical sites of occlusion are jejunum and distal colon [4]. As far as we know, this is the 5th case of pediatric ileal intussusception described in a PJS

patient [5]. It is unclear whether the solitary polyp is an autonomous entity of PJS, as specific markers (*LKB1-STK11*, a tumor suppressor gene seen in up to 70% patients in the syndrome) were not found in this lesions, although the pathologic characteristics are the same [6]. Whenever an isolate polyp is found, it is needed to rule out the diagnosis of PJS on the basis of the WHO criteria: (1) ≥ 3 hamartomatous polyps; (2) ≥ 1 hamartomatous polyps, if family history of PJS; (3) prominent mucocutaneous melanosis if family history of PJS; (4) prominent mucocutaneous melanosis and ≥ 1 hamartomatous polyp [7]. This can be helpful to drive further patient management; in case of confirmed PJS, the patient must be enrolled in a diligent monitoring program: upper and lower gastrointestinal endoscopy, bowel MRI, videocapsule enteroscopy [1]. Polyp resection is mandatory, by double balloon enteroscopy or surgery (laparoscopy/laparotomy), to avoid both malignancy and intussusception risk [8]. Double balloon enteroscopy appears to be safe, allowing an effective, early and non-invasive approach, but it is technical demanding and not available everywhere [9]. Surgical resection, although more invasive, is the only emergency option available to solve acute presentations as intussusception or acute bleeding; many authors report successful combination of both techniques to retrieve polyps [10, 11].

Patients with isolated polyps in PJS previously described were observed mostly in the 4th decade of life, whereas PJS patients present more often in

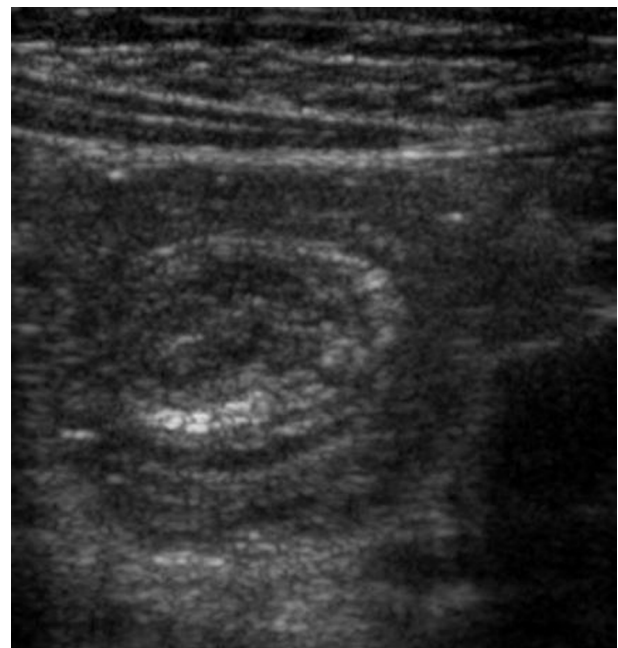

Figure 1. Urgent US re-evaluation finally evidenced typical intussusception sign (target US sign) in mesogastrium.

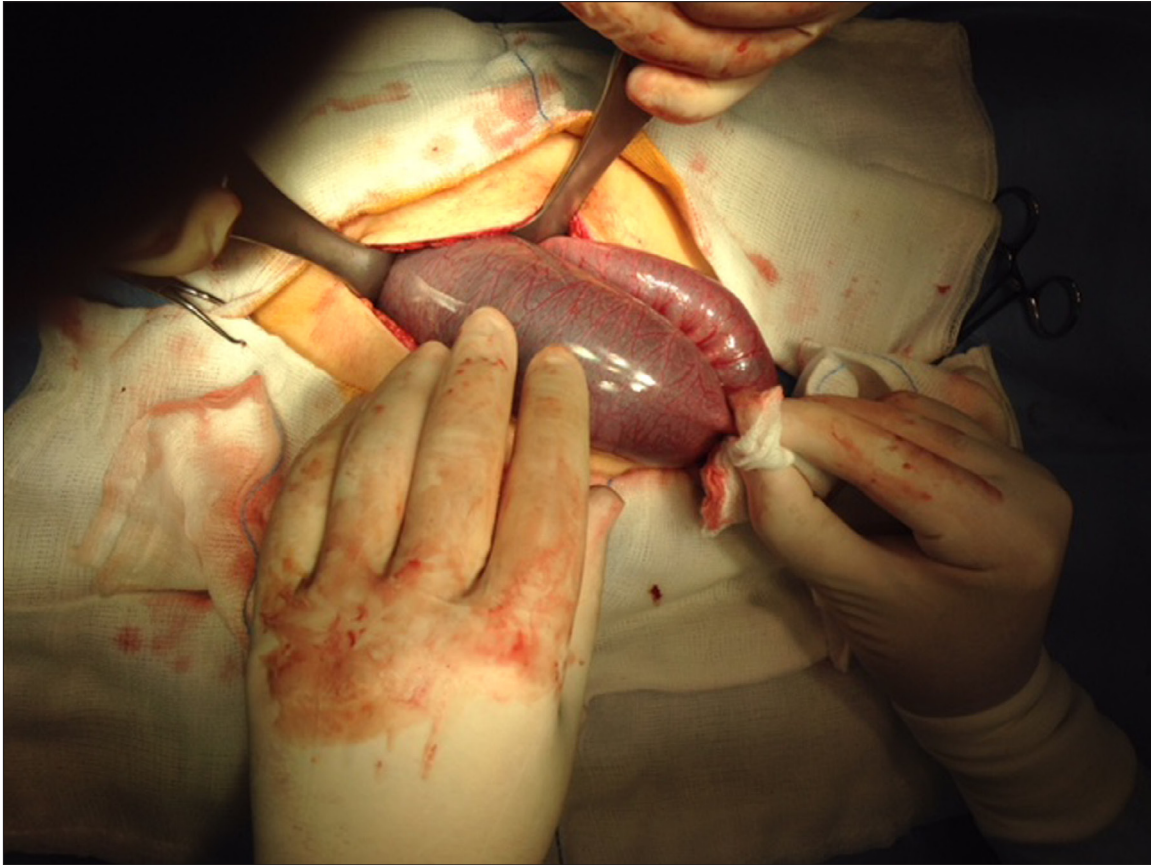


Figure 2. Emergency laparotomy: an ileal intussusception was found.

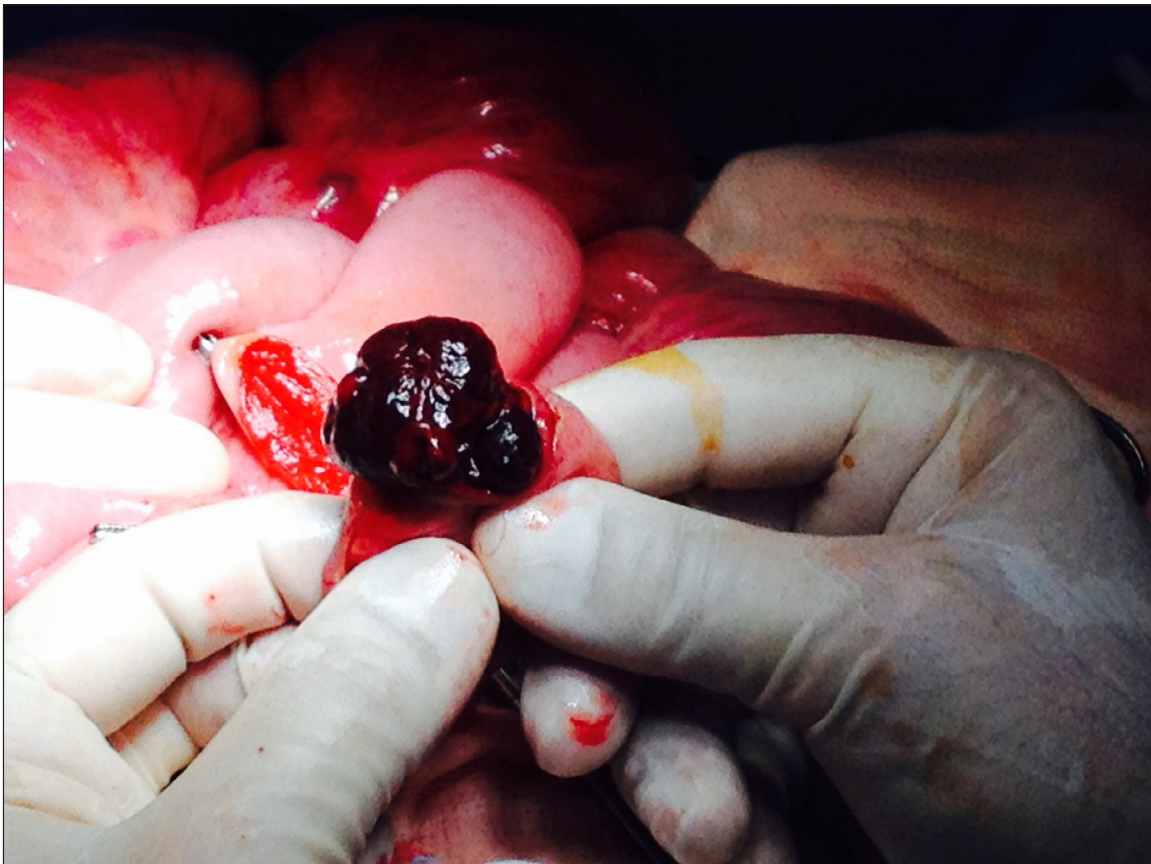


Figure 3. After reduction, longitudinal enterotomy showed presence of large sessile polyp as leading point.

the 2nd or 3rd decade of life [8]. Rarity of pediatric cases may lead to misdiagnosis, with an increased complication rate. We suggest to always rule out small bowel lesions in PJS patients, before they develop complication, by accurate imaging and follow-up. Acute presentation may be challenging, so US abdominal investigation alone may be not permit a timely intervention.

Declaration of interest

The Authors declare that there is no conflict of interest.

References

1. Kopacova M, Tacheci I, Rejchrt S, Bures J. Peutz-Jeghers syndrome: Diagnostic and therapeutic approach. *WJG*. 2009;15(43):5397-408.
2. Utsunomiya J, Gocho H, Miyanaga T, Hamaguchi E, Kashimure A. Peutz-Jeghers syndrome: its natural course and management. *Johns Hopkins Med J*. 1975;136:71-82.
3. Burkart AL, Sheridan T, Lewin M, Fenton H, Ali NJ, Montgomery E. Do sporadic Peutz-Jeghers polyps exist? Experience of a large teaching hospital. *Am J Surg Pathol*. 2007;31:1209-14.
4. Oncel M, Remzi FH, Church JM, Goldblum JR, Zutshi M, Fazio VW. Course and follow-up of solitary Peutz-Jeghers polyps: A case series. *Int J Colorectal Dis*. 2003;18:33-5.
5. Sekino Y, Inamori M, Hirai M, Suzuki K, Tsuzawa K, Akimoto K, Takahata A, Fujisawa N, Saito K, Tsunemi A, Tanaka M, Iida H, Sakamoto Y, Takahashi H, Koide T, Tokoro C, Abe Y, Nakajima A, Maeda S, Koyama S. Solitary Peutz-Jeghers type hamartomatous polyps in the duodenum are not always associated with a low risk of cancer: Two case reports. *J Med Case Rep*. 2011;5:240.
6. Kalavant AB, Menon P, Mitra S, Thapa BR, Narasimha Rao KL. Solitary Peutz-Jeghers Polyp of Jejunum: A Rare Cause of Childhood Intussusception. *J Indian Ass Ped Surg*. 2017;22(4):245-7.
7. Retrosi G, Nanni L, Vecchio FM, Manzoni C, Canali R, Busato G, Pintus C. Solitary Peutz-Jeghers Polyp in a Paediatric Patient. *Case Rep Gastroenter*. 2010;4(3):452-6.
8. Ter Borg PP, Westenend PP, Hesp FW, van der Straaten FF, van de Vrie WW, Honkoop PP. A solitary Peutz-Jeghers type polyp in the jejunum of a 19 year-old male. *Cases J*. 2008;1:68.
9. Zbuk KM, Eng C. Hamartomatous polyposis syndromes. *Nat Clin Pract Gastroenterol Hepatol*. 2007;4:492-502.
10. Serrano M, Mão-de-Ferro S, Pinho R, Marcos-Pinto R, Figueiredo P, Ferreira S, Claro I, Mascarenhas-Saraiva M, Dias-Pereira A. Double-balloon enteroscopy in the management of patients with Peutz-Jeghers syndrome: a retrospective cohort multicenter study. *Rev Esp Enferm Dig*. 2013;105(10):594-9.
11. Ross AS, Dye C, Prachand VN. Laparoscopic-assisted double-balloon enteroscopy for small-bowel polyp surveillance and treatment in patients with Peutz-Jeghers syndrome. *Gastrointest Endosc*. 2006;64(6):984-8.