

# Atypical pleomorphic adenoma with chronic sialoadenitis of the submandibular gland: a case report in a child

Andrea Satta<sup>1</sup>, Filippo Carta<sup>2</sup>, Carlo Ripoli<sup>3</sup>, Anna Maria Nurchi<sup>3</sup>, Roberto Puxeddu<sup>2</sup>, Gavino Faa<sup>1</sup>, Clara Gerosa<sup>1</sup>

<sup>1</sup>Division of Pathology, Department of Surgery Science, AOU Cagliari, University of Cagliari, Cagliari, Italy

<sup>2</sup>1<sup>st</sup> Pediatric Clinic, Microcitemic Hospital, AOB (Brotzu), University of Cagliari, Cagliari, Italy

<sup>3</sup>Division of Otorhinolaryngology, Department of Surgery Science, AOU Cagliari, University of Cagliari, Cagliari, Italy

## Abstract

A 12-year-old girl presented with an oval swelling in the left submandibular region. The tumor had gradually increased in size, during the last 9 months. Preoperative ultrasonography evidenced an hypoechoic oval mass, 14 x 12 mm in size. Submandibulectomy was performed. At macroscopy, the tumor was surrounded by a fibrous capsule, and appeared tan-white in color. At histology, an admixture of epithelial and mesenchymal cell components characterized the tumor. Epithelial cells showed large polymorphous atypical nuclei, with irregular nuclear membranes. The mesenchymal cells were embedded in a myxoid matrix, with focal areas of chondroid differentiation. The tumor showed pushing margins, focally extending into the fibrous capsule. Occasionally, some scattered foci of capsular pseudo-infiltration were detected. The proliferative index of tumor cells, detected by Ki67 immunostaining, reached levels around 10% in some tumor areas characterized by the highest frequency of atypical tumor cells. On these bases, a diagnosis of atypical pleomorphic adenoma was performed. A lymphocytic infiltrate, sometimes organized in lymphoid nodules, was observed in the surrounding submandibular gland. After 1 year of follow-up, the patient is in good health, in the absence of any recurrence. The case here reported confirms that tumors of the salivary gland occurring in children are characterized by a higher aggressive potential, here represented by the atypical tumor cells associated with the high proliferative index and with the pressure on the tumor capsule, and deserve the complete resection of the affected salivary gland, in order to prevent their potential malignant transformation. The association of the salivary gland tumor presenting in our patient with lymphocytic nodular sialoadenitis confirms previous reports of this peculiar association, and reinforces the hypothesis that the two conditions might share a common etiology.

## Keywords

Pleomorphic adenoma, children, submandibular gland, sialoadenitis, salivary gland tumor, parotid gland.

## Corresponding author

Clara Gerosa, Division of Pathology, Department of Surgery Science, AOU Cagliari, University of Cagliari, Cagliari, Italy; email: clarge@tiscali.it.

## How to cite

Satta A, Carta F, Ripoli C, Nurchi AM, Puxeddu R, Faa G, Gerosa C. Atypical pleomorphic adenoma with chronic sialoadenitis of the submandibular gland: a case report in a child. *J Pediatr Neonat Individual Med.* 2018;7(1):e070116. doi: 10.7363/070116.

## Introduction

Salivary gland tumors are rare in pediatric patients, less than 5% of them occurring in children younger than 16 years [1, 2]. Pleomorphic adenoma represents the most common salivary gland tumor of infancy, most frequently occurring in the major salivary glands [3, 4]. The parotid gland is the most commonly affected major salivary gland (56.7%), whereas the palate represents the most common site of minor salivary gland involvement [5-7]. Pleomorphic adenoma occurring in children has been reported to show different clinical and pathological characteristics, when compared with their adult counterparts. In particular, the association with chronic sialoadenitis has been reported in children, putatively representing a coincidental or a causal factor [8, 9]. The aim of this work was to describe a case of submandibular mass occurring in a child, showing peculiar pathological findings that underline the peculiarity of salivary gland tumor occurring in childhood.

## Case report

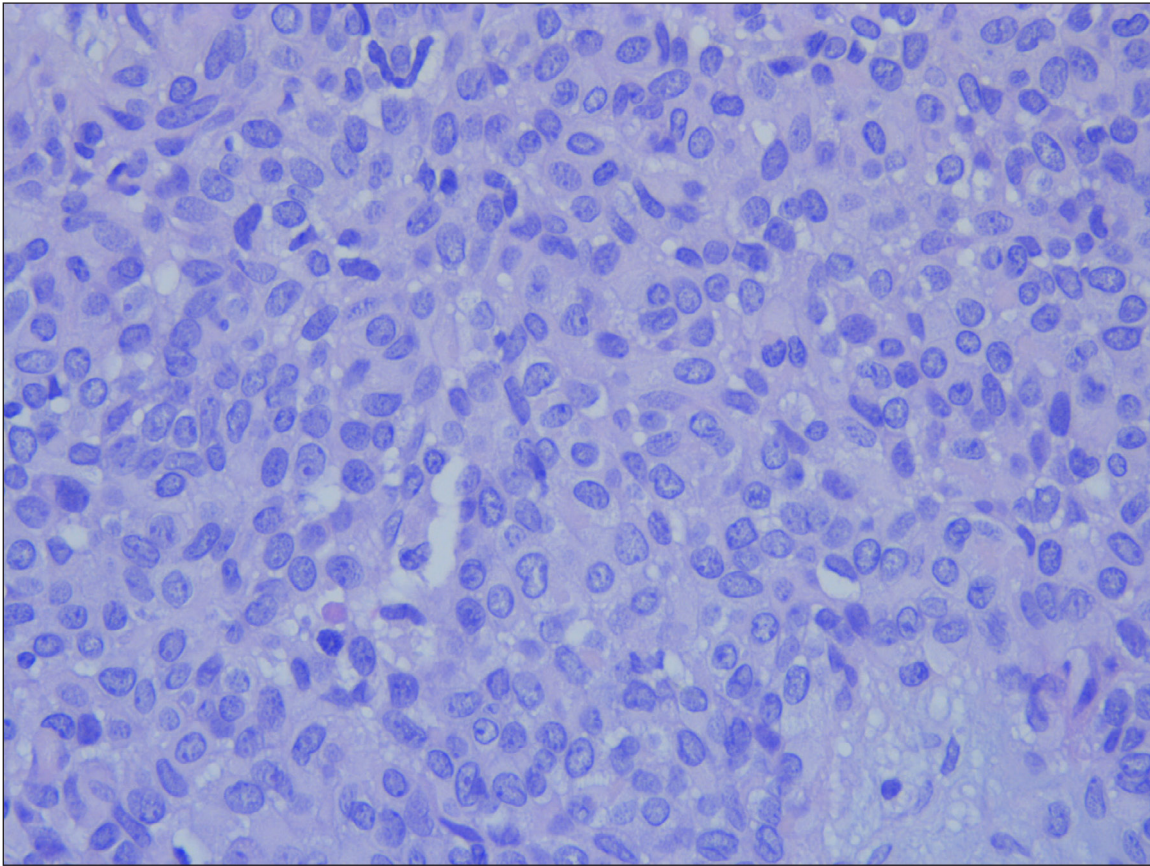
A 12-year-old girl presented with an oval painless swelling in the left submandibular region. The tumor had gradually increased in size, during the last 9 months. Magnetic resonance revealed an enlarged submandibular gland, due to an intraglandular neoplasia. Preoperative ultrasonography evidenced an hypoechoic oval mass, 14 x 12 mm in size. The patient underwent surgery, and submandibulectomy was performed. At macroscopy, the tumor was

surrounded by a fibrous capsule, and tan-white in color. At histology, the tumor was well surrounded by a thick fibrous capsule, and formed by an admixture of epithelial and mesenchymal cell components. Epithelial cells showed large polymorphous nuclei, with irregular nuclear membranes (**Fig. 1**). The mesenchymal cells were characterized by a spindle nucleus, with dense compact chromatin, and were embedded in a myxoid matrix, with focal areas of chondroid differentiation (**Fig. 2**). The tumor showed pushing margins, focally extending into the fibrous capsule (**Fig. 3**). Occasionally, some scattered foci of capsular pseudo-infiltration were detected, with tumor cells becoming in contact with the surrounding submandibular gland. No intratumoral necrosis, nor hemorrhages were found. Mitoses were rare, about 1 mitosis per 10 high power fields. The proliferative index of tumor cells, detected by Ki67 immunostaining, was uneven, reaching levels around 10% in some tumor areas characterized by the highest frequency of atypical tumor cells. A lymphocytic infiltrate, sometimes organized in lymphoid nodules, was observed in the surrounding submandibular gland (**Fig. 4**). After 1 year of follow-up, the patient is in good health, in the absence of any recurrence.

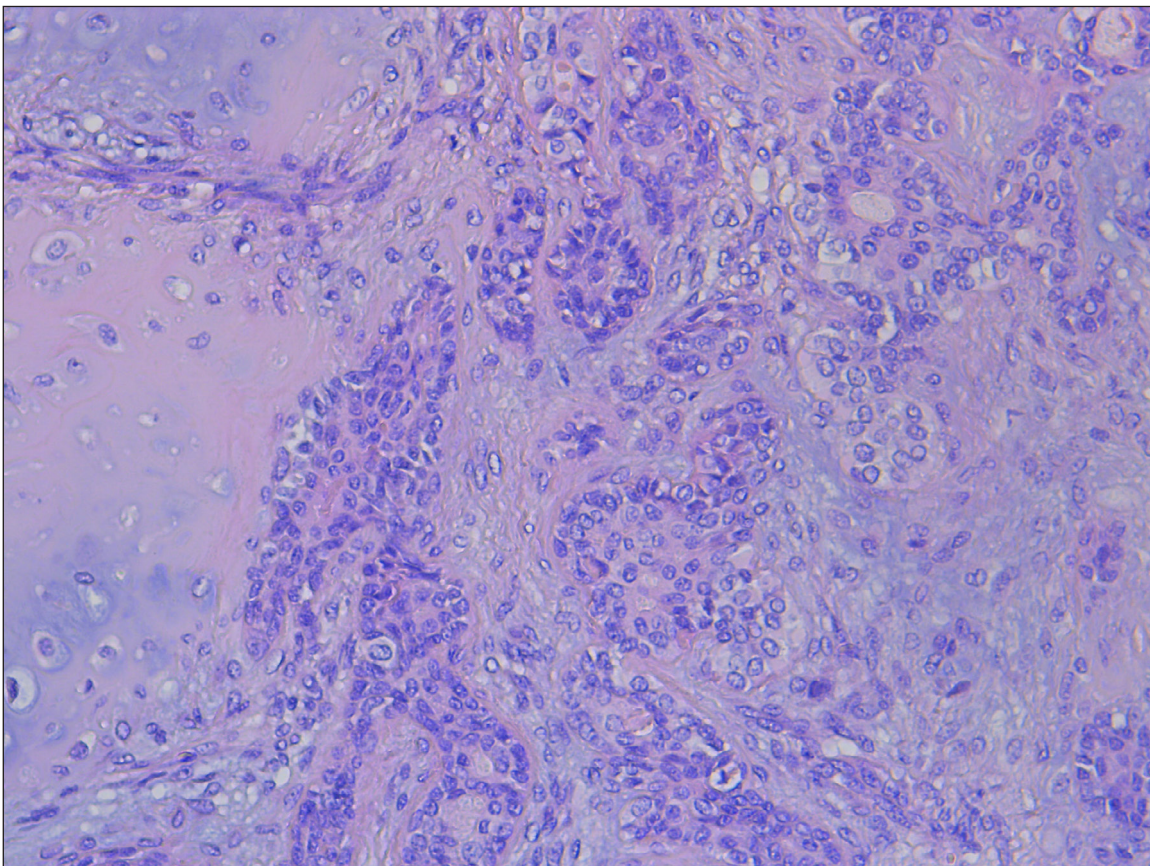
## Discussion

The case here reported regards a 12-year-old girl who presented with a mass in the submandibular gland that, at histology, was diagnosed as a pleomorphic adenoma. Some pathological findings detected in our case are uncommon and deserve some consideration. The histological pattern was not that typical of pleomorphic adenoma occurring in adults. In fact, tumor cells were characterized by atypical features, including hypercellularity, polydimensional nuclei, nuclear polymorphism and irregular nuclear membranes. All these histological data, taken together, are at the basis of the pathological diagnosis of atypical pleomorphic adenoma, a variant characterized by higher incidence of recurrence [10]. Our findings confirm that tumors of the salivary gland occurring in children are characterized by a higher aggressive potential and deserve the complete resection of the affected salivary gland, in order to prevent their potential malignant transformation [11, 12].

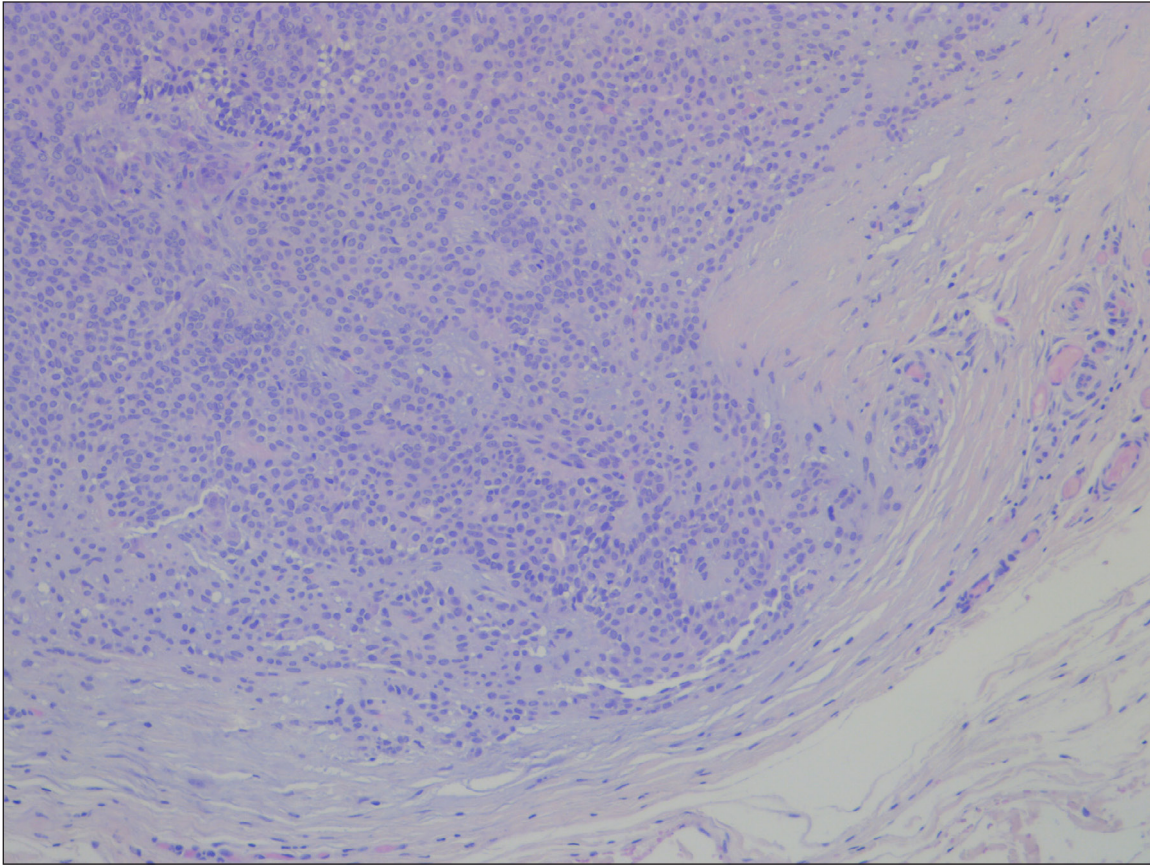
The potential aggressive behavior of the pleomorphic adenoma here described is confirmed by the presence of multiple foci of capsular pseudo-invasion, with buds of tumor cells lying in contact



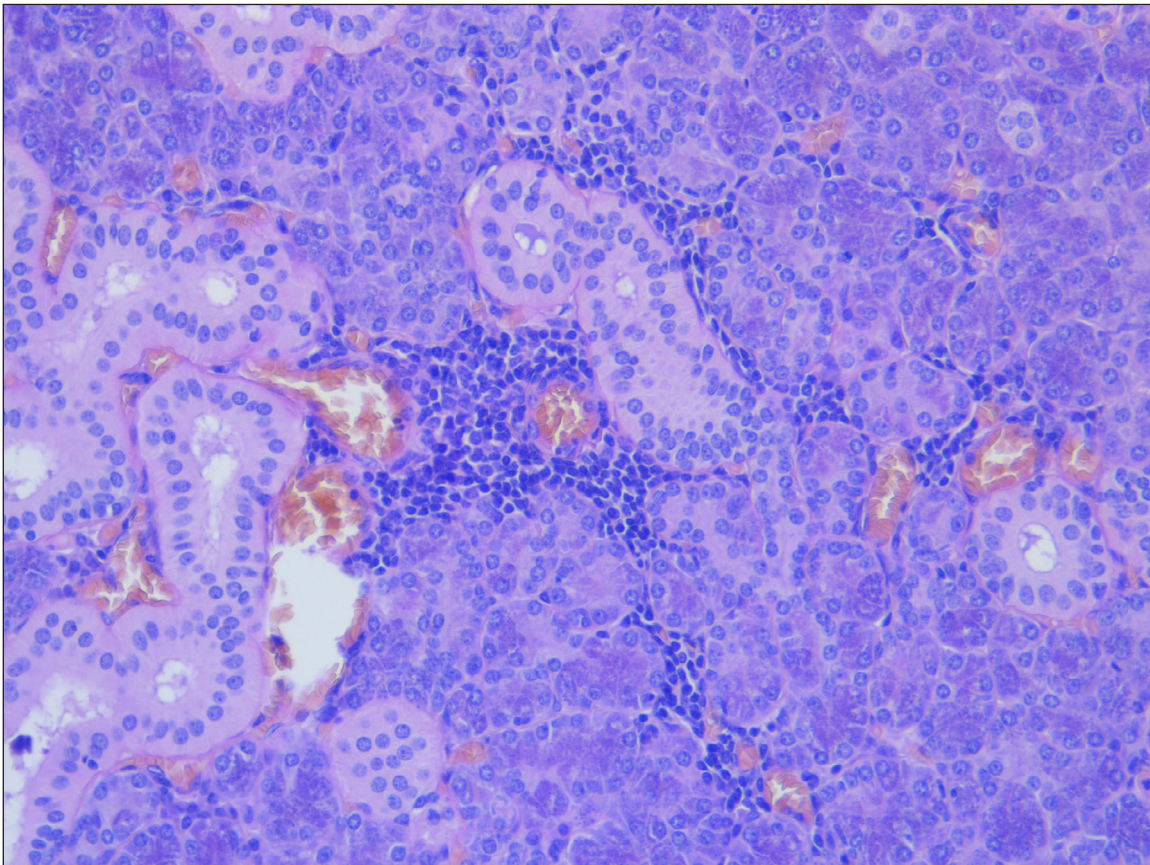
**Figure 1.** Epithelial cells showed slightly polidimensional nuclei and irregular nuclear membranes.



**Figure 2.** Mesenchymal-like component with spindle cells embedded in a myxoid and chondroid matrix.



**Figure 3.** The tumor pushing margins were characterized by cones of pressure inside the capsule.



**Figure 4.** Submandibular gland showed a lymphomonocytic interstitial infiltrate.

with the surrounding glandular parenchyma. Tumor islands occasionally appeared to be outside the capsule, but serial sectioning demonstrated that such satellites were, in fact, continuous within the main tumor mass and should not be regarded as real invasion [13]. Our findings clearly indicate that every tumor occurring in salivary glands in children should be serially sectioned and fully included, for a better evaluation of its potential aggressive behavior.

The finding of some scattered tumor areas with moderate mitotic activity and higher Ki67+ proliferative cellular index should be considered as another sign of potential aggressivity, given that pleomorphic adenomas with high proliferative activity have been reported to more likely develop to carcinoma [11].

Another feature that deserves some comment is represented by the association of the salivary gland tumor presenting in our patient with lymphocytic nodular sialoadenitis. This finding confirms a previous report of this peculiar association [8], and reinforces the hypothesis that the two conditions might share a common etiology.

In conclusion, the case here reported confirms previous data regarding the peculiarity of clinical and pathological features that characterize pleomorphic adenomas of the salivary glands occurring in childhood. Given the higher frequency in children of atypical histological and immunohistochemical features and the increased risk of an aggressive behavior, a careful examination of the capsular borders and immunostaining for Ki67 appear mandatory, in order to identify the tumors with a possible aggressive potential.

### Declaration of interest

The Authors declare that there is no conflict of interest.

### References

1. Ellies M, Laskawi R. Diseases of the salivary glands in infants and adolescents. *Head Face Med.* 2010;6:1.
2. Jagadishkumar K, Anilkumar MG, Chowdegowda H, Krishna Kumar HC, Maggad R. Pleomorphic adenoma of the cheek in a child: A case report. *Dent Res J (Isfahan).* 2014;11(4):522-4.
3. Guzzo M, Ferrari A, Marcon I, Collini P, Gandola L, Pizzi N, Casanova M, Mattavelli F, Scaramellini G. Salivary gland neoplasms in children: the experience of the Istituto Nazionale Tumori of Milan. *Pediatr Blood Cancer.* 2006;47:806-10.
4. Carlson ER, Ord RA. Benign Pediatric Salivary Gland Lesions. *Oral Maxillofacial Surg Clin N Am.* 2016;28:67-81.
5. Fu H, Wang J, Wang L, Zhang Z, He Y. Pleomorphic adenoma of the salivary glands in children and adolescents. *J Pediatr Surg.* 2012;47(4):715-9.
6. Dhanuthai K, Sappayatosok K, Kongin K. Pleomorphic adenoma of the palate in a child: A case report. *Med Oral Patol Oral Cir Bucal.* 2009;14:73-5.
7. Azma R, Fallahi M, Khoddami M, Shamsian BS, Alavi S. Congenital pleomorphic adenoma in a Submandibular Gland of a Newborn – A Case Report. *Iran J Otorhinolaryngol.* 2016;28(85):153-7.
8. Ratan SK, Bhardwaj M, Gambhir A, Sen A. Chronic sialadenitis with pleomorphic adenoma of the parotid: coincidental or causal? *Pediatr Surg Int.* 2002;18:60-1.
9. Kuşcu O, Kayahan B, Önay Ö, Günaydın RÖ, Akyol MU. Parotidectomy outcomes, diagnosis and complications on pediatric patients; twelve years of experiences in a tertiary care center. *Turk J Pediatr.* 2016;58(2):132-5.
10. Molina EJ, Mayer K, Khurana J, Grewal H. Pleomorphic adenoma of the submandibular gland. *J Pediatr Surg.* 2008;43:1224-6.
11. Auclair PL, Ellis GL. Atypical features in salivary gland mixed tumors: their relationship to malignant transformation. *Mod Pathol.* 1996;9:652-7.
12. Bentz BG, Hughes CA, Lüdemann JP, Maddalozzo J. Masses of the salivary gland region in children. *Arch Otolaryngol Head Neck Surg.* 2000;126:1435-9.
13. Fletcher CDM. *Diagnostic histopathology of tumors – 4<sup>th</sup> Edition.* Philadelphia, PA: Elsevier Saunders, 2013.