

# Impact of mydriatic eye drops on neonatal cerebral blood flow

Atef Alshafei<sup>1</sup>, Mahmoud Ahmed<sup>1</sup>, Shymaa Farouk<sup>1</sup>, Ahmed Gouda<sup>1</sup>, Anwar Khan<sup>1</sup>, Rashid Mustafa<sup>2</sup>

<sup>1</sup>Neonatology Section, Pediatric Department, Dubai Hospital, Dubai, UAE

<sup>2</sup>Radiology Department, Dubai Hospital, Dubai, UAE

## Abstract

Retinopathy of prematurity (ROP) screening is a common routine procedure carried out on preterm infants in neonatal intensive care units (NICUs). Mydriatic eye drops containing phenylephrine hydrochloride 2.5% (a sympathomimetic agent) and tropicamide 0.5% (a cycloplegic medication) are readily absorbed from the conjunctiva and produce systemic responses in various organs. To our knowledge, no studies have investigated the direct effects of these medications on cerebral blood flow velocities (CBFVs) in preterm infants.

To evaluate the systemic effects of locally instilled mydriatic eye drops (phenylephrine hydrochloride 2.5% and tropicamide 0.5%) used for ROP screening, on cerebral blood flow velocity in preterm infants, a prospective observational study was conducted among preterm infants with gestational age (GA) < 31 weeks admitted to the NICU at Dubai Hospital between February 20, 2017 and June 20, 2017.

The infants (at a post-menstrual age of 31-34 weeks) underwent duplex ultrasound evaluation of CBFV before and after mydriatic eye drops administration.

Pulsed-wave Doppler ultrasound studies were performed 1 h before and 1 h after eye mydriasis. We measured peak systolic velocity (PSV) and end diastolic velocity (EDV) for both the anterior cerebral artery (ACA) and middle cerebral artery (MCA) and calculated the resistive index (RI), defined as  $PSV - EDV/PSV$ . Mean arterial blood pressure (MAP), heart rate, oxygen saturation and pain score were assessed before and 1 h after ROP examination.

A paired t-test and McNemar's test were used to assess the statistical significance of the difference between pairs of means and the qualitative variables measured twice for the same study group.

Among the 42 eligible preterm infants, the mean (SD) GA was 27 (2.68) weeks (range, 24-31 weeks). The mean (SD) RI of ACA before and 1 h after eye drops administration was 0.84 (0.06) and 0.83 (0.07) respectively ( $p = 0.453$ ). The mean (SD) RIs of MCA before and then 1 h after mydriasis were 0.83 (0.05) and 0.83 (0.09), respectively ( $p = 0.559$ ).

Phenylephrine hydrochloride 2.5% and tropicamide 0.5% eye drops for neonatal ROP screening were not associated with significant changes in CBFVs. There was no effect on pain score or hemodynamic stability in the preterm infants.

### Keywords

Mydriatics, neonates, cerebral velocity, preterm infants, Doppler.

### Corresponding author

Atef Alshafei, MRCPCH, Neonatology Section, Pediatric Department, Dubai Hospital, Dubai, UAE, PO box: 7272; telephone number: +9771561924270; email: ahalshafei@dha.gov.ae.

### How to cite

Alshafei A, Ahmed M, Farouk S, Gouda A, Khan A, Mustafa R. Impact of mydriatic eye drops on neonatal cerebral blood flow. *J Pediatr Neonat Individual Med.* 2018;7(1):e070102. doi: 10.7363/070102.

### Introduction

Retinopathy of prematurity (ROP) is a developmental vascular disorder affecting the retina of preterm infants and represents a potentially preventable cause of blindness in children [1].

The American Academy of Pediatrics and the American Association for Pediatric Ophthalmology recommend that all preterm infants who have birth weights less than 1,500 g or gestational ages of 30 weeks or less, as well as selected infants whose birth weights are between 1,500 and 2,000 g and who have an unstable clinical course, should receive fundus examination after pupillary dilatation to evaluate for ROP [2].

To attain the maximal and sustained mydriasis for proper fundus examination, two mydriatic eye drops are commonly used: phenylephrine hydrochloride 2.5% and tropicamide 0.5% eye drops. Phenylephrine has an alpha-1 sympathomimetic agonist effect, is readily absorbed from conjunctival mucosa and has a potent systemic vasopressor response [3]. Tropicamide has a short acting para-sympatholytic effect causing cycloplegia by inhibition of ciliary muscle contraction [4].

There are relatively few studies regarding the frequency and severity of adverse systemic effects caused by drugs used for ROP screening examination.

We performed an observational prospective study to explore whether local mydriatic eye drops impair cerebral blood flow velocity (CBFV) in preterm infants after ROP examination. We hypothesized that the systemic vasoconstriction effects observed in previous case reports could potentially extend and adversely affect the immature cerebral blood vessels.

Using Doppler ultrasound, we studied the peak systolic velocity (PSV), end diastolic velocity (EDV), and resistive index (RI) in both the anterior cerebral artery (ACA) and middle cerebral artery (MCA). Doppler flow studies were carried out before and 1 h after instillation of mydriatic eye drops.

### Methods

#### *Study design, setting, and participants*

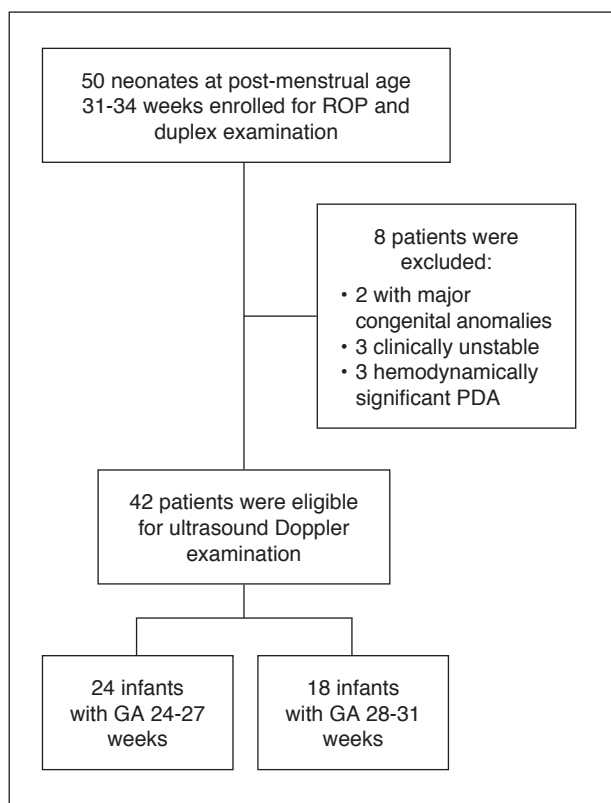
This observational prospective study was carried on eligible preterm infants admitted to the neonatal intensive care unit (NICU) at Dubai Hospital, United Arab Emirates (UAE). Forty-two preterm neonates with a gestational age (GA) of 24-31 weeks, who were hemodynamically stable and candidates for ROP examination, were enrolled after Dubai Scientific Research Ethics Committee approval of the study protocol. Written informed consent from parents was obtained before ultrasound examinations.

#### **Study protocol**

Preterm infants with GA ranging from 24 to 31 weeks were enrolled in the study according to the illustrated protocol (**Fig. 1**). The post-menstrual age at initial examination was 31 weeks (for those between 24-26 weeks) and 31-34 weeks (for those between 27-31 weeks) respectively according to the guidelines of ROP examination [5].

We excluded infants with major congenital abnormalities, hydrocephalus, clinical instability or hemodynamically significant ductus arteriosus (hsDA). Clinical instability was defined if the infant oxygen requirement exceeded 30%, was on inotropic support, was anemic or had unstable blood gases. HsDA was considered when the shunting was predominantly left-to-right across the ductus arteriosus with an associated left atrium (LA) to aortic (Ao) ratio > 1.4, and an EDV in the left pulmonary artery (LPA) > 0.2 m/s as detected by echocardiography.

One hour before mydriatic eye drops instillation, infants were examined, ventilation status and vital



**Figure 1.** Patient population in the study.

50 preterm infants with post-menstrual age of 31-34 weeks were enrolled for ROP examination, 8 infants were excluded due to congenital anomalies, hydrocephalus, and hemodynamic instability. 42 infants were subjected to ultrasound duplex examinations of cerebral arteries before and then 1 hour after ROP examination.

ROP: retinopathy of prematurity; PDA: patent ductus arteriosus; GA: gestational age.

signs were recorded. Heart rate, peripheral oxygen saturation ( $SpO_2$ ) in the right hand, and mean arterial blood pressure (MAP) were measured using Philips monitor IntelliVue MP70 Neonates (Royal Philips Electronics, the Netherlands). Pain score was evaluated by using the neonatal infant pain scale (NIPS) assessed by the caring bedside nurse over one minute and ranged from 0 to 7. A score of 2 or less meant no or mild pain, a score of 3-4 meant moderate pain and indicated non-pharmacological intervention, while a score of 5-7 indicated pharmacological and non-pharmacological intervention and implied severe pain.

Because of possible systemic effects of caffeine therapy on hemodynamics and CBFV, all these measurements were made before the daily caffeine dose.

Mydriatic eye drops phenylephrine hydrochloride 2.5% and tropicamide 0.5% were used for pupil dilatation at a dose of one drop, 3 times at 15 minutes interval, in both eyes prior to ROP examination.

The pulsed-wave ultrasound studies were performed by two trained neonatologists (A.A. and S.F.) using Philips HD 11XE (Philips Medical Systems, Eindhoven, The Netherlands) with a convex transducer (5-12 MHz) inside the incubator. We measured PSV and EDV for both the ACA and MCA and then calculated the RI, defined as  $PSV - EDV/PSV$ .

The anterior fontanelle was used in the sagittal plane to examine the CBFV in the ACA using color Doppler. The ACA was insonated as it curves around the corpus callosum. The CBFV of the MCA was measured through the temporal bone, 1 cm in front of the ear in an axial plane. The angle of insonation was close to 0 degrees for both arteries (**Fig. 2A** and **Fig. 2B**). Infants were examined in a supine position with the head in the midline horizontal position and were calmed by sucrose administration to decrease stress and pacify them when needed.

Ten CBFVs records were randomly selected and revised later by a radiologist who was blinded to the study to eliminate bias.

This protocol was performed twice for each patient, once before instillation of mydriatic eye drops and then 1 h after ROP examination at the onset of the pharmacological peak effect of medications.

## Main outcome

The primary outcome was defined as a significant increase in CBFV indices namely PSV, EDV and RI of ACA and or MCA after mydriatic eye drops instillation. The calculated CBFV parameters were compared to the reference parameters of the corresponding GA and postmenstrual age. The reference RI was variable according to GA and postmenstrual age and for both ACA and MCA, and ranged from 0.64 m/s (10<sup>th</sup> centile) to 0.86 m/s (90<sup>th</sup> centile) [6]. The changes in heart rate, blood pressure, oxygen saturation and pain score were considered as secondary outcomes.

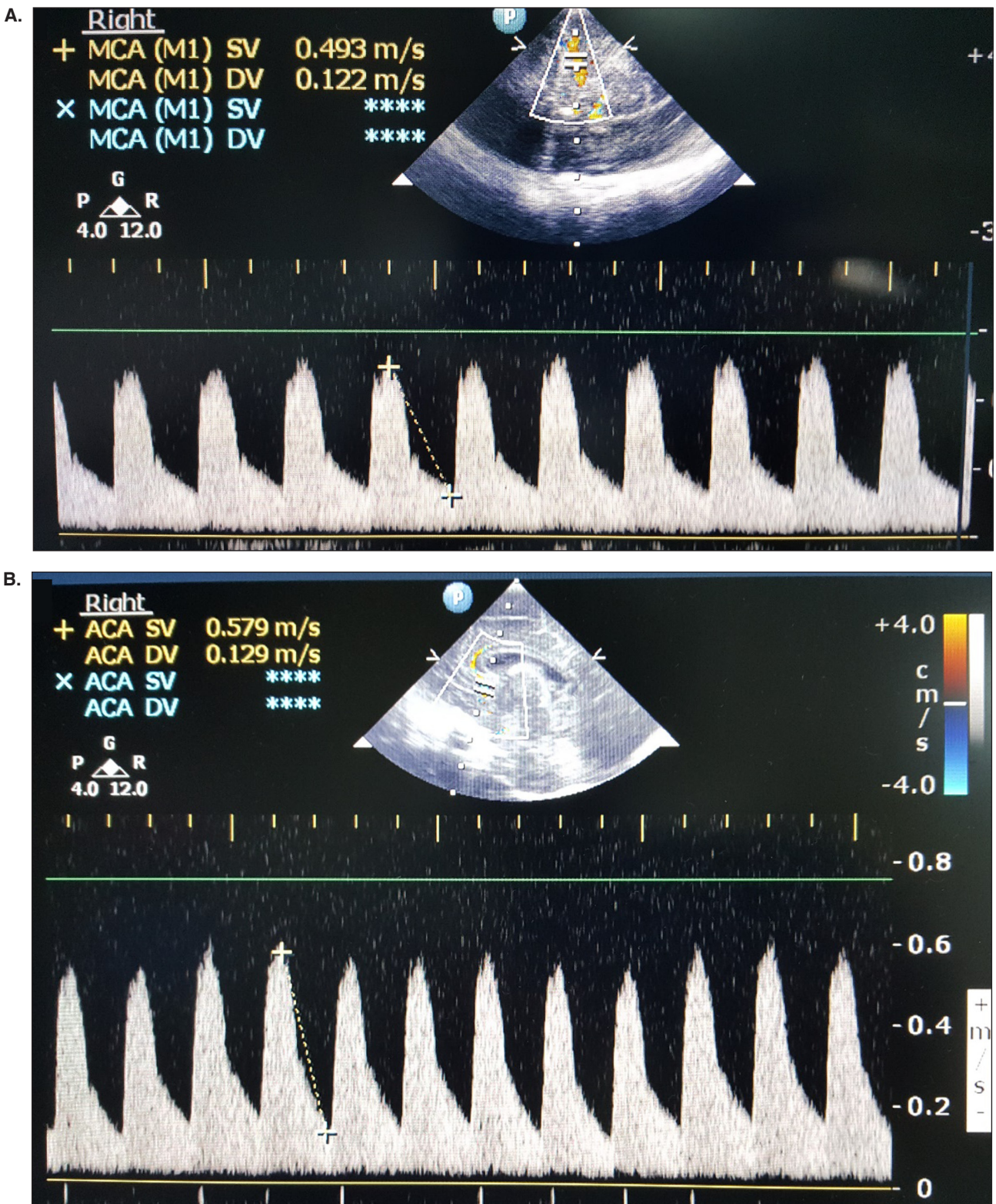
## Statistical analysis

Sample size could not be calculated properly on designing the study because of lack of comparable trials studying the same subject. However, 50 preterm infants were considered based on rate of NICU admission during the study period.

The collected data were revised, coded, tabulated and recorded using Statistical Package for Social Science (IBM® SPSS® Statistics for

Windows®, Version 20.0, released 2011. Armonk, NY: IBM Corp). Data were presented and suitable analysis was done according to the type of data

obtained for each parameter. A paired t-test was used to assess the statistical significance of the difference between two means measured twice



**Figure 2.** Cerebral blood flow velocity (CBFV) in anterior cerebral artery (ACA) and middle cerebral artery (MCA) by ultrasound duplex. **A.** Doppler waveforms study illustrated in an axial plane displaying peak systolic velocity (PSV) and end diastolic velocity (EDV) of MCA in a 26 weeks preterm infant. **B.** Duplex ultrasound study of ACA at sagittal plane as it curves around corpus callosum showing PSV and EDV. MCA: middle cerebral artery; ACA: anterior cerebral artery.

(before and after mydriatics instillation) for the same study group. The McNemar test was used to assess the statistical significance of the difference between a qualitative variable measured twice for the same study group. P-value > 0.05: non-significant; p-value < 0.05: significant; p-value < 0.01: highly significant.

## Results

Of the original 50 preterm infants enrolled in the study from February 20<sup>th</sup>, 2017 to June 20<sup>th</sup>, 2017, 42 patients were eligible and their data were available for final analysis. We excluded 3 infants with hsDA, 3 patients were clinically unstable and 2 infants with multiple congenital anomalies. Demographic data of infants in the study group are shown in **Tab. 1**.

The mean (SD) postnatal age at the time of examination was 50.7 (27) days ranging from 7 to 124 days and the mean (SD) birth weight was 980 (350) g ranging from 510 to 1,620 g.

Regarding respiratory support, 71% of infants were breathing room air (n = 30) and the remaining 12 infants were on non-invasive respiratory support either continuous positive airway pressure (CPAP) or heated humidified high-flow nasal cannula (HHHFNC) with a fraction of inspired oxygen (FIO<sub>2</sub>) of 21-25%.

The results of primary outcome are shown in **Tab. 2**. There was no statistically significant difference in RI of ACA and MCA before and after mydriatic eye drops instillation. In ACA, the mean (SD) RI before and 1 h after mydriatic eye drops installation was 0.84 (0.06) and 0.83 (0.07),

respectively (p = 0.453). While the mean (SD) RI of MCA before and then 1 h after mydriasis was 0.83 (0.05) and 0.83 (0.09), respectively (p = 0.559).

In ACA, RI was normal in 61.9% (n = 26) of infants after ROP examination, high in 33.3% (n = 14), and low in 4.8% (n = 2). While in MCA, RI was normal in 35.7% (n = 15) of infants after ROP examination, high in 57.1% (n = 24), and low in 7.1% (n = 3) of cases.

The changes in the CBFV parameters of PSV and EDV, in both the ACA and MCA, were statistically non-significant before and 1 h after mydriatic eye drops instillation.

After eye mydriasis, the PSV of ACA was high in 21.4% (n = 9) of cases while the EDV was only high in 7.1% (n = 3) of cases.

In MCA, on the other hand, the PSV was high in 19% (n = 8) of cases compared to the EDV which was high in only 4.8% (n = 2) of cases.

There were no significant statistical differences in pain score, SpO<sub>2</sub>, mean blood pressure and heart rate among the studied group of infants before and after mydriatic eye drops instillation.

## Discussion

We hypothesized that the systemic pharmacologic effects of sympathomimetic mydriatic eye drops could potentially extend to the immature cerebral blood vessels of preterm infants and impair cerebral blood flow. CBFVs are a reliable indicator of blood flow in neonatal cerebral arteries, which plays a fundamental role in different cerebral insults of the developing preterm brain [6]. However, we did not find any significant effect of the instilled eye drops on the CBFVs and RI which remained within normal reference ranges for the corresponding GA and postmenstrual ages. After ROP examination, the RI of both ACA and MCA increased in 30% and 50% of cases, respectively, but did not reach statistically significant values. We adopted the reference values of CBFV indices from the previous study of Romagnoli et al., being the largest, and studied a similar population group concerning gestational and post-menstrual age [6].

Tatar Aksoy et al. evaluated the effects of mydriatic eye drops on cerebral and mesenteric oxygenation by near infrared spectroscopy (NIRS) in very low birth weight infants after ROP examination. A slight decrease in cerebral and mesenteric oxygenation was observed af-

**Table 1.** Demographic data of infants during the study period.

		GA 24-27 weeks	GA 28-31 weeks
Number (%)		24 (64%)	18 (36%)
Postnatal age (days), mean ± SD		66 ± 25.1	30.3 ± 11.6
Current weight (kg), mean ± SD		1.6 ± 0.5	1.8 ± 0.36
Birth weight (kg), mean ± SD		0.63 ± 0.12	0.65 ± 0.22
Sex	Male	6 (14%)	7 (16%)
	Female	18 (42%)	11 (26%)
Ventilation	RA	13 (30%)	17 (40%)
	CPAP	7 (16%)	1
	IMV	3	0
	HHHFNC	1	0

GA: gestational age; RA: room air; CPAP: continuous positive airway pressure; IMV: intermittent mandatory ventilation; HHHFNC: heated humidified high-flow nasal cannula.

**Table 2.** Comparison of cerebral blood flow velocities (CBFV) before and after mydriatic instillation.

	ACA			MCA		
	Mean	± SD	p-value	Mean	± SD	p-value
PSV before (m/s)	0.50	0.13	0.478	0.67	0.17	0.299
PSV after 1 h (m/s)	0.49	0.11		0.64	0.16	
EDV before (m/s)	0.08	0.03	0.650	0.12	0.05	0.175
EDV after 1 h (m/s)	0.08	0.04		0.10	0.06	
RI before	0.84	0.06	0.453	0.83	0.05	0.559
RI after 1 h	0.83	0.07		0.83	0.09	

ACA: anterior cerebral artery; MCA: middle cerebral artery; PSV: peak systolic velocity; EDV: end diastolic velocity; RI: resistive index.

ter mydriatics instillation, however this was statistically non-significant [7].

ROP screening examination is a stressful procedure for the neonate and carries potential risk and discomfort either from the procedure or the medications used for pupillary dilation. A small body of literature has addressed the safety and side effects of mydriatic eye drops used prior ROP screening examination. Mydriatic eye drops do exhibit systemic effects on different body organs as they are absorbed readily from conjunctival mucosa, and pass through the nasolacrimal duct to be absorbed from the highly vascular mucosa [8].

These effects are more evident in premature infants, as they have an immature metabolic system, low body mass, small blood volume of approximately 1/20<sup>th</sup> of adults, and poor excretory function. Hence, premature infants are more susceptible to elevated plasma concentrations of locally instilled mydriatics [9].

Takayama et al. have investigated the topical effects of phenylephrine hydrochloride 5% on human and animal subjects and confirmed a significant increase in RI with a decrease in blood flow velocity of optic nerve and retinal arteries [10].

Phenylephrine hydrochloride 2.5% eye drops were found to induce vasoconstriction of conjunctival blood vessels through alpha adrenergic mechanisms and produced significant conjunctival hypoxia in an adult study [11].

Systemic side effects of mydriatic eye drops on the central nervous system have been reported previously and ranged from restlessness to ataxia and epileptic seizure especially with use of cyclopentolate and phenylephrine ophthalmic solutions [12, 13].

In our study, we did not find relevant changes in blood pressure or heart rate after mydriatics instillation. These findings concur with those

of Neffendorf and colleagues who found that a combination of phenylephrine hydrochloride 2.5% and cyclopentolate 0.5% had no cardiovascular or neurologic adverse effects during ROP examination and in the 24-h period afterwards [14]. Other studies found no significant changes in the blood pressure following ROP examination although a transient increase in heart rate and decreased oxygen saturation were observed, related to the infant discomfort and physical manipulation of the eyes [15-17]. However, an acute severe hypertensive episode was reported in a 5-month-old infant shortly after phenylephrine 5% eye drops instillation [18]. Local vasoconstriction of the infant's periorbital skin with pallor was observed in a previous report after 45 minutes of phenylephrine hydrochloride 2.5% instillation for ROP screening examination [19]. A case of cardiopulmonary arrest in a 6-week-old preterm infant was reported after use of tropicamide and phenylephrine hydrochloride 2.5% ophthalmic solutions for ROP screening [20].

Adverse systemic vasoconstriction effects of mydriatics could potentially impair renal function as reported by Shinomiya et al. [21] and cases of necrotizing enterocolitis and acute gastric dilatation have been reported previously following ROP screening [22].

We did not find any significant change in pain score secondary to the procedure or mydriatics use for ROP screening examination. Cohen and colleagues reported significant pain response to mydriatics in one third of the study group of preterm infants subjected to ROP examination [23]. Lack of pain expression in our study could be due to the routine use of oral sucrose, pacifiers and less time spent in scleral manipulation during eye examination [24]. The use of scleral depression and lid speculum during examination seems to be the most painful and noxious stimulus during the procedure [25]. However, pain experience is not merely due to

the eye examination and manipulation, it could be the local burning and stinging effect of the locally instilled mydriatics especially tropicamide as observed in adult studies [26].

We did not observe significant changes in oxygen saturation, apnea or bradycardia after ROP examination. This contrasts with previous case reports of desaturation episodes and bronchoconstriction following phenylephrine hydrochloride 2.5% eye drops instillation for ROP examination [27, 28]. Wood and Kaufman reported two cases of severe apnea, cyanosis, and bradycardia after instillation of cyclomydril eye drops (cyclopentolate and phenylephrine hydrochloride) for ROP screening examination in an outpatient setting [29]. Belda et al. have observed an increased incidence of significant apneic episodes in 41% of infants 24 h after ROP examination compared to 19% of infants before the procedure [30].

70% of infants in our trial were on room air at the time of ROP screening while the remaining 30% were on non-invasive respiratory support. Nasal CPAP or HHHFNC did not correlate with a change in CBFV compared to infants on room air; both groups had a normal RI in their cerebral arteries. Our results are consistent with two previous reports finding no effect of non-invasive ventilation on CBFV [31, 32].

This study had some limitations. Although RI was calculated at the end of study, other CBFVs were displayed and recorded by the two operators who were not blinded to the trial. Also, secondary outcomes were recorded only once after ROP screening by 1 h, accordingly late effects of medications that could extend for 24 h might have been overlooked.

## Conclusions

The current combination of mydriatic eye drops phenylephrine hydrochloride 2.5% and tropicamide 0.5% used for ROP screening examination are safe and, despite GA, carry no significant risk on the CBFVs of preterm infants. However, powered and randomized clinical trials are needed to investigate the short- and long-term sequelae on the developing immature brain with poor vascular autoregulation and a defective blood brain barrier.

## Declaration of interest

The Authors declare that there is no conflict of interest. Obtained funding: none.

## References

1. Zin A, Gole GA. Retinopathy of prematurity-incidence today. *Clin Perinatol.* 2013;40(2):185-200.
2. Fierson WM; American Academy of Pediatrics Section on Ophthalmology, American Academy of Ophthalmology, American Association for Pediatric Ophthalmology and Strabismus, American Association of Certified Orthoptists, Screening examination of premature infants for retinopathy of prematurity. *Pediatrics.* 2013;131(1):189-95.
3. Mitchell AJ, Green A, Jeffs DA, Roberson PK. Physiologic effects of retinopathy of prematurity screening examinations. *Adv Neonatal Care.* 2011;11:291-7.
4. Sweetman S. Antimuscarinics. In: Sweetman S (Ed.). *Martindale – The Complete Drug Reference, Edition 33.* UK: Pharmaceutical Press, 2002, p. 475.
5. Reynolds JD, Dobson V, Quinn GE, Fielder AR, Palmer EA, Saunders RA, Hardy RJ, Phelps DL, Baker JD, Trese MT, Schaffer D, Tung B; CRYO-ROP and LIGHT-ROP Cooperative Study Groups. Evidence-based screening criteria for retinopathy of prematurity: natural history data from the CRYO-ROP and LIGHTROP studies. *Arch Ophthalmol.* 2002;120(11):1470-6.
6. Romagnoli C, Giannantonio C, De Carolis MP, Gallini F, Zecca E, Papacci P. Neonatal color Doppler US study: Normal values of cerebral blood flow velocities in preterm infants in the first month of life. *Ultrasound Med Biol.* 2006;32(3):321-31.
7. Tatar Aksoy TH, Oguz SS, Özen Tunay Z, Yıldız R, Kanmaz HG, Dilmen U. Effect of mydriatic eye drops on cerebral and mesenteric tissue oxygenation in very low birth weight infants; preliminary report. *Arch Dis Child.* 2012;97(2):A371.
8. Le Jeunne C, Hugues FC, Munera Y, Haas C. Systemic effects of eyedrops. *Ann Med Interne.* 1990;141:674-7.
9. Patel AJ, Simon JW, Hodgetts DJ. Cycloplegic and mydriatic agents for routine ophthalmologic examination: a survey of pediatric ophthalmologists. *J AAPOS.* 2004;8:274-7.
10. Takayama J, Mayama C, Mishima A, Nagahara M, Tomidokoro A, Araie M. Topical phenylephrine decreases blood velocity in the optic nerve head and increases resistive index in the retinal arteries. *Eye (Lond).* 2009;23(4):827-34.
11. Isenberg SJ, Green BF. Effect of phenylephrine hydrochloride on conjunctival PO2. *Arch Ophthalmol.* 1984;102(8):1185-6.
12. Demayo AP, Reidenberg MM. Grand mal seizure in a child 30 minutes after Cyclogyl (cyclopentolate hydrochloride) and 10% Neo-Synephrine (phenylephrine hydrochloride) eye drops were instilled. *Pediatrics.* 2004;113:e499-500.
13. Büyükcım A, Tolga Çelik H, Korkmaz A, Yurdakök M. Myoclonic seizure due to cyclopentolate eye drop in a preterm infant. *Turk J Pediatr.* 2012;54:419-20.
14. Neffendorf JE, P. Mota PM, Xue K, Hildebrand GD. Efficacy and safety of phenylephrine 2.5% with cyclopentolate 0.5% for retinopathy of prematurity screening in 1246 eye examinations. *Eur J Ophthalmol.* 2015;25(3):249-53.

15. Rush R, Rush S, Nicolau J, Chapman K, Naqvi M. Systemic manifestations in response to mydriasis and physical examination during screening for retinopathy of prematurity. *Retina*. 2004;24:242-5.
16. Samra HA, McGrath JM. Pain management during retinopathy of prematurity eye examinations: a systematic review. *Adv Neonatal Care*. 2009;9:99-110.
17. Stavert B, McGuinness MB, Harper CA, Guymer RH, Finger RP. Cardiovascular adverse effects of phenylephrine eyedrops: a systematic review and meta-analysis. *JAMA Ophthalmol*. 2015;133(6):647-52.
18. Calenda E, Richez F, Muraine M. Acute hypertension due to phenylephrine eyedrops in a newborn. *Can J Ophthalmol*. 2007;42:486.
19. Alpay A, Ermis B, Ugurbas SC, Battal F, Sagdik HM. The local vasoconstriction of infant's skin following instillation of mydriatic eye drops. *Eur J Clin Pharmacol*. 2010;66(11):1161-4.
20. Agrawal Y, Malhotra D, Loker J. Retinopathy of prematurity screening leading to cardiopulmonary arrest: fatal complication of a benign procedure. *JACC*. 2016;67(13):1220.
21. Shinomiya K, Kajima M, Tajika H, Shiota H, Nakagawa R, Saijyou T. Renal failure caused by eye drops containing phenylephrine in a case of retinopathy of prematurity. *J Med Investig*. 2003;50(3-4):203-6.
22. Ozgun U, Demet T, Ozge KA, Zafer D, Murat S, Mehmet Y, Nilgun K. Fatal Necrotising Enterocolitis due to Mydriatic Eye Drops. *J Coll Physicians Surg Pak*. 2014;24(Suppl 2):S147-9.
23. Cohen AM, Cook N, Harris MC, Ying GS, Binenbaum G. The pain response to mydriatic eye drops in preterm infants. *J Perinatol*. 2013;33(6):462-5.
24. Sun X, Lemyre B, Barrowman N, O'Connor M. Pain management during eye examinations for retinopathy of prematurity in preterm infants: a systematic review. *Acta Paediatr*. 2010;99(3):329-34.
25. Kirchner L, Jeitler V, Pollak A, Müllner-Eidenböck A, Weinzettel R, Kraschl R, Waldhör T, Wald M. Must screening examinations for retinopathy of prematurity necessarily be painful? *Retina*. 2009;29(5):586-91.
26. Hassler-Hurst J, Wadham C, Rayman G. A double-blind study comparing 0.5% and 1% tropicamide for annual retinal screening in diabetic adolescents. *Diabet Med*. 2004;21(5):434-9.
27. Kim HJ, Choi JG, Kwak KH. Bronchoconstriction following instillation of phenylephrine eye drops in premature infants with bronchopulmonary dysplasia: two cases report. *Korean J Anesthesiol*. 2015;68(6):613-6.
28. Mirmanesh SJ, Abbasi S, Bhutani VK. Alpha-adrenergic bronchoprovocation in neonates with bronchopulmonary dysplasia. *J Pediatr*. 1992;121(4):622-5.
29. Wood MG, Kaufman LM. Apnea and bradycardia in two premature infants during routine outpatient retinopathy of prematurity screening. *J AAPOS*. 2009;13(5):501-3.
30. Belda S, Pallás CR, De la Cruz J, Tejada P. Screening for retinopathy of prematurity: is it painful? *Biol Neonate*. 2004;86(3):195-200.
31. Dani C, Bertini G, Cecchi A, Corsini I, Pratesi S, Rubaltelli FF. Brain hemodynamic effects of nasal continuous airway pressure in preterm infants of less than 30 weeks' gestation. *Acta Paediatr*. 2007;96(10):1421-5.
32. Chang HY, Cheng KS, Lung HL, Li ST, Lin CY, Lee HC, Lee CH, Hung HF. Hemodynamic effects of nasal intermittent positive pressure ventilation in preterm infants. *Medicine*. 2016;95(6):e2780.