

Rare lymphatic malformation in an extreme premature infant: question

Veronica Mugarab Samedi, Adel Elsharkawy

Neonatal-Perinatal Medicine, Alberta Health Services, Canada

The answers can be found in the following article:

*Samedi VM, Elsharkawy A. Rare lymphatic malformation in an extreme premature infant: answer.
J Pediatr Neonat Individual Med. 2017;6(2):e060210. doi: 10.7363/060210.*

Keywords

Lymphatic malformation, cystic lymphangioma, extreme prematurity, congenital mass.

Corresponding author

Veronica Mugarab Samedi, Neonatal-Perinatal Medicine, Alberta Health Services, Canada; email:
veronica.samedi@albertahealthservices.ca.

How to cite

Samedi VM, Elsharkawy A. Rare lymphatic malformation in an extreme premature infant: question.
J Pediatr Neonat Individual Med. 2017;6(2):e060209. doi: 10.7363/060209.

Case summary

Our patient was born to a healthy 35-year-old Asian mother. It was a planned pregnancy for the married couple who had had a healthy child before.

The mother used folic acid and prenatal vitamins as suggested by her family physician, her first trimester screening was normal, and her serologies were protective. This pregnancy was uneventful until 25 weeks of gestational age (GA), when she had preterm prolonged rupture of membranes (PPROM).

Ultrasound at that point showed a new finding of 4.7 x 4.1 cm heterogenous cystic skin-covered mass with areas of echogenicity on the posterior aspect of the fetus with blood flow to the mass and minimal vascularity overall (**Fig. 1**)

Fetal MRI confirmed the presence of hypointense soft-tissue lesion at the midline of the back, superficial to the mid and lower thoracic spine,

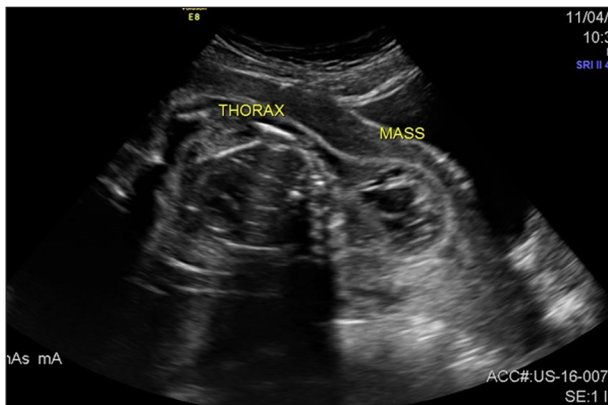


Figure 1. Fetal US showed cystic mass with areas of echogenicity on the posterior aspect of the fetus.

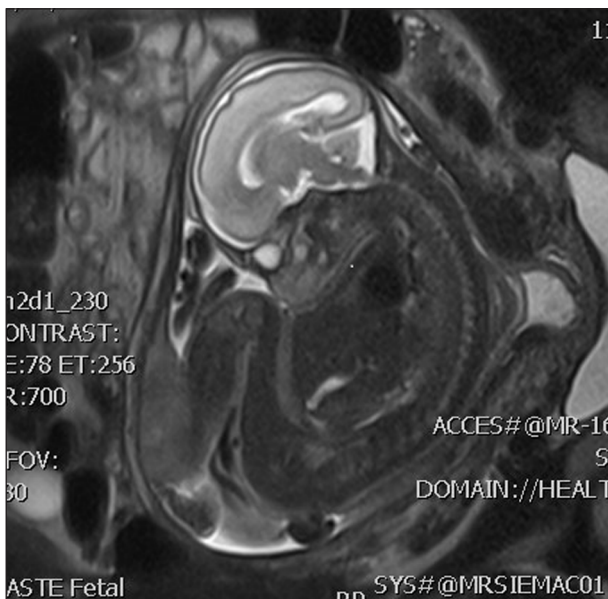


Figure 2. Fetal MRI showed well-defined lesion at the midline of the back, superficial to the mid and lower thoracic spine.

and excluded the possibility of spinal dysraphism (**Fig. 2**).

The male infant was delivered at 26⁺⁴ weeks by emergency caesarian section for fetal distress with birth weight of 720 grams, his APGAR scores were 6 and 9 on 1st and 5th minutes of life, respectively. He was admitted to NICU for further care.

On initial assessment, his vitals were stable and systemic examination was within normal limits for his gestational age. A significant finding was a massive swelling over the upper back with a firm central mass. Total size of swelling was 10.2 x 12.2 cm, central cystic mass was smaller (5.0 x 4.2 cm), firm in consistency, slightly mobile, non-pulsatile, non-compressible and non-translucent. Examination of mass did not cause changes in vital signs, thus the mass was considered as a painless malformation. **Fig. 3** shows initial presentation at birth.

Questions

1. What is your diagnosis?
2. Which further investigations would you suggest?
3. Which subspecialties need to be involved in the management of this case?

Declaration of interest

The Authors declare that there is no conflict of interest.

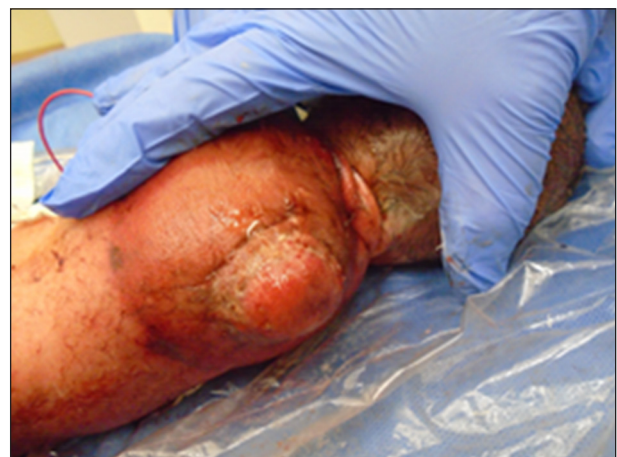

Figure 3. Initial presentation at birth.