

A model of integrated lung and focused heart ultrasound as a new screening examination in infants at risk of respiratory or hemodynamic compromise

Yasser Elsayed¹, Mohamed Abdelmawla¹, Michael Narvey¹, Jens Wrogemann²

¹Department of Pediatrics, University of Manitoba, Winnipeg, MB, Canada

²Department of Pediatric Radiology, University of Manitoba, Winnipeg, MB, Canada

Abstract

Objective: This was a feasibility study to determine whether an educational program conducted over 2 days followed by 25 performed studies under supervision equips physicians with the skills to accurately interpret and perform integrated lung ultrasound (LUS) and focused heart ultrasound (FHUS) as a screening exam in infants at risk of respiratory or hemodynamic compromise.

Methods: We conducted a training course over 2 days (total of 16 hours) to teach fellows how to interpret a pre-designed model of LUS and FHUS, as a screening exam for infants at risk of respiratory or hemodynamic compromise. Then trainees performed 25 cases with different neonatal lung and functional heart issues. The screening model included only the basic views required to evaluate common lung parenchymal and functional neonatal heart conditions in sick infants. The accuracy of interpretation during the course was assessed by Kappa.

Results: The inter-rater agreement between all trainees and instructor improved on the second day of the course to Kappa 0.86 (95% CI: 0.72-0.97) for LUS views and 0.78 (95% CI: 0.69-0.91) for FHUS views. The inter-rater agreement between trainees themselves improved from Kappa 0.64 (95% CI: 0.47-0.81) for LUS on day one to 0.89 (95% CI: 0.81-0.96) on day two. And from 0.58 (95% CI: 0.44-0.73) on day one to 0.75 (95% CI: 0.68-0.84) on day two.

Conclusion: Bedside screening, using integrated LUS and FHUS can be a useful adjunct to clinical examination in infants at risk of respiratory or hemodynamic compromise.

Keywords

Lung ultrasound, heart ultrasound, targeted neonatal echocardiography, neonatal hemodynamics.

Corresponding author

Yasser Elsayed, MD, PhD, Section of Neonatology, MS361L-820 Sherbrook Street, Winnipeg – Manitoba R3A1R9 – Canada; phone: +12047871879; fax: +12047871587; email: yelsayed@exchange.hsc.mb.ca.

How to cite

Elsayed Y, Abdelmawla M, Narvey M, Wrogemann J. A model of integrated lung and focused heart ultrasound as a new screening examination in infants at risk of respiratory or hemodynamic compromise. *J Pediatr Neonat Individual Med.* 2017;6(1):e060131. doi: 10.7363/060131.

Introduction

Use of point-of-care ultrasound has expanded over the last decades, particularly in intensive care, to the point that it is now readily available for use by the physician in this setting [1]. The focus of ultrasound by radiologists is on anatomy or pathology and often is employed in elective, non-urgent situations. Now, with clinicians actively using this bedside technology, attention has shifted to the critical evaluation of physiological abnormalities in different body systems. In the last 10 years, research studies have shown that lung ultrasound (LUS) is an accurate, non-invasive method for predicting ventilatory failure and offers advantages over traditional chest radiography [2]. Care of infants with compromised systemic circulation or at risk of hypoxemic respiratory failure can be one of the most challenging issues in neonatal intensive care. Traditional bedside physical examination can be misleading given the complex pathophysiology of compromised hemodynamics and the wide range of differential diagnoses of respiratory failure [3]. Patients with compromised hemodynamics and respiratory failure have higher risks for multiple adverse outcomes, including chronic lung disease, neurodevelopmental delay, and mortality [4]. Furthermore, these correlate with cumulative exposure to disturbed oxygen homeostasis (hypoxemia or hyperoxia). Inappropriate management due to misdiagnosis can lead to unfavorable outcomes [5].

LUS can accurately and reliably diagnose transient tachypnea of the newborn (TTN) and has a

great value in differentiating TTN from respiratory distress syndrome (RDS) [6]. Additionally, many of the common pulmonary and pleural diseases in neonates also display characteristic findings [7]. Targeted neonatal echocardiography (TNE) provides an objective assessment of cardiac function and output and permits assessment of response to therapeutic interventions [8]. It can provide real-time evaluation of abnormal pulmonary circulation either due to pulmonary hypertension or left-to-right shunt through a patent ductus arteriosus (PDA), but this requires prolonged and detailed training [9].

We developed a screening model of bedside ultrasound assessment for infants requiring cardiovascular or oxygen support which integrates both lung and focused heart ultrasound. We used the term focused heart ultrasound (FHUS) to differentiate our simplified protocol from more detailed TNE. The aim of this protocol was to give an objective, simplified assessment of lung parenchyma, pleura, and to evaluate both presence and effect of a PDA and pulmonary hypertension. This protocol can be performed by fellows in training or in-house physicians before considering a more detailed TNE by an expert staff member. Following the conclusion of the training program, we sought to determine the impact of this education to guide plans for further bedside clinical application.

Methods

We consulted Institutional Research Ethics Board, and they consider the study as a quality evaluation of our teaching program which does not need ethics approval. We conducted a two-day training program to nine subspecialty neonatal-perinatal medicine training fellows. We taught them how to interpret eight standard LUS views, and four standard FHUS for twelve selected cases, using both prepared video clips on a computer display for teaching views interpretation and high fidelity simulator (Vimedix ultrasound simulator, CAE Healthcare) for hands-on sessions. Day one was focused more on ultrasound basics and how to interpret normal views; day two included more cases with pathology. Inter-rater agreement between trainees and pre-evaluated views by trained neonatologist in ultrasound and echocardiography (Y.E.) was calculated. All fellows were requested to perform 25 cases for the purpose of training (after having the local logistic approvals), all cases were neonates admitted to neonatal intensive care unit neonatal intensive care unit (NICU) or intermediate

care nursery (IMCN). All studies were audited and evaluated by Y.E. and all studies gave an evaluation mark (maximum of 100) for both LUS and FHUS, separately. **Fig. 1** shows the algorithm of our integrated screening exam and the related clinical intervention. Description of the LUS and FHUS model and related interpretation are presented below.

I. Lung ultrasound views

Total of four lung views on each side (**Fig. 2**) for upper anterior (right, R1 and left, L1), lower anterior (R2 and L2), lateral (R3 and L3) lung zones, and costophrenic angle (R4 and L4) at the mid axillary line on both sides to evaluate for pleural effusions.

Interpretation of lung ultrasound in our model

Based on previous research by Brat et al. we employed a validated LUS severity score utilizing patterns of ultrasound artifacts [10] (**Fig. 3**).

Pattern 1: transverse repetition of artifact A-lines; pattern 2: separated longitudinal artifact B-lines (at least 3 lines in one frame); pattern 3: coalescent B-lines; pattern 4: subpleural consolidation with air bronchograms. Regardless of the pattern, the absence of lung sliding indicates the presence of a pneumothorax [10].

Conditions considered being evaluated by our model

Respiratory distress syndrome: Neonatal RDS is a consequence of deficiency of lung surfactant and is common in the preterm infant. Sonographically it appears as either coalescent B-lines, diffusely and homogeneously distributed in both lungs resulting in a picture of “white lung” (pattern 3), or in severe cases with air bronchograms and subpleural consolidation (pattern 4) (**Fig. 3**). This pattern may reflect fluid in normally aerated alveoli [11].

Transient tachypnea of the newborn: TTN is a common, usually mild, cause of neonatal respiratory distress, which can be differentiated by

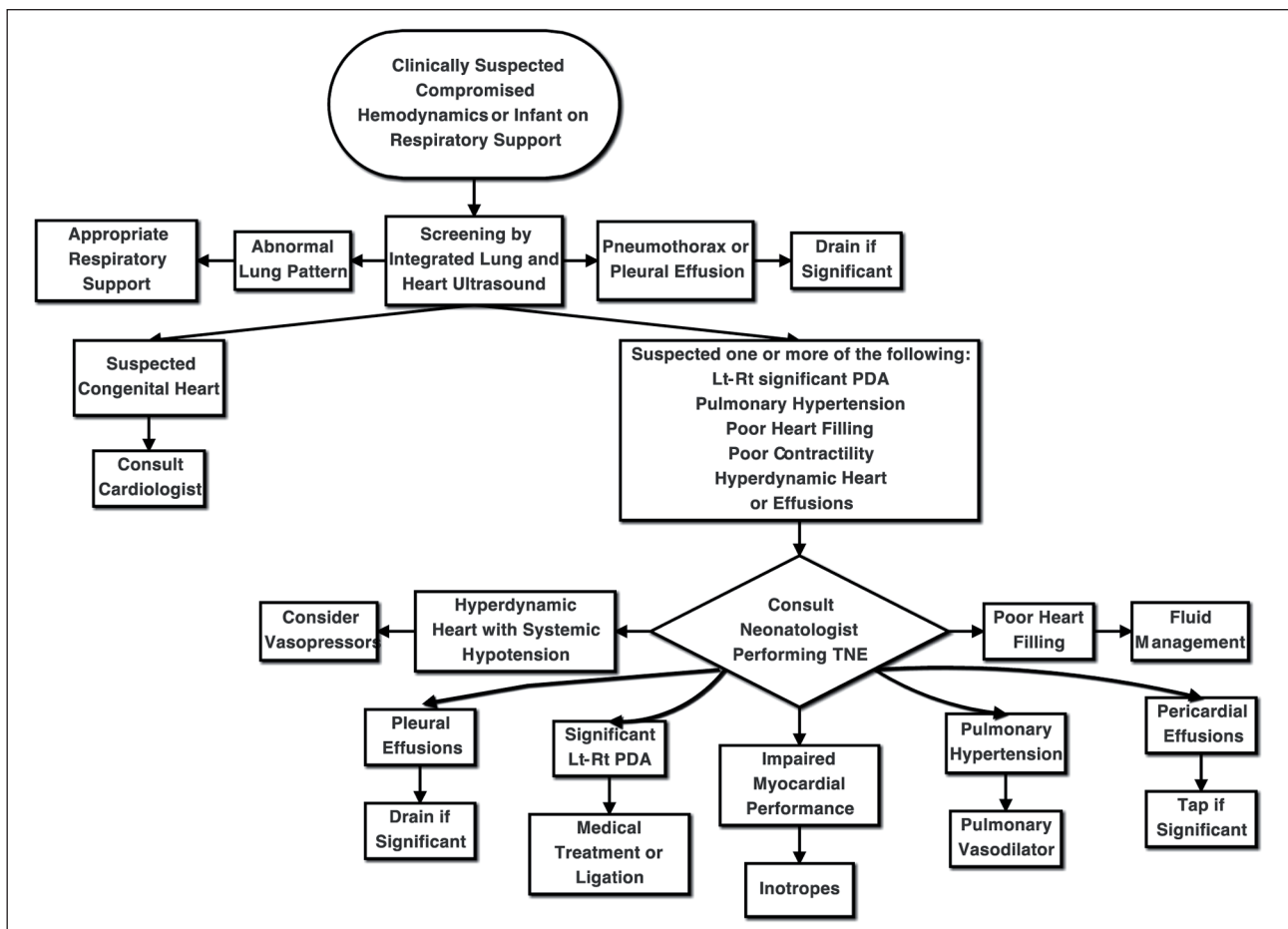


Figure 1. Integrated lung ultrasound (LUS) and focused heart ultrasound (FHUS) as a dynamic screening exam, with the related physiologic based and target directed clinical intervention.

PDA: patent ductus arteriosus.

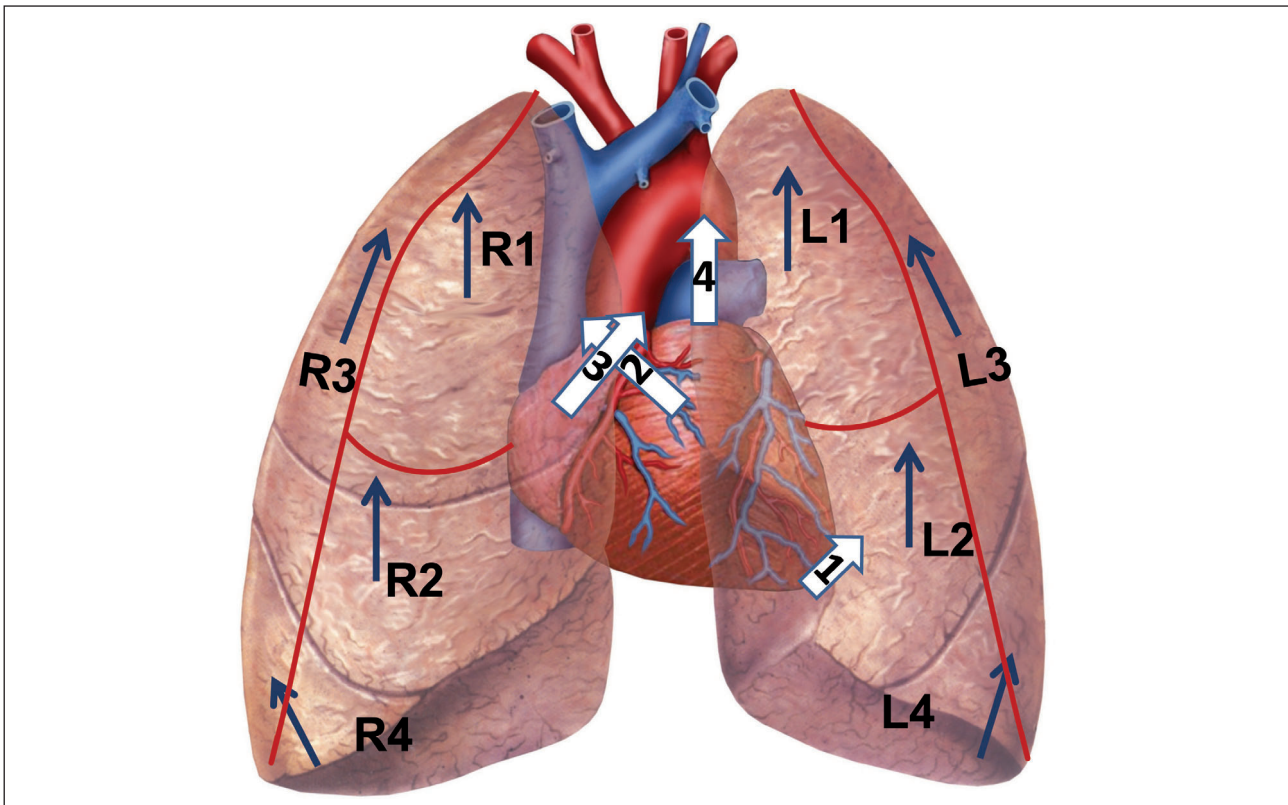


Figure 2. Scanning protocol of integrated lung and focused heart ultrasound. Lung zones: R1: right upper anterior, R2: right lower anterior, R3: right lateral, R4: right costophrenic angle; same sequence for left side. Focused heart ultrasound: white arrow 1: apical four chamber view, white arrow 2: parasternal long axis view, white arrow 3: parasternal short axis view, white arrow 4: ductal cut. Direction of all arrows is representing the direction of ultrasound probe.

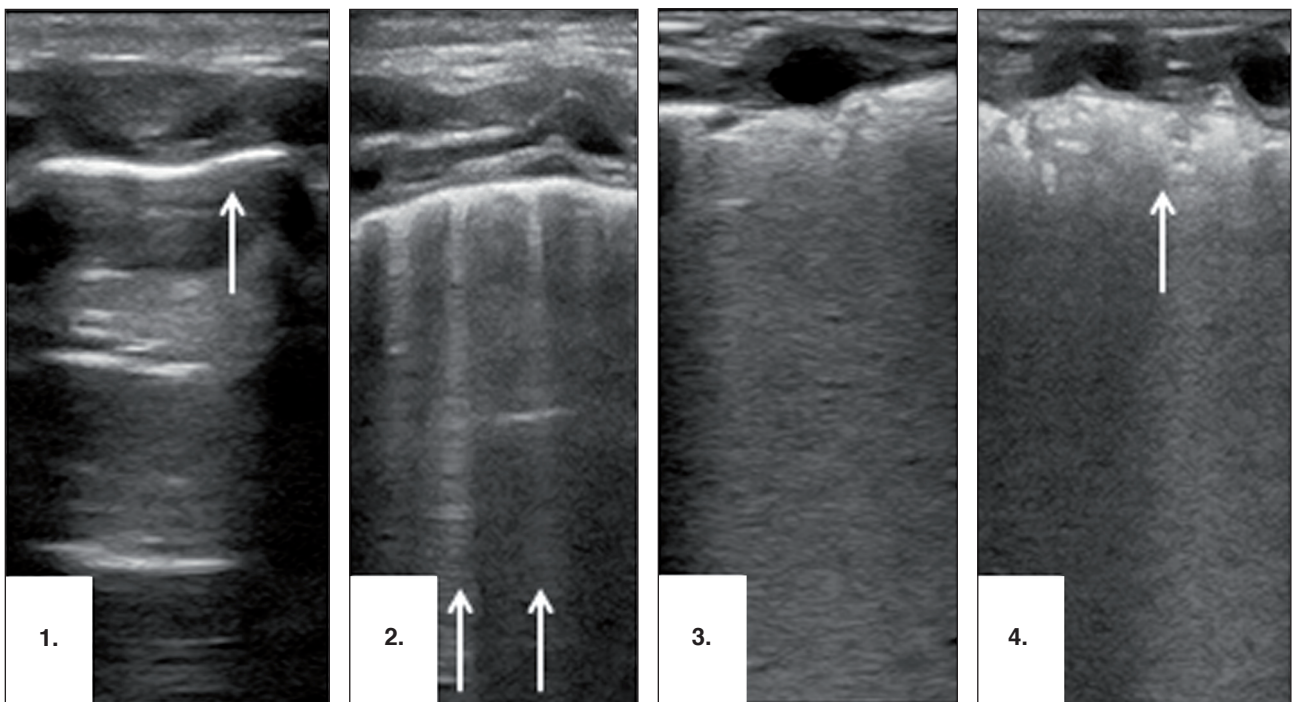


Figure 3. Four typical patterns of lung ultrasound. **1.** Normal lung aeration with transverse repetition of pleural image which is artifact A-line (arrow), absent sliding in this pattern signifies pneumothorax. **2.** Longitudinal separated B-lines (arrows) reaching the bottom of the image signifies interstitial fluid (transient tachypnea of the newborn [TTN] pattern). **3.** Coalescent B-lines with homogenous echographic view and thickened pleura (respiratory distress syndrome [RDS] pattern). **4.** Same as 3 with subpleural air bronchogram (arrow) bronchopulmonary dysplasia [BPD] pattern.

LUS from other conditions such as pneumothorax, pneumonia, sepsis, and RDS. In cases of TTN, the sonographic appearance characteristically shows bilateral differentiated B-lines (pattern 2) in mild cases or coalescent B-lines (pattern 3) in severe cases in the lower lung fields and normal or near-normal appearance in the upper lung fields (pattern 1). This finding is bilateral and nearly symmetric. The pleural line is normal in the areas of coalescent B-lines. This ultrasound finding is defined as “double lung point” and specific for TTN [12].

Bronchopulmonary dysplasia: Bronchopulmonary dysplasia (BPD) is a chronic lung disease in preterm neonates with varying degrees of severity and need for respiratory support and/or oxygen at 36 weeks gestation. In infants with BPD, all of the 4 described patterns can be found in one patient. Areas of non-homogenously distributed B-lines with pleural line thickening and multiple small subpleural consolidations (pattern 4) may be found [7]. The presence of spared areas and the severity of the described lung patterns correlate with the degree of chronic injury. Due to the non-homogenous lung pattern on ultrasound in BPD, we utilized the LUS score described in adults by Santos et al. [13] and modified in neonates by Brat et al. [10]. For each zone a score of zero to three is given. Zero for a lung zone with pattern 1, one for a lung zone with 3 or more separated B-lines (pattern 2), two for a lung zone with pattern 3, and three for a lung zone with pattern 4. Cumulative scores of four or more have previously been validated to be correlated well with increased oxygen requirement and need for surfactant [10].

Pleural effusion: Pleural effusion can accompany a variety of intra- and extrathoracic disease processes. The costophrenic angle is the best view to evaluate pleural effusions, which can be seen as hypoechoic fluid between the diaphragm and lung which may be collapsed in large effusions.

Pneumothorax: Pneumothorax is common in the neonatal period, particularly in ventilated newborns. On ultrasound, it is characterized by prominent A-lines, absent B-lines, absent lung sliding and possibly a double lung point sign [14] (**Fig. 4**).

II. Focused heart ultrasound

Intact or normal systemic hemodynamics implies adequate blood flow for delivering oxygen and nutrients to tissues [15]. Blood flow varies with vascular resistance and cardiac function, both of which are reflected by blood pressure

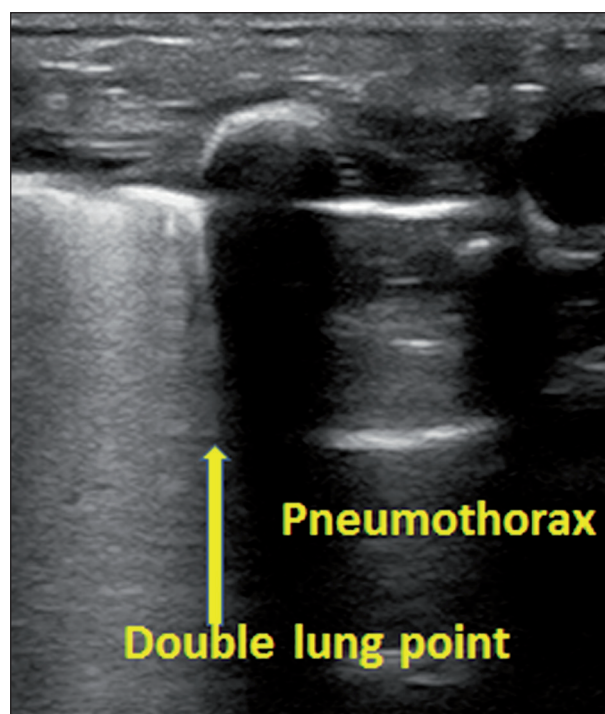


Figure 4. Double lung point in pneumothorax, the arrow representing the demarcation between pneumothorax and collapsed adjacent lung zone.

[16]. Failure to maintain adequate systemic blood flow can result in shock and multiple organ dysfunction. On the pulmonary side; maintaining normal pulmonary artery (PA) pressure is necessary for normal pulmonary circulation. This is achieved by the presence of physiologic pulmonary vascular resistance and an adequate right ventricular output. Conversely, increased pulmonary vascular resistance may impact right ventricular performance and normal pulmonary blood flow as in persistent pulmonary hypertension of the newborn (PPHN) [17]. If pulmonary circulation increases as in a significant left-to-right patent ductal shunts in preterm infants, resultant pulmonary over-circulation may cause ventilation-perfusion mismatch [18]. Both conditions can increase oxygen requirement and ventilatory support, with nonspecific clinical differentiating signs. The pattern of a PDA in the preterm can rapidly deteriorate, especially in the first 3-4 days of life. Thus a delay of even 24 hours in the thorough evaluation of the hemodynamic status can be detrimental for the whole clinical course of the patient. Thus, developing a protocol dedicated to core aspects of neonatal hemodynamics to arrange a screening model may enhance the clinical decision-making and decrease the number of unnecessary or non-urgent neonatal echocardiography requests.

In cases where this screening exam identifies impaired heart filling, impaired contractility, pericardial effusions, pulmonary hypertension or significant shunt through a PDA, a full evaluation by TNE by an expert neonatologist should be performed before considering interventions, and suspected congenital heart defect should be referred immediately to pediatric cardiologist. Implementation of such an abbreviated study or use of point-of-care ultrasound should not be considered in substitution of a TNE by an expert neonatologist or a comprehensive ultrasound exam by an expert radiologist. This model does not include a detailed Doppler or M-mode assessment. The last two techniques should be performed as part of a detailed echocardiographic assessment when the initial screening is doubtful.

Views included for focused heart ultrasound

1. Apical four chamber view to observe overall cardiac performance by determining the ratio between the left and right ventricular size (normal right ventricle [RV] is 2/3 left ventricle [LV] after first 72 hours of life, which is the postnatal transition); a dilated RV being a sign of pulmonary hypertension, adding color Doppler helps to demonstrate interventricular septum (IVS) defects, **Fig. 5** shows this view in different clinical conditions.
2. Parasternal long axis view to obtain the ratio between left atrium (LA) and aorta (AO) (a reliable sign of left heart volume overload) in the presence of a PDA causing hemodynamic compromise. This view is also helpful to detect

suboptimal filling of the left heart chambers and differentiate pericardial from pleural effusions. The accumulated fluid in a pericardial effusion is between the pericardial sac and the myocardium, in a location anterior to the descending aorta (DAO). Pleural effusion is seen as accumulation of fluid outside the pericardial sac and posterior to the DAO as in **Fig. 6**.

3. a. Parasternal short axis view at the level of the base of the heart, to check normal patency and continuation of the main PA to the 2 main branches. It also confirms the normal relationship between the great arteries. In the presence of PDA, a third vessel to the left of left pulmonary branch exists connecting the DAO to the PA as in **Fig. 7**.
- b. Parasternal short axis view at the level of the mitral valve or papillary muscles to check the movement of the IVS. Normally it should be rounded and forming part of the regular round contour of the LV in systole and diastole. Conversely, it appears as flattening or bulging into the LV in moderate and severe pulmonary hypertension respectively [19] (**Fig. 8**).
4. High parasternal view (ductal cut or 2-vessel sign) using 2-dimensional (2-D) views with color Doppler to check ductal patency. The trainee was required to comment on the absence of ductal flow between 2 vessels (DAO and PA and both with blue color Doppler). Presence of significant left-to-right shunt can be appreciated if 3 vessels are detected (2 vessels with blue color Doppler and in between them a third vessel with red or blue color Doppler according

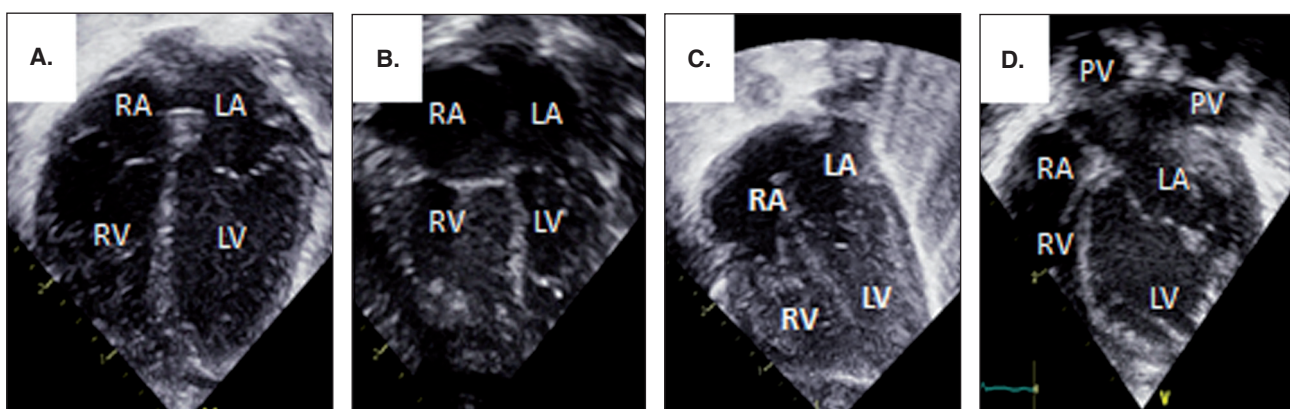


Figure 5. **A.** Normal 4 chamber view with RV:LV ratio is normal and apex made by LV. **B.** 4 chamber view in pulmonary hypertension with dilated RV and apex made by RV. **C.** 4 chamber view with under filling and small cavities of both ventricles in infant with volume depletion. **D.** 4 chamber view with significant dilation of LV, LA and pulmonary veins due to significant patent ductus arteriosus (PDA) in a preterm infant.

LA: left atrium; LV: left ventricle; RA: right atrium; RV: right ventricle.

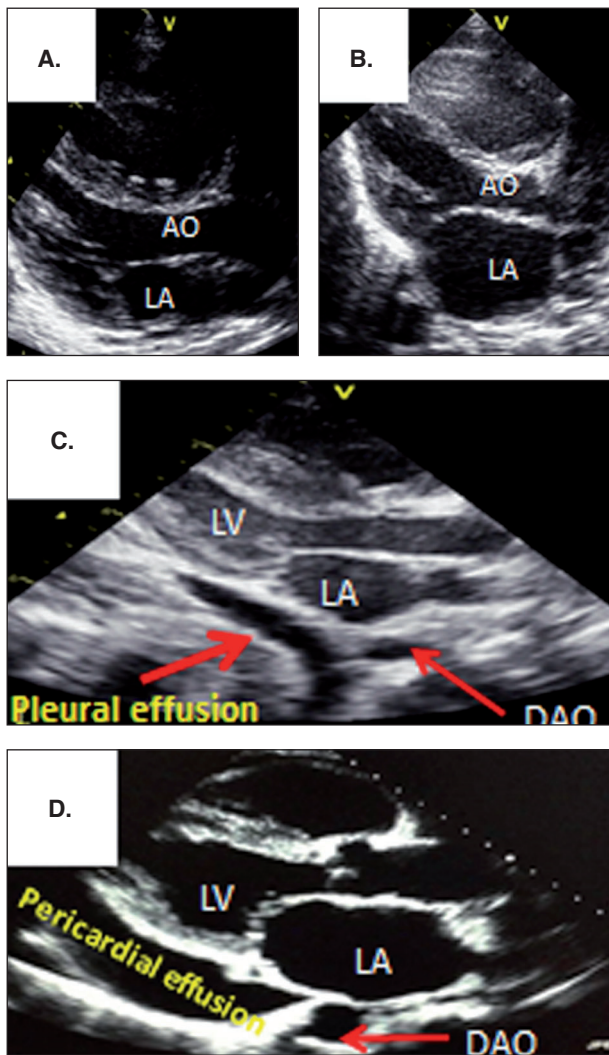


Figure 6. Long axis parasternal view with normal LA size in image **A**, and dilated due to PDA in image **B**. Image **C** shows mild pleural effusion outside the pericardial sac and passing posterior to the cross section of DAO; it should be differentiated from pericardial effusion in image **D** with fluid within the pericardial sac and passing anterior to the cross section of the DAO.

AO: aorta; DAO: descending aorta; LA: left atrium; LV: left ventricle.

to the direction of the flow). Tavera et al. described 4 patterns of PDA as identified by pulsed Doppler: pulmonary hypertension with bidirectional shunt for early postnatal transition, a growing pattern with mainly left-to-right flow when pulmonary vascular resistance drops after birth and a pulsatile pattern for significant left-to-right shunt, and closing non-significant left-to-right shunt [20].

As we are relying on 2-D and color Doppler, we classified the PDA into 6 patterns with different clinical significance as in **Fig. 7** and **Fig. 9**:

1. Pulmonary hypertension pattern with right-to-left shunt. A PDA can be identified in the short axis

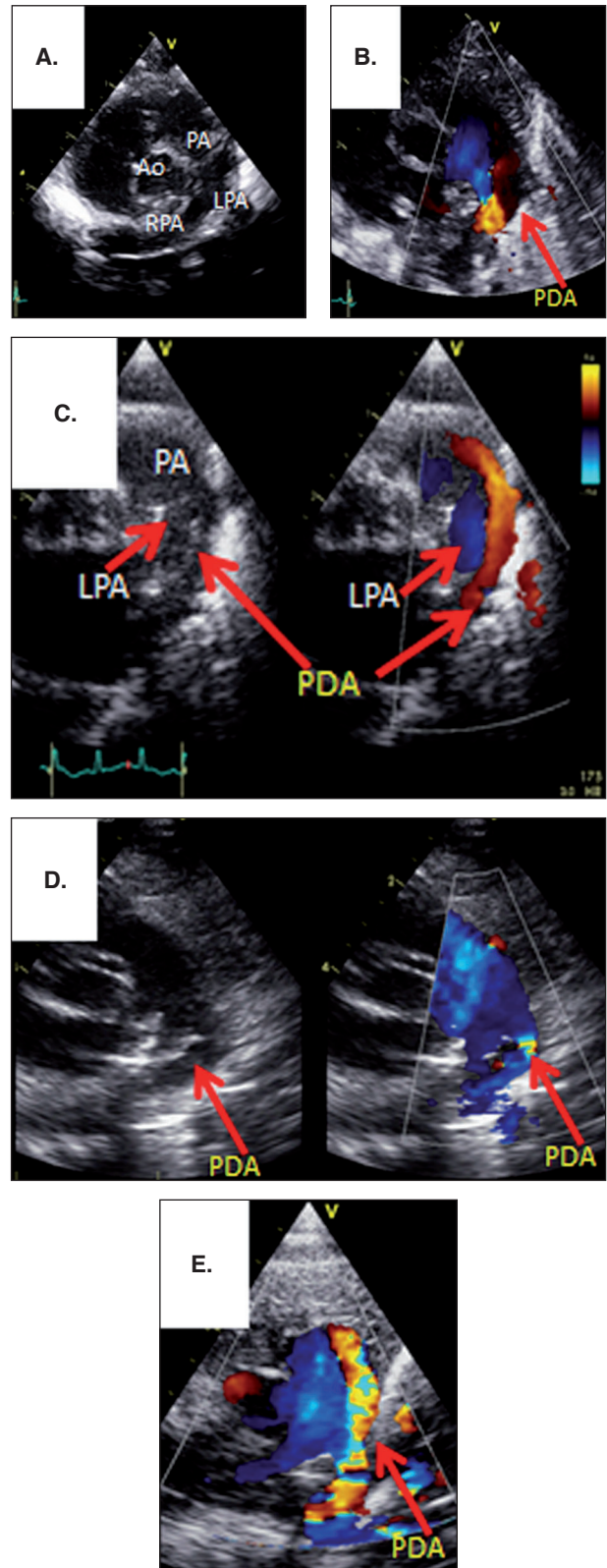


Figure 7. **A.** Short axis parasternal view at the level of heart base, with normal anatomy. **B.** Large PDA pattern (wide red jet extends for short distance in the PA). **C.** Moderate PDA pattern (narrow red jet deeply extends inside the PA). **D.** Pulmonary hypertension pattern with blue color flow. **E.** Restrictive PDA pattern with mosaic color jet deeply extends inside PA.

AO: aorta; LPA: left pulmonary artery; PA: pulmonary artery; PDA: patent ductus arteriosus; RPA: right pulmonary artery.

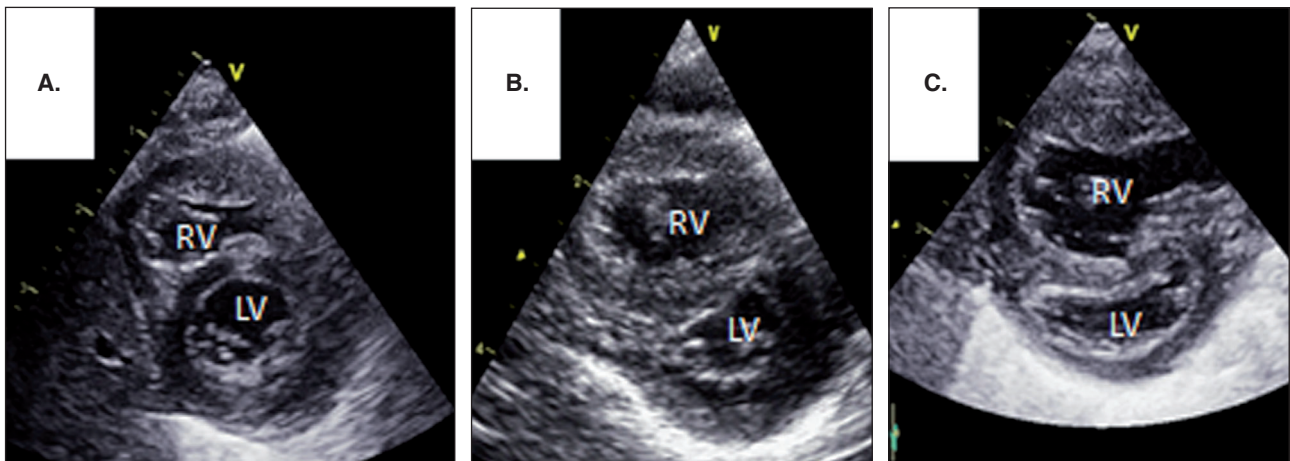


Figure 8. Short axis parasternal view at the level of mitral valve. **A.** Normal curvature of IVS and normal size of RV. **B.** Flat IVS with mild dilatation of RV due to pulmonary hypertension. **C.** IVS bows to the LV with significant dilation of RV due to severe supra-systemic pulmonary hypertension.

LV: left ventricle; RV: right ventricle; IVS: interventricular septum.

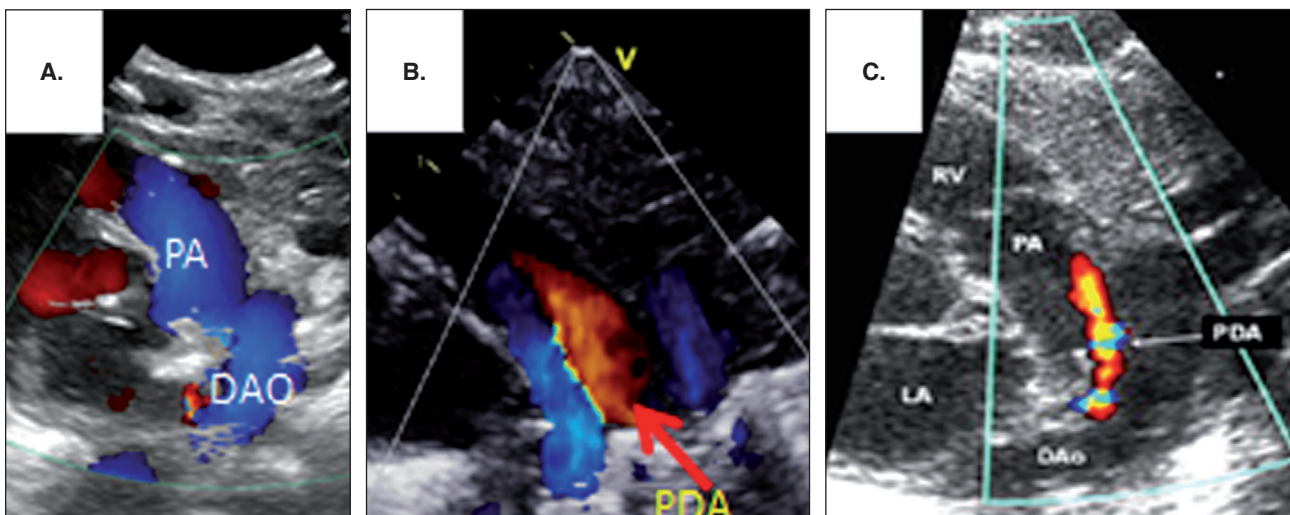


Figure 9. High parasternal view (ductal cut). **A.** No PDA by color between PA and DAO. **B.** Large PDA pattern **C.** Closing PDA pattern.

DAO: descending aorta; LA: left atrium; PA: pulmonary artery; PDA: patent ductus arteriosus; RV: right ventricle.

parasternal view by the so-called “three fingers image” (2 pulmonary branches and the PDA). As well, the high parasternal view shows the PDA as a vessel connecting the PA from left side of left PA (LPA) to DAO. Moreover, by color Doppler the “hypertensive” PDA shows as a blue flow between LPA and DAO. These are the signs of failed transition from high fetal PA pressure to lower neonatal levels due to perinatal hypoxia.

2. Transitional pattern: it can be viewed as the same as in pattern 1 but the color is alternating between blue (right-to-left in systole) and red (left-to-right in diastole), this is a common physiologic pattern during transition from fetal

to neonatal circulation usually in the first 12 hours of age or longer in infants with respiratory distress or perinatal hypoxia. As well, it is the typical pattern of a pulmonary hypertension, either mild or sub-systemic.

3. Large left-to-right pattern: the PDA can be identified in the short axis parasternal 2-D view by the so-called “three fingers image” (2 pulmonary branches and the PDA), or high parasternal as a vessel between the LPA and DAO. Most often it is larger than 2 mm in diameter, a red flow is present at color Doppler on the left side of LPA and extends inside the main PA. This pattern, if associated with

increasing oxygen requirement and ventilatory support, is considered as a hemodynamically significant PDA.

4. Moderate left-to-right pattern: the PDA can be identified in the short axis 2-D view by the so-called “three fingers image” (2 pulmonary branches and PDA) or high parasternal as a vessel between the LPA and DAO. Most often it is narrower than pattern 3, namely less than 2 mm, by color Doppler it is detected as a red flow jet on the left side of the LPA extending inside the main PA, sometimes up to the pulmonary valve. This pattern, if associated with increasing oxygen requirement and ventilatory support, could be considered as a hemodynamically significant PDA.
5. Restrictive PDA pattern: it can be detected by the same scans as in patterns 2 and 3 but with a constrictive lumen at the pulmonary end or a shelf restricting the flow. For this reason the flow will appear at color Doppler as a mosaic due to the turbulence created by the narrowed lumen. This kind of PDA is hemodynamically not relevant.
6. Closing pattern: difficult to identify by 2-D without color Doppler, the color jet is a mosaic and the flow is tiny.

The four standard heart views with the expected interpretation are outlined in **Tab. 1**. The model can be performed within a 10-minute time frame by the person who has completed the required audited training.

Statistical analysis

We evaluated Kappa values of inter-rater agreement as described. Pearson correlation was used to correlate fellows' performance with study order number. We calculated the median and interquartile ranges of fellows' performance. SPSS® v. 24 (SPSS Inc, Chicago, Illinois) was used to perform the statistical analysis.

Results of the training course model

Two instructors were involved in this training model; a neonatologist trained in TNE and LUS and a pediatric radiologist. Nine neonatal perinatal fellows with little or no previous exposure to ultrasound were taught how to interpret LUS and FHUS and then given an exam consisting of 6 ultrasound studies at the end of day one (mainly normal ultrasound views). Evaluation of the trainee's performance by measuring inter-

Table 1. Focused heart assessment with standard 4 views.

Heart view	Check	Expected Interpretation
1a. Apical 4 chamber view	RV Performance (Normal-impaired) by eyeballing	Impaired RV performance in severe pulmonary hypertension
	LV Performance and filling (Normal-impaired) by eyeballing	Impaired LV performance and/or LV filling in compromised systemic circulation or severe pulmonary hypertension
	RV:LV (Normal 2/3) by eyeballing	Dilated RV in pulmonary hypertension with apex made by RV
1b. Apical 4 chamber view with color	Intact IVS	VSD or AVCD
2. Parasternal long axis view	LA:AO ratio	Ratio > 1.5 in presence of PDA is a sign of left heart volume overload
	Fluid collection surrounding the heart and within the pericardium, or outside pericardium	Pericardial or pleural effusion
3a. Parasternal short axis view (base of the heart view)	Normal flow through PA to 2 branches, and connecting vessel with DAO	Presence of vessel (PDA) on the left side of the left pulmonary connecting PA to DAO
3b. Parasternal short axis view (level of the papillary muscle)	IVS: normal rounded, flat or bows to left ventricle	Moderate or severe pulmonary hypertension
4. Ductal cut	PDA (third vessel between aorta and pulmonary arteries) by color Doppler	Red homogenous: significant left to right shunt mosaic: small restrictive left to right shunt Blue: right to left

RV: right ventricle; LV: left ventricle; IVS: interventricular septum; VSD: ventricular septal defect, AVCD: atrio-ventricular canal defect; LA: left atrium; AO: aorta; PDA: patent ductus arteriosus; PA: pulmonary artery; DAO: descending aorta.

Table 2. Inter-rater agreement between trainees and instructor.

	Inter-rater agreement (Kappa)	95% confidence interval
Between all fellows (average) and the instructor – day one		
Lung ultrasound	0.61	0.41-0.77
Heart ultrasound	0.57	0.37-0.68
Between fellows themselves (n = 9) – day one		
Lung ultrasound	0.64	0.47-0.81
Heart ultrasound	0.58	0.44-0.73
Between all fellows (average) and the instructor – day two		
Lung ultrasound	0.86	0.72-0.97
Heart ultrasound	0.78	0.69-0.91
Between fellows themselves (n = 9) – day two		
Lung ultrasound	0.89	0.81-0.96
Heart ultrasound	0.75	0.68-0.84

rater agreement between trainees themselves, and between all trainees (averaged) and the instructor were good (**Tab. 2**).

A second day of teaching with a more detailed ultrasound simulation model followed by another 6 ultrasound test studies were administered and inter-rater agreement measured. Results demonstrated a significant increase in the confidence for interpreting lung and heart views. Cases presented on the second day included pleural effusions, pneumothorax, RDS, TTN, mild, moderate and severe BPD, pulmonary hypertension with and without impairment of right ventricular function, and a large PDA with lung overcirculation and edema. Ultrasound findings in the teaching model typically correlated with the clinical findings and were performed by a single expert operator (Y.E.) using the same machine for selected cases (Zonare Ultrasound-SP – Mountain view, California, USA).

A total of 225 studies were performed by all fellows over a median period of 4 (IQR: 2-7) weeks. LUS studies showed strong positive correlation with the increasing order number of the study, $r = 0.9$ ($p = 0.0001$). **Fig. 10** shows the correlation curve between the mean assessment mark of the nine fellows and order number of the study steeply directing up and flattening after study number 20. Heart ultrasound studies showed strong correlation with the increasing order number of the study, $r = 0.9$ ($p = 0.0001$). **Fig. 11** shows the correlation curve between the mean mark of the nine fellows and order number of the study steeply directing up, more slowly compared to LUS. **Fig. 12** shows the correlation between all LUS studies performed by

the nine fellows and order number of the studies, $r = 0.78$ ($p = 0.001$). **Fig. 13** shows the correlation between all FHUS studies performed by all fellows and order number of the studies, $r = 0.73$ ($p = 0.002$). Median (IQR) of the best and lowest fellow performance in LUS were 86 (81, 91) and 61 (44, 74), respectively. The median (IQR) of the highest and lowest fellow performance in FHUS were 76 (71, 79) and 48 (44, 75). Normal studies were 42% and abnormal studies with variety between mild to severe lung conditions were 58%.

Discussion

LUS is a diagnostic tool increasingly used in the critical care setting to provide standardized data [21]. Nevertheless, it has been suggested that in complex clinical conditions, such as neonatal respiratory and hemodynamic compromise, only a combined heart and lung evaluation can accurately assess the multifactorial interactions found in these circumstances [22]. In agreement with this hypothesis, the current study demonstrates the feasibility of teaching a new model of integrated heart and lung ultrasound as a screening examination for infants at risk of hypoxemia related to parenchymal lung diseases or hemodynamic compromise. Performing such a point-of-care ultrasound examination may improve the findings after physical examination of the heart and lungs, and minimize administration of radiation by chest radiographs. TNE and point-of-care ultrasound have rapidly been integrated into clinical care in the last decade [23]. Increasingly, practicing physicians are now trained in TNE and ultrasound

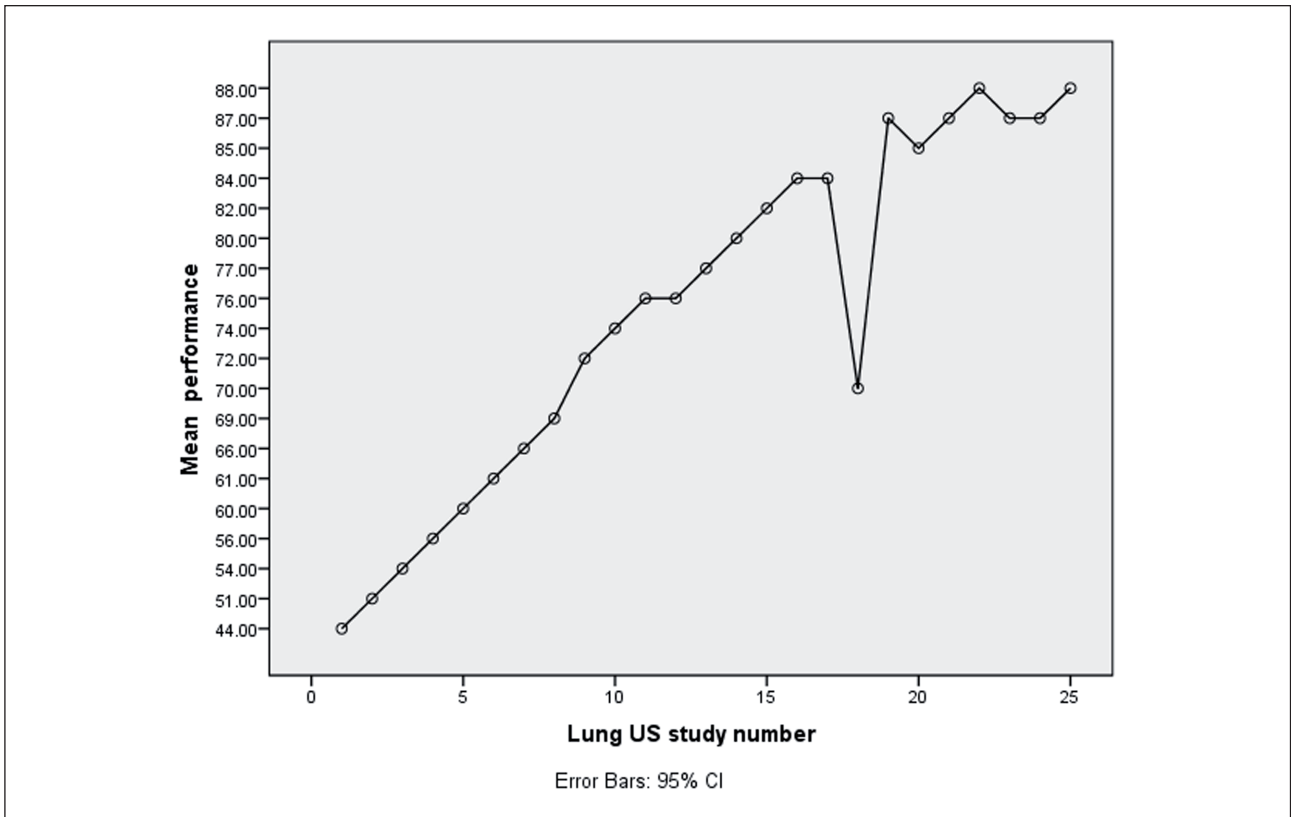


Figure 10. Correlation curve of fellows’ performance in lung ultrasound (LUS), horizontal axis represents order number of studies, and vertical axis represents mean of performance mark.

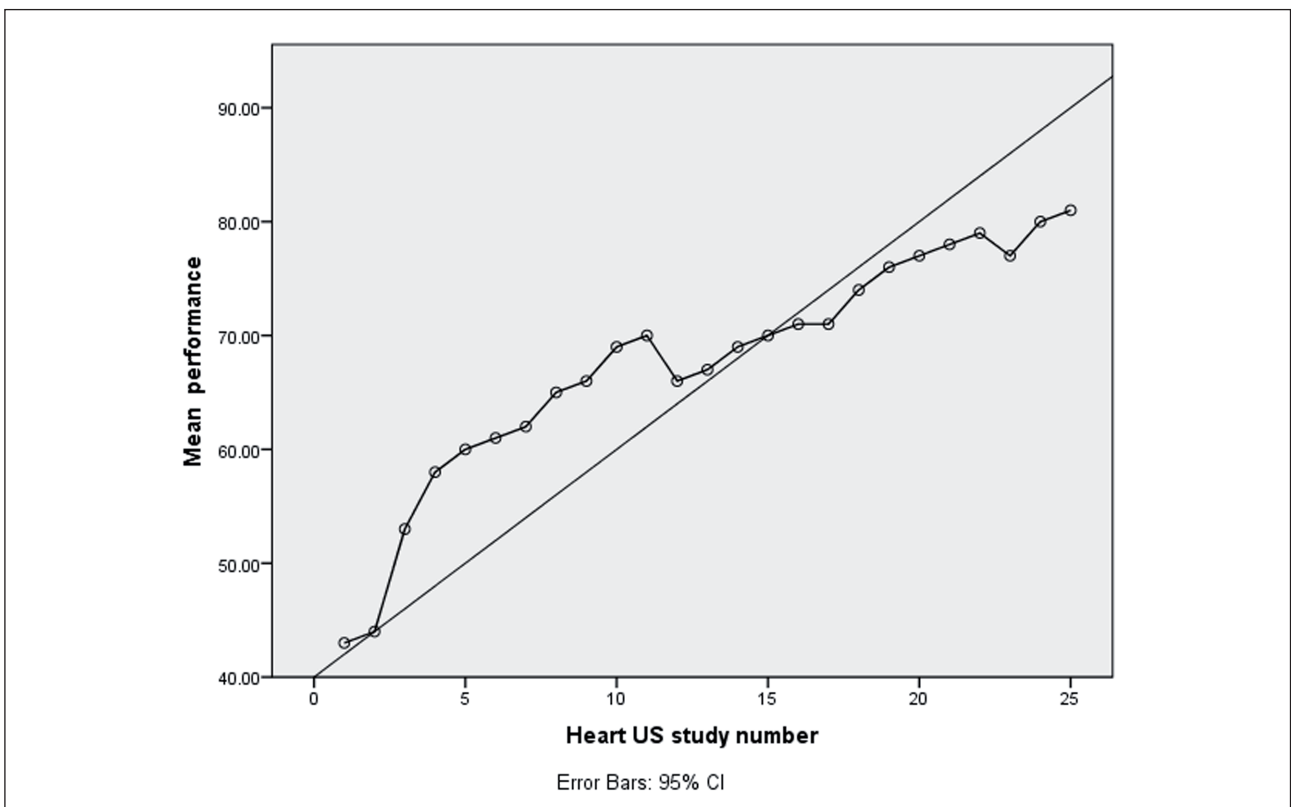


Figure 11. Correlation curve of fellows’ performance in focused heart ultrasound (FHUS), horizontal axis represents order number of studies, and vertical axis represents mean of performance mark.

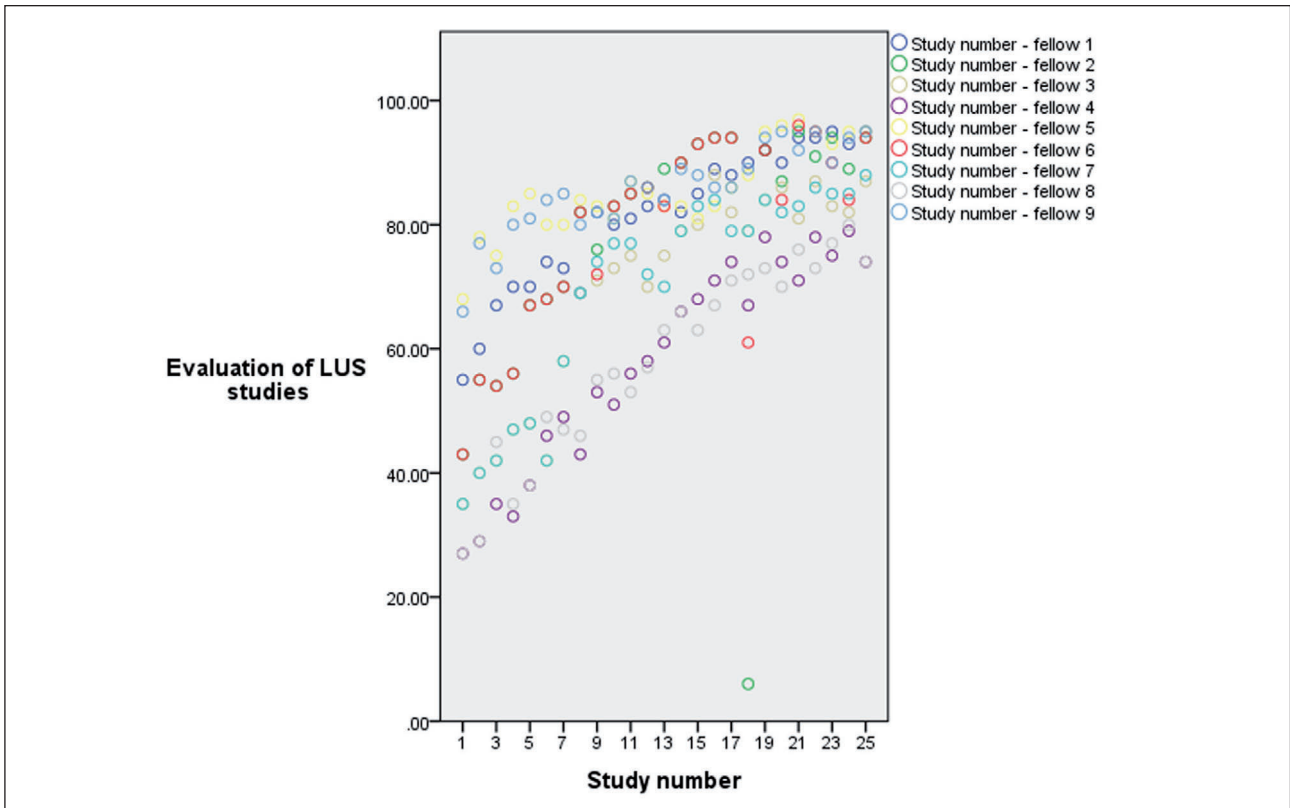


Figure 12. Correlation curve of all fellows' performance in lung ultrasound (LUS), horizontal axis represents order number of studies, and vertical axis represents performance mark (maximum of 100).

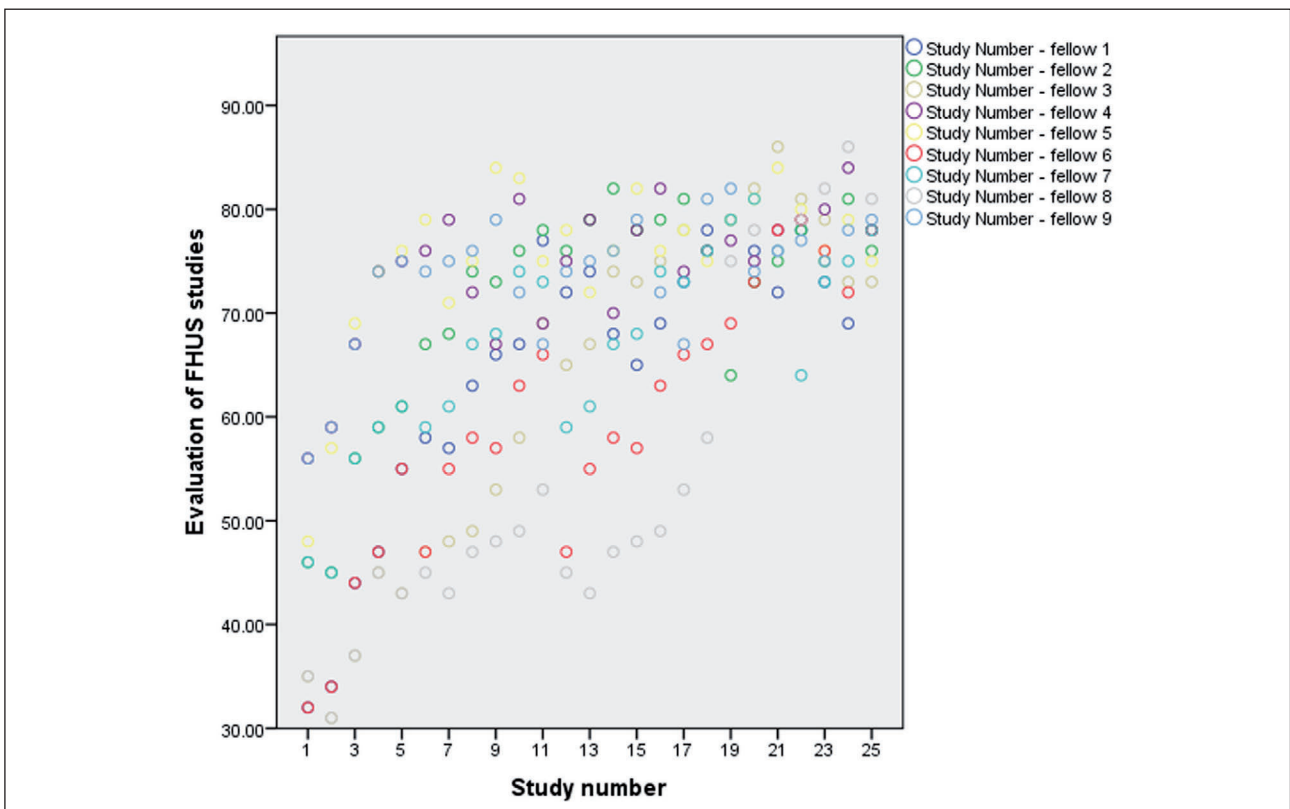


Figure 13. Correlation curve of all fellows' performance in focused heart ultrasound (FHUS), horizontal axis represents order number of studies, and vertical axis represents performance mark (maximum of 100).

while attending programs at North American Institutes [23]. Studies have demonstrated that initial integration of bedside ultrasound into the evaluation of the sick infants results in a more accurate diagnosis with an improved structured care planning [9]. Instead of relying on subjective clinical signs such as auscultation of abnormal sounds suggestive of specific pathology, bedside ultrasound now allows direct visualization of pathology or abnormal physiological states. Thus, bedside ultrasound is becoming an increasingly essential component in the evaluation of the sick infants. In this model we combine selected heart views for quick and focused evaluation of sick neonates together with LUS (integrated approach) in one protocol and demonstrate that competency in interpretation can be achieved in a short time, especially compared to comprehensive TNE.

In adult intensive care unit, integrated thoracic ultrasound including LUS and FHUS has significantly better performance than LUS alone in the diagnosis of acute respiratory failure and is particularly useful to distinguish cases of hemodynamic pulmonary edema and pneumonia [22]. This approach has not been previously studied in the neonatal age group.

In our model we have shown that integrated LUS and FHUS can be taught to trainees over a short period of time with improved Kappa of agreement on the second day of training as a preparation of successful hands on training for less than 2-month period. Combining real and simulator-based cases has resulted in a better comprehension of the pathophysiological effect of several conditions in the lung and the heart. This can be taught to neonatal trainees in two steps. The first step focuses on interpretation of ultrasound views on a high-fidelity ultrasound simulator. The second step is performing scans under the supervision of a trained neonatologist together with a pediatric radiologist until competency has been confirmed. This protocol should be considered as a screening exam as it is not yet validated in different neonatal diseases, which is the main limitation of our protocol; however, such projects are in the process of being completed.

Conclusion

Bedside evaluation of integrated LUS and FHUS can be a useful adjunct to clinical examination in infants at risk of respiratory or hemodynamic compromise, and can be taught to trainees over a short period.

Abbreviations

2-D:	2-dimensional ultrasound
AO:	aorta
AVCD:	atrio-ventricular canal defect
BPD:	bronchopulmonary dysplasia
DAO:	descending aorta
FHUS:	focused heart ultrasound
IVS:	interventricular septum
LA:	left atrium
LPA:	left pulmonary artery
LUS:	lung ultrasound
LV:	left ventricle
PA:	pulmonary artery
PDA:	patent ductus arteriosus
RA:	right atrium
RDS:	respiratory distress syndrome
RPA:	right pulmonary artery
RV:	right ventricle
TNE:	targeted neonatal echocardiography
TTN:	transient tachypnea of the newborn
VSD:	ventricular septal defect

Declaration of interest

The authors have no financial relationships to disclose, and no conflict of interest. Funding source: no funding was secured for this study.

References

1. Evans N, Gournay V, Cabanas F, Kluckow M, Leone T, Groves A, McNamara P, Mertens L. Point-of-care ultrasound in the neonatal intensive care unit: international perspectives. *Semin Fetal Neonatal Med.* 2011;16(1):61-8.
2. Xirouchaki N, Magkanas E, Vaporidi K, Kondili E, Plataki M, Patrianakos A, Akoumianaki E, Georgopoulos D. Lung ultrasound in critically ill patients: comparison with bedside chest radiography. *Intensive Care Med.* 2011;37(9):1488-93.
3. Rodríguez-Roisin R, Roca J. Mechanisms of hypoxemia. *Intensive Care Med.* 2005;31(8):1017-9.
4. Elsayed Y, Fraser D. Integrated Evaluation of Neonatal Hemodynamics Program Optimizing Organ Perfusion and Performance in Critically Ill Neonates, Part 1: Understanding Physiology of Neonatal Hemodynamics. *Neonatal Netw.* 2016;35(3):143-50.
5. Poets CF, Roberts RS, Schmidt B, Whyte RK, Asztalos EV, Bader D, Bairam A, Moddemann D, Peliowski A, Rabi Y, Solimano A, Nelson H; Canadian Oxygen Trial Investigators. Association Between Intermittent Hypoxemia or Bradycardia and Late Death or Disability in Extremely Preterm Infants. *JAMA.* 2015;314(6):595-603.
6. Liu J, Cao H-Y, Wang X-L, Xiao L-J. The significance and the necessity of routinely performing lung ultrasound in

- the neonatal intensive care units. *J Matern Neonatal Med.* 2016;7058:1-6.
7. Copetti R, Cattarossi L. Lung Ultrasound in Newborns, Infants, and Children. Chapter 13. In: Mathis G (Ed.). *Chest Sonography.* Berlin and Heidelberg: Springer-Verlag, 2011, pp. 241-5.
 8. Elsayed Y, Fraser D. Integrated Evaluation of Neonatal Hemodynamics, Part 2: Systematic Bedside Assessment. *Neonatal Netw.* 2016;35(4):192-203.
 9. El-Khuffash A, Herbozo C, Jain A, Lapointe A, McNamara PJ. Targeted neonatal echocardiography (TnECHO) service in a Canadian neonatal intensive care unit: a 4-year experience. *J Perinatol.* 2013;33:1-4.
 10. Brat R, Yousef N, Klifa R, Reynaud S, Shankar Aguilera S, De Luca D. Lung Ultrasonography Score to Evaluate Oxygenation and Surfactant Need in Neonates Treated With Continuous Positive Airway Pressure. *JAMA Pediatr.* 2015;169(8):e151797.
 11. Escourrou G, De Luca D. Lung ultrasound decreased radiation exposure in preterm infants in a neonatal intensive care unit. *Acta Paediatr.* 2016;105(5):e237-9.
 12. Raimondi F, Migliaro F, Sodano A, Umbaldo A, Romano A, Vallone G, Capasso L. Can neonatal lung ultrasound monitor fluid clearance and predict the need of respiratory support? *Crit Care.* 2012;16(6):R220.
 13. Santos TM, Franci D, Coutinho CMG, Ribeiro DL, Schweller M, Matos-Souza JR, Carvalho-Filho MA. A simplified ultrasound-based edema score to assess lung injury and clinical severity in septic patients. *Am J Emerg Med.* 2013;31(12):1656-60.
 14. Gardelli G, Feletti F, Nanni A, Mughetti M, Piraccini A, Zompatori M. Chest ultrasonography in the ICU. *Respir Care.* 2012;57(5):773-81.
 15. Wolff CB. Normal cardiac output, oxygen delivery and oxygen extraction. *Adv Exp Med Biol.* 2008;599:169-82.
 16. Azhan A, Wong FY. Challenges in understanding the impact of blood pressure management on cerebral oxygenation in the preterm brain. *Front Physiol.* 2012;3:471.
 17. Peterson AL, Deatsman S, Frommelt MA, Mussatto K, Frommelt PC. Correlation of echocardiographic markers and therapy in persistent pulmonary hypertension of the newborn. *Pediatr Cardiol.* 2009;30(2):160-5.
 18. Khositseth A, Nuntnarumit P, Chongkongkiat P. Echocardiographic parameters of patent ductus arteriosus in preterm infants. *Indian Pediatr.* 2011;48(10):773-8.
 19. Mourani PM, Abman SH. Pulmonary vascular disease in bronchopulmonary dysplasia: pulmonary hypertension and beyond. *Curr Opin Pediatr.* 2013;25:329-37.
 20. Tavera MC, Bassareo PP, Biddau R, Montis S, Neroni P, Tumbarello R. Role of echocardiography on the evaluation of patent ductus arteriosus in newborns. *J Matern Fetal Neonatal Med.* 2009;22(Suppl 3):10-3.
 21. Lichtenstein DA. Ultrasound examination of the lungs in the intensive care unit. *Pediatr Crit Care Med.* 2009;10(6):693-8.
 22. Bataille B, Riu B, Ferre F, Moussot PE, Mari A. Integrated Use of Bedside Lung Ultrasound and Echocardiography in Acute Respiratory Failure A Prospective Observational Study in ICU. *Chest.* 2014;146(6):1586-93.
 23. Mertens L, Seri I, Marek J, Arlettaz R, Barker P, McNamara P, Moon-Grady AJ, Coon PD, Noori S, Simpson J, Lai WW. Targeted Neonatal Echocardiography in the Neonatal Intensive Care Unit: Practice Guidelines and Recommendations for Training. *Eur J Echocardiogr.* 2011;12(10):715-36.