

Zika virus from a neonatologist's perspective

Anna Zylak, Sergio G. Golombek

The Regional Neonatal Center, Division of Newborn Medicine, Department of Pediatrics, Maria Fareri Children's Hospital at Westchester Medical Center, New York Medical College, Valhalla, NY, USA

Abstract

Zika virus has been known for more than half a century. Its clinical significance was just recently discovered, after the epidemic of Zika virus emerged in South and Central America. A task force established in 2015 by the Brazil Ministry of Health investigated the possible association between congenital Zika infection and microcephaly in fetuses and newborns. Since then more and more evidence emerged, supporting this hypothesis. The objective of this article is to review and summarize the currently available literature regarding Zika virus from a neonatologist's standpoint and provide some guidance to medical providers who may have to care for potentially exposed pregnant patients and their newborns.

Keywords

Zika virus, pregnancy, transmission, newborn, neonatal outcomes, microcephaly.

Corresponding author

Anna Zylak MD, FAAP, The Regional Neonatal Center, Division of Newborn Medicine, Department of Pediatrics, Maria Fareri Children's Hospital at Westchester Medical Center, New York Medical College, Valhalla, NY, USA; email: anna.zylak@wmchealth.org.

How to cite

Zylak A, Golombek SG. Zika virus from a neonatologist's perspective. *J Pediatr Neonat Individual Med*. 2017;6(1):e060128. doi: 10.7363/060128.

Introduction

Since January 2016 the topic of Zika virus (also known as ZIKV) infection has been constantly present in the headlines of the largest news agencies and the most famous medical journals. The suspected association between Zika virus infection and microcephaly in neonates raised the level

of anxiety especially in the population of pregnant women and their medical providers.

Background

Zika virus is a mosquito-borne RNA Flavivirus. There are 2 known lineages: an African and an Asian [1]. The virus was discovered by D.W.A. Dick for the first time in 1947, but not described in the literature until 1952. It was isolated from a febrile Rhesus monkey found in the Zika Forest (hence the name) in Uganda. The first documented human case was subsequently isolated in Nigeria in 1954 [2, 3]. Before 2007 only isolated human disease cases were reported from countries in Asia and Africa. In 2007 the first documented outbreak was reported in Yap State, Federated States of Micronesia, followed by outbreaks in Southeast Asia, the Western Pacific region and, most recently, in 2015 in Brazil [4]. On February 1, 2016, WHO has declared the problem of Zika virus infection a “Public Health Emergency of International Concern” [5]. The number of documented cases of Zika virus infection is constantly at the rise, both worldwide as well as on US territories [6, 7]. **Fig. 1** shows the countries worldwide with documented active Zika virus transmissions, as of September 23, 2016, as per CDC [8].

Transmission occurs most commonly via an insect vector [1]. There are 2 known vectors: *Aedes aegypti* also known as the Yellow fever mosquito; and *Aedes albopictus* – the Asian tiger mosquito. *Aedes aegypti* is the main vector and can also spread dengue fever, chikungunya, yellow fever viruses, and other diseases. It originated from Africa, but can also be found in most tropical and subtropical regions of the world (including: South and Central America, Asia and Polynesia). *Aedes albopictus* is more common in Asia, some regions of Europe and can also be found in North America. New research has shown that both species are capable of spreading in the United States further North as initially anticipated, hence posing a higher risk of infection transmission [1, 6, 9]. Some authors also hypothesize that there might be a genetic basis causing the evolution into new viral types with the enhanced ability to infect humans [10]. The recent epidemics also revealed other ways of transmission. It is known that the infection can be acquired transplacentally and intrapartum [11-13], via blood transfusions (no documented cases in the US, but suspected cases in Brazil) [13], as well as via sexual contact (the virus can be detected in semen for up to 2 weeks after the acute illness) [14]. Organ transplantation could potentially also pose a risk for transmission, although there are currently no known cases worldwide. An interesting issue is

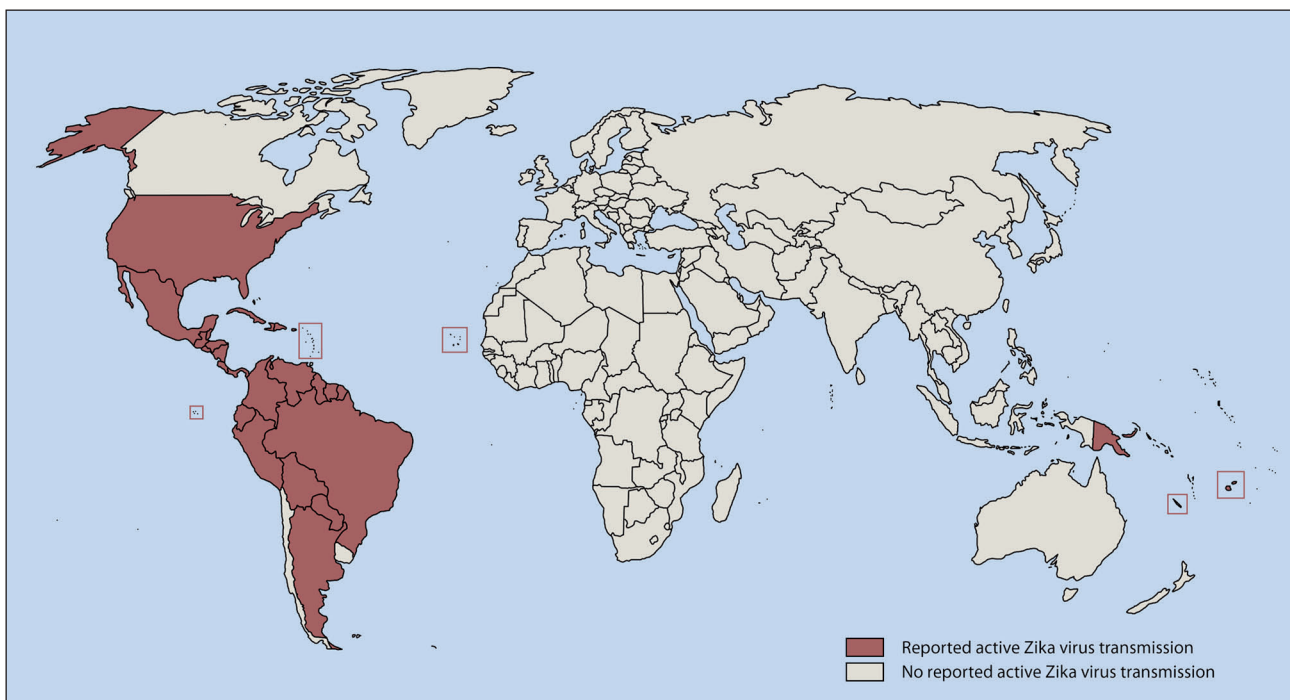


Figure 1. Zika virus (also known as ZIKV) reported active transmission as of September 23, 2016. Data are from the Centers for Disease Control and Prevention (CDC) [8].

also the risk of transmission via breastfeeding, the virus has been detected in breastmilk in 2 cases in Polynesia [15].

The majority of affected patients is asymptomatic (80%). The incubation period for Zika virus disease is still unknown, but is likely to be a few days to a week. Of those patients who present with symptoms, the most common complaints are very nonspecific: low-grade fever, maculopapular rash, arthralgia, non-purulent conjunctivitis, myalgia and headache. The illness is usually mild with symptoms lasting for several days to a week, rarely causing a severe sickness requiring medical attention in a hospital setting or causing death [16]. There are known cases in the literature of neurological complications associated with Zika virus infection. Both during the outbreak in French Polynesia in 2013-2014 and in Brazil in 2015 patients were presenting with symptoms resembling Guillain-Barré syndrome, an autoimmune disease characterized by ascending paralysis [17, 18].

There is currently no curative treatment available, and the management of Zika positive patients is based on supportive measures: hydration, analgesics and antipyretics. The key in decreasing the numbers of infected patients lies in prevention, mainly with personal protection, repellents, barrier contraception [1, 17]. In March 2016 the New York State Government suggested providing to health care providers “Zika Virus Protection Kits” containing repellents, condoms and larvicide tablets to treat standing water [19].

Pathogenesis of microcephaly and other anomalies due to Zika virus infection and hypothesis of causation

The clinical significance of a congenital Zika virus infection was discovered for the first time in 2015 in Brazil. In early 2015, an outbreak of Zika was identified in northeast Brazil. By September, reports of a 20-fold increase in the number of infants born with microcephaly in Zika-affected areas began to appear. Initially Zika RNA was identified from the amniotic fluid of 2 women whose fetuses were diagnosed with microcephaly. Subsequently more evidence emerged confirming the presence of Zika virus genetic material in newborn tissues obtained from neonates with microcephaly shortly after birth or after termination of pregnancy [17, 20-22].

Viral tropism of Zika to the brain has been known since 1952. Already back then, research

was suggesting that the virus can cross the blood-brain barrier. In mice models the virus infected both neurons and glia producing a variety of intracytoplasmic inclusions [2, 3]. Current studies also report the highest levels of viremia in samples obtained from the brain tissue of infected fetuses or neonates. One of the current hypothesis by Tetro [23] links the pathogenesis of Zika microcephaly with centrosome abnormalities. Centrosomes are involved in mitosis, migration, polarity and proper trafficking of vesicles. Abnormal function of these organelles can delay mitosis, increase apoptosis, cause improper neural stem cell orientation and premature neuronal differentiation, as well as decrease progenitor cells. By influencing all these processes, it can lead to reduction of brain formation subsequently causing a reduced brain size. After the epidemics in Brazil emerged, several animal studies were performed on mice to investigate the mode of transmission on a more cellular level. The investigators have found that Zika virus most likely preferentially injures the cortical neuronal progenitor cells [12]. The death of progenitor cells initiated by viral induced inflammation could explain the brain malformations, microcephaly and cortical thinning. Other authors hypothesize that there are strong similarities between Zika virus infection and hypervitaminosis A, a known *in utero* teratogen. In the model described by Mawson [24], an early infection with the virus activates a retinoic cascade in the liver resulting in an increased production of retinoic acid. Elevated retinoic acids levels cause cholestatic liver damage and then subsequently neuronal apoptosis and necrosis, leading to growth restriction, microcephaly and ophthalmologic defects. Rasmussen [25] published an interesting analysis reviewing the association between prenatal Zika infection, microcephaly and other brain abnormalities. By applying specific criteria for the evaluation of potential teratogens (also known as Bradford Hill criteria) on all available evidence they concluded that there is sufficient evidence supporting the causal relationship between congenital Zika virus infection and microcephaly.

Birth defects associated with congenital Zika virus infection

Besides brain abnormalities (microcephaly, ventriculomegaly, intracranial calcifications, neuronal migration disorders, lissencephaly, pachygyria, corpus callosum dysgenesis) [20-22,

26-29] and eye abnormalities (microphthalmia, focal pigment mottling of the retina, chorioretinal atrophy, optic nerve abnormalities, cataracts, eye asymmetry, intraocular calcifications, macular atrophy, lens subluxation) [24, 30], congenital Zika virus infection can be also associated with congenital contractures, arthrogryposis and club feet [26]. Additionally, growth restriction was noted in the affected fetuses and neonates, raising the suspicion of abnormal placental development or placental insufficiency caused by Zika virus infection [12, 22]. The relationship between the timing of the acute maternal infection and the subsequent fetal abnormalities still remains unknown. Some studies suggest a 1% chance of developing microcephaly if the Zika virus infection and subsequent insult occurred during the first trimester of pregnancy. This theory corresponds with the known fact, that the most crucial stages of brain development occur during that time. Stillbirth has been associated with acute viral infection late in pregnancy [29].

Diagnostic approach and management in suspected neonatal cases of Zika virus infection

The CDC guidelines recommend testing of pregnant women with a possible exposure to Zika virus. Tests can be performed on both serum and amniotic fluid – one must remember though the risks of amniocentesis itself, which can result in fetal loss in about 0.1% of cases [31]. Additionally, it is still not known how sensitive and specific the available testing is and if a positive result is actually predictive of a subsequent fetal abnormality. The currently available diagnostic opportunities include PCR testing for viral RNA, detection of Zika virus-specific IgM antibodies using ELISA and plaque reduction neutralization test (PRNT) for Zika antibodies. Viral RNA can be detected during the first 7 days of illness, after that the level of viremia decreases. During that period, molecular testing is recommended. However, a negative RT-PCR performed on days 5-7 of the acute illness does not exclude Zika virus infection and should be verified with serological testing. Zika virus-specific IgM antibodies might be detected as early as on the 4th day of the acute illness and they can persist 2-12 weeks. However, serum collected within the first 7 days might not detect specific Zika virus antibodies. Hence it is recommended to postpone serologic testing until after 7 days of illness. Cross reactivity might occur between Zika virus antibodies and antibodies against

other *Flaviviridae* (especially with the increasing numbers of tourists being vaccinated for Yellow Fever or Japanese Encephalitis), hence every positive antibody test should be confirmed with a plaque-reduction neutralization test (PRNT). A 4-fold or higher increase in specific Zika virus antibody titers is considered positive [26, 32]. In the case of a positive Zika test as per CDC serial ultrasound examinations should be considered to monitor fetal growth and anatomy every 3-4 weeks. The pregnant woman should be referred to a Maternal Fetal Medicine and Infectious Diseases specialist. After delivery histopathologic examination of the placenta and umbilical cord is recommended, as well as testing of frozen placental tissue and cord tissues for Zika virus RNA and testing of cord serum for Zika and dengue virus IgM along with neutralizing antibodies. In the situation of a fetal loss due to suspected Zika infection, CDC also highly recommends Zika virus PCR testing and immunohistochemical staining to be performed on the fetal tissues, including umbilical cord and placenta. Zika testing is also recommended for infants with microcephaly or intracranial calcifications born to women who traveled to or resided in areas with Zika virus transmission while being pregnant as well as for infants born to mothers with a positive or inconclusive test results for Zika virus infection. A thorough physical exam should be performed in all cases of suspected congenital Zika infection, including an evaluation for neurologic abnormalities, dysmorphic features, splenomegaly, hepatomegaly, and rash or other skin lesions; a hearing evaluation and an ophthalmologic evaluation. Laboratory testing for infants includes: serum samples from the umbilical cord or directly from the baby within 2 days after birth; CSF if clinically warranted; frozen and fixed placenta tissue. All cases of confirmed Zika infection should be reported to the state, territorial, or local health department and should be monitored for additional guidance as it is released. Additional hearing screen should be conducted at age 6 months, due to the possibility of co-occurrence of CMV infection. Providers should carefully evaluate occipito-frontal circumference and developmental milestones at every well child visit [6, 26, 31, 33]. Although the virus has been detected in breastmilk in the past in 2 cases in Polynesia, WHO still recommends breastfeeding, possibly attributing the infection not directly to breastfeeding but to close contact between the mother and the infant [15].

Conclusions

What are our hopes for the future? Some experts are hoping that the Zika virus will behave similarly to rubella: most of the population gets it and subsequently most of the population becomes immune. Nevertheless, several research labs are currently working on developing a vaccine, which should soon enter the first phase of clinical trials [34, 35].

Declaration of interest

The Authors declare that there is no conflict of interest. The Authors report no funding for this publication.

References

- Higgs S. Zika Virus: Emergence and Emergency. *Vector Borne Zoonotic Dis.* 2016;16(2):75-6.
- Dick GW, Kitchen SF, Haddow AJ. Zika virus. I. Isolations and serological specificity. *Trans R Soc Trop Med Hyg.* 1952;46(5):509-20.
- Dick GW. Zika virus. II. Pathogenicity and physical properties. *Trans R Soc Trop Med Hyg.* 1952;46(5):521-34.
- Tetro J. Zika virus: the making of an epidemic. Available at: <http://www.popsci.com/zika-virus-making-an-epidemic>, last access: July 2016.
- <http://www.who.int/mediacentre/news/statements/2016/1st-emergency-committee-zika/en/>, last access: July 2016.
- <https://www.cdc.gov/zika/>, last access: August 2016.
- Dasti JI. Zika virus infections: An overview of current scenario. *Asian Pac J Trop Med.* 2016;9(7):621-5.
- <http://www.cdc.gov/zika/geo/active-countries.html>, last access: October 2016.
- Calvez E, Guillaumot L, Millet L, Marie J, Bossin H, Rama V, Faamoe A, Kilama S, Teurlai M, Mathieu-Daudé F, Dupont-Rouzeyrol M. Genetic Diversity and Phylogeny of *Aedes aegypti*, the Main Arbovirus Vector in the Pacific. *PLoS Negl Trop Dis.* 2016;10(1):e0004374.
- Panchaud A, Stojanov M, Ammerdorffer A, Vouga M, Baud D. Emerging Role of Zika Virus in Adverse Fetal and Neonatal Outcomes. *Clin Microbiol Rev.* 2016;29(3):659-94.
- Besnard M, Lastere S, Teissier A, Cao-Lormeau V, Musso D. Evidence of perinatal transmission of Zika virus, French Polynesia, December 2013 and February 2014. *Euro Surveill.* 2014;19(13):pii=20751.
- Mysorekar IU, Diamond MS. Modeling Zika Virus Infection in Pregnancy. *N Engl J Med.* 2016;375:481-4.
- Marrs C, Olson G, Saade G, Hankins G, Wen T, Patel J, Weaver S. Zika Virus and Pregnancy: A Review of the Literature and Clinical Considerations. *Am J Perinatol.* 2016;33(7):625-39.
- Oster AM, Russell K, Stryker JE, Friedman A, Kachur RE, Petersen EE, Jamieson DJ, Cohn AC, Brooks JT. Update: Interim Guidance for Prevention of Sexual Transmission of Zika Virus — United States, July 2016. *MMWR Morb Mortal Wkly Rep.* 2016;65(12):323-5.
- http://www.ncbi.nlm.nih.gov/books/NBK374155/pdf/Bookshelf_NBK374155.pdf, last access: July 25, 2016.
- Hennessey M, Fischer M, Staples JE. Zika Virus Spreads to New Areas – Region of the Americas, May 2015-January 2016. *MMWR Morb Mortal Wkly Rep.* 2016;65(3):55-8.
- <http://ecdc.europa.eu/en/publications/Publications/zika-virus-rapid-risk-assessment-11-april-2016.docx.pdf>, last access: July 25, 2016.
- Oehler E, Watrin L, Larre P, Leparc-Goffart I, Lastere S, Valour F, Baudouin L, Mallet H, Musso D, Ghawche F. Zika virus infection complicated by Guillain-Barre syndrome – case report, French Polynesia, December 2013. *Euro Surveill.* 2014;19(9):pii=20720.
- <https://www.smartbrief.com/servlet/ArchiveServlet?issueid=6215D33D-59E8-4C85-BCD2-D428FE22B19B&Imid=archives>, last access: 2016.
- Schuler-Faccini L, Ribeiro EM, Feitosa IM, Horovitz DD, Cavalcanti DP, Pessoa A, Doriqui MJ, Neri JI, Neto JM, Wanderley HY, Cernach M, El-Husny AS, Pone MV, Seroo CL, Sanseverino MT; Brazilian Medical Genetics Society – Zika Embryopathy Task Force. Possible Association Between Zika Virus Infection and Microcephaly – Brazil, 2015. *MMWR Morb Mortal Wkly Rep.* 2016;65(3):59-62.
- Cauchemez S, Besnard M, Bompard P, Dub T, Guillemette-Artur P, Eyrolle-Guignot D, Salje H, Van Kerkhove MD, Abadie V, Garel C, Fontanet A, Mallet HP. Association between Zika virus and microcephaly in French Polynesia, 2013-15: a retrospective study. *Lancet.* 2016;387(10033):2125-32.
- Brasil P, Pereira JP Jr, Raja Gabaglia C, Damasceno L, Wakimoto M, Ribeiro Nogueira RM, Carvalho de Sequeira P, Machado Siqueira A, Abreu de Carvalho LM, Cotrim da Cunha D, Calvet GA, Neves ES, Moreira ME, Rodrigues Baião AE, Nassar de Carvalho PR, Janzen C, Valderramos SG, Cherry JD, Bispo de Filippis AM, Nielsen-Saines K. Zika Virus Infection in Pregnant Women in Rio de Janeiro – Preliminary Report. *N Engl J Med.* 2016 Mar 4. [Epub ahead of print].
- Tetro JA. Zika and microcephaly: causation, correlation, or coincidence? *Microbes Infect.* 2016;18(3):167-8.
- Mawson AR. Pathogenesis of Zika Virus-Associated Embryopathy. *Biores Open Access.* 2016;5(1):171-6.
- Rasmussen SA, Jamieson DJ, Honein MA, Petersen LR. Zika Virus and Birth Defects — Reviewing the Evidence for Causality. *N Engl J Med.* 2016;374:1981-7.
- Staples JE, Dziuban EJ, Fischer M, Cragan JD, Rasmussen SA, Cannon MJ, Frey MT, Renquist CM, Lanciotti RS, Muñoz JL, Powers AM, Honein MA, Moore CA. Interim Guidelines for the Evaluation and Testing of Infants with Possible Congenital Zika Virus Infection – United States, 2016. *MMWR Morb Mortal Wkly Rep.* 2016;65(3):63-7.

27. Oliveira Melo AS, Malinger G, Ximenes R, Szejnfeld PO, Alves Sampaio S, Bispo de Filippis AM. Zika virus intrauterine infection causes fetal brain abnormality and microcephaly: tip of the iceberg? *Ultrasound Obstet Gynecol.* 2016;47(1):6-7.
28. Rodrigues LC. Microcephaly and Zika virus infection. *Lancet.* 2016;387(10033):2070-2.
29. Moron AF, Cavalheiro S, Milani H, Sarmento S, Tanuri C, de Souza FF, Richtmann R, Witkin SS. Microcephaly associated with maternal Zika virus infection. *BJOG.* 2016;123(8):1265-9.
30. Ventura CV, Maia M, Bravo-Filho V, Góis AL, Belfort R Jr. Zika virus in Brazil and macular atrophy in a child with microcephaly. *Lancet.* 2016;387(10015):228.
31. Petersen EE, Staples JE, Meaney-Delman D, Fischer M, Ellington SR, Callaghan WM, Jamieson DJ. Interim Guidelines for Pregnant Women During a Zika Virus Outbreak – United States, 2016. *MMWR Morb Mortal Wkly Rep.* 2016;65(2):30-3.
32. http://www.aphl.org/materials/CDCMemo_Zika_Chik_Deng_Testing_011916.pdf, last access: July 2016.
33. Torjesen I. Zika virus outbreaks prompt warnings to pregnant women. *BMJ.* 2016;352:i500.
34. Larocca RA, Abbink P, Peron JP, Zanotto PM, Iampietro MJ, Badamchi-Zadeh A, Boyd M, Ng'ang'a D, Kirilova M, Nityanandam R, Mercado NB, Li Z, Moseley ET, Bricault CA, Borducchi EN, Giglio PB, Jetton D, Neubauer G, Nkolola JP, Maxfield LF, Barrera RA, Jarman RG, Eckels KH, Michael NL, Thomas SJ, Barouch DH. Vaccine protection against Zika virus from Brazil. *Nature.* 2016 Jun 28. [Epub ahead of print].
35. Bogoch II, Brady OJ, Kraemer MU, German M, Creatore MI, Kulkarni MA, Brownstein JS, Mekaru SR, Hay SI, Groot E, Watts A, Khan K. Anticipating the international spread of Zika virus from Brazil. *Lancet.* 2016;387(10016):335-6.