

Manual ward reduction of gastroschisis without anesthesia, a safe procedure – 8 years experience

Kamal Nain Rattan¹, Pallavi Sonika², Richa Singh², Kuldeep Yadav², Dayanand Hota²

¹Department of Pediatric Surgery, PGIMS, Rohtak, Haryana, India

²Department of Pediatrics, PGIMS, Rohtak, Haryana, India

Abstract

Introduction: Gastroschisis is the most common type of abdominal wall defect at birth. Various modalities of treatment have been proposed ranging from primary closure to the staged closure using prosthetic materials under general anesthesia. One of the modalities is manual ward reduction with primary repair of gastroschisis without anesthesia. We are reporting our 8 years of experience with manual ward reduction of gastroschisis with primary repair without anesthesia.

Materials and methods: It is a retrospective analysis of all patients of gastroschisis who presented in our institution from January 2008 to June 2016. The data were analyzed for antenatal diagnosis, sex, day of presentation, weight of baby, associated anomalies, management by manual reduction without anesthesia and post reduction morbidity and mortality.

Results: Out of a total of 68 patients, 28 were females and 40 were males. Fifty-five cases (80.8%) were antenatally diagnosed. Fifty-nine patients (86.7%) presented within 24 hours of birth while the rest had delayed presentation. Preterms (< 37 weeks) were 18 (26.4%). Cases of simple gastroschisis were 22 while those complicated were 46. The average birth weight was 1.88 kg with the lowest weight of 1 kg who was a 27-week preterm. In 60 patients (88.2%), bedside manual reduction without anesthesia and primary closure was possible while in 8 patients it could not be done owing to delayed presentation and complications. The mortality in these patients was 40%.

Conclusion: Manual reduction and primary closure of gastroschisis without anesthesia is a safe procedure. It requires no ventilator support and can be managed with antibiotics, total parenteral nutrition (TPN) and continuous positive airway pressure (CPAP) in the post-reduction period.

Keywords

Gastroschisis, manual reduction, neonates.

Corresponding author

Kamal Nain Rattan, Senior Professor and Head, Department of Pediatric Surgery, PGIMS, Rohtak, Haryana, India 124001; email: knrattan@gmail.com.

How to cite

Rattan KN, Sonika P, Singh R, Yadav K, Hota D. Manual ward reduction of gastroschisis without anesthesia, a safe procedure – 8 years experience. J Pediatr Neonat Individual Med. 2017;6(1):e060112. doi: 10.7363/060112.

Introduction

Gastroschisis is an anterior abdominal wall defect present at birth, almost always on the right side and is lateral to the intact cord. The size of the defect is usually 3-4 cm. The herniated contents include intestines, stomach and may also contain liver and gallbladder. The contents are not enclosed in a peritoneal sac. The defect results from rupture at the base of the umbilical cord in an area weakened by involution of the right umbilical vein. Incidence reported from various studies varies from 0.4 to 11.7% cases per 10,000 newborns [1]. Gastroschisis can be simple or complicated. Simple gastroschisis consists of intact bowel loops with no breach, while the complicated form consists of bowel loops with edema, necrosis, perforation, stenosis or volvulus.

Surgical treatment includes reduction of herniated contents into the bowel cavity followed by primary closure whenever possible or the staged repair if the abdominal cavity is small. The first surgical intervention by manual closure with fatal outcome was reported in 1878. The first successful primary closure of gastroschisis was reported by Watkins in 1943. Moor and Stokes reported the use of the skin flap technique in 1953. In 1967, Schuster made a major conceptual advance in surgical treatment by using Teflon sheets sewn to the abdominal wall. But this procedure involved the risk of bowel injury and infectious complications. Allen and Wrenn used Silastic instead of Teflon [2]. But owing to various risks, primary closure remained the procedure of choice until 1980. After that, staged repair using silo became the preferred method because mortality was high with primary closure. But this procedure was associated with longer ICU stays and led to increased complications

associated with late onset sepsis and increased time to initiate enteral nutrition. In 1998, Bianchi and Dickson performed bedside reduction and closure without anesthesia and found this to be associated with fewer complications and better survival [3].

Materials and methods

This is a retrospective study which includes the data of cases of gastroschisis admitted from January 2008 to June 2016. The data were analyzed for antenatal diagnosis, sex, day of presentation, weight of baby, associated anomalies, management by manual reduction without anesthesia and post reduction morbidity and mortality.

Results

During the study period of 8 years, 68 patients presenting gastroschisis were admitted to our institute (**Fig. 1**). Fifty-five cases (80.8%) were antenatally diagnosed. Fifty-nine patients (86.7%) presented within 24 hours of birth while 9 patients had delayed presentation after 24 hours of birth. Forty patients were male and 28 patients were female. The number of preterms (< 37 weeks) were 18 (26.4%). Average birth weight was 1.88 kg and the lowest weight was 1 kg. Those with simple gastroschisis were 22 while the complicated cases were 46. Manual reduction with primary closure was possible

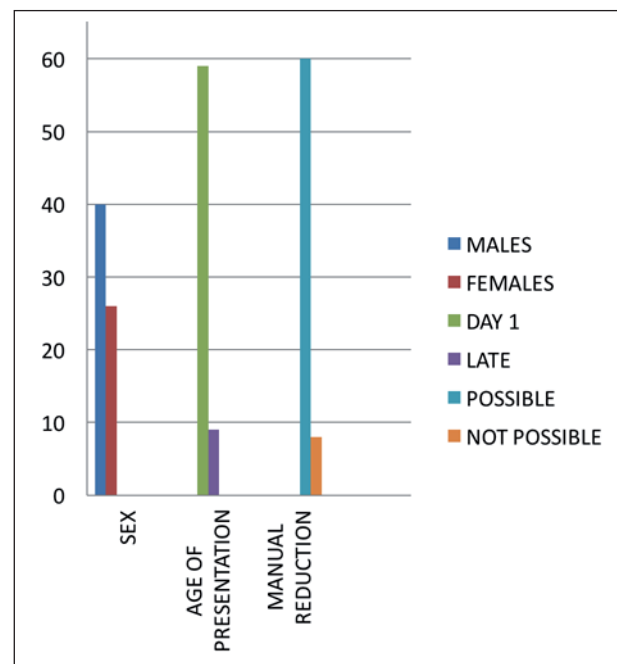


Figure 1. Characteristics of patients presenting gastroschisis who were admitted to our institute.

in 60 patients (88%). In 8 patients manual reduction and primary closure could not be performed owing to associated complications such as massive edema of the gut, volvulus, gangrene of the gut or when the herniated contents contained other organs such as liver, gallbladder, etc. Associated anomalies are rare with gastroschisis: 3 patients presented ileal atresia and 4 patients had Meckel's diverticulum.

Surgical technique

After admission of the neonate, the bowel loops were washed with saline and covered with a warm saline soaked gauze piece. After initial stabilization, a nasogastric tube was placed and the stomach decompressed. Under all aseptic precautions, after assessing the bowel cavity, the gut was gradually

reduced loop by loop (**Figures 2-7**). After complete reduction of the gut, the wall defect was closed in one layer. During reduction, in some patients the abdominal cavity was stretched so that the bowel could be accommodated. The procedure usually took 5 to 20 minutes. Passage of the meconium during the procedure is a good prognostic sign and rules out distal atresia of the gut.

In cases where the defect size was small, a small lateral incision was made under local anesthesia to facilitate the reduction.

In 2 cases the gut was ischemic and friable, so during reduction the perforation of gut occurred. The gut was reduced and the perforated end was brought as ileostomy. In one case, there was no distal atresia and the ileostomy closed spontaneously. In the other case, the child died due to sepsis.

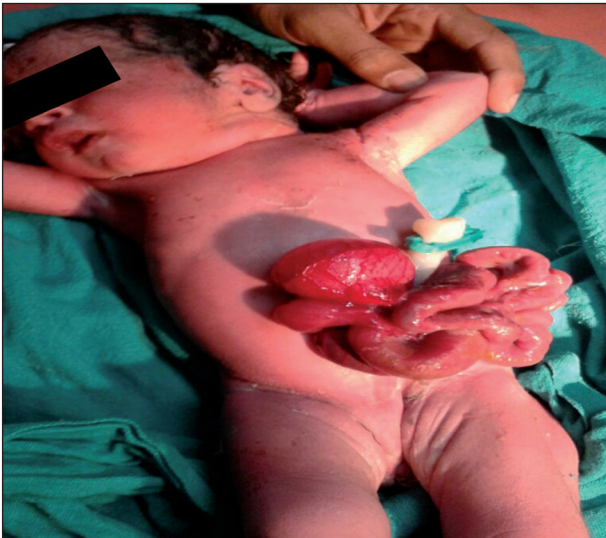

Figure 2. Simple gastroschisis with healthy gut.

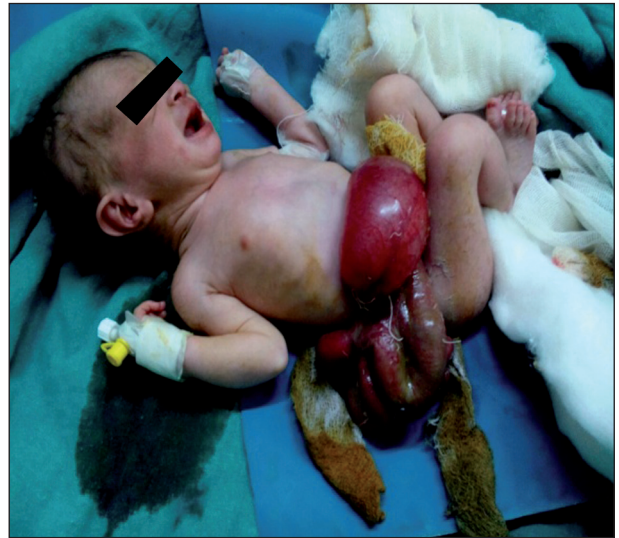

Figure 3. Complicated gastroschisis showing edematous gut.

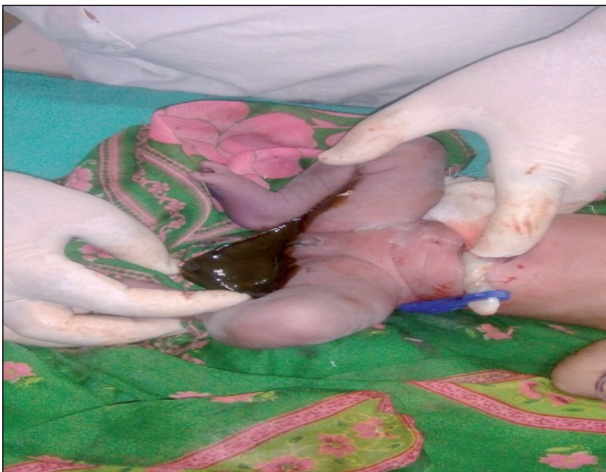

Figure 4. Passage of meconium during the procedure.

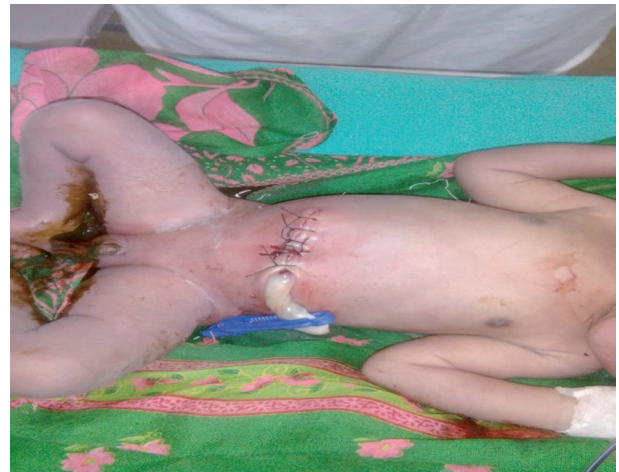

Figure 5. After reduction.

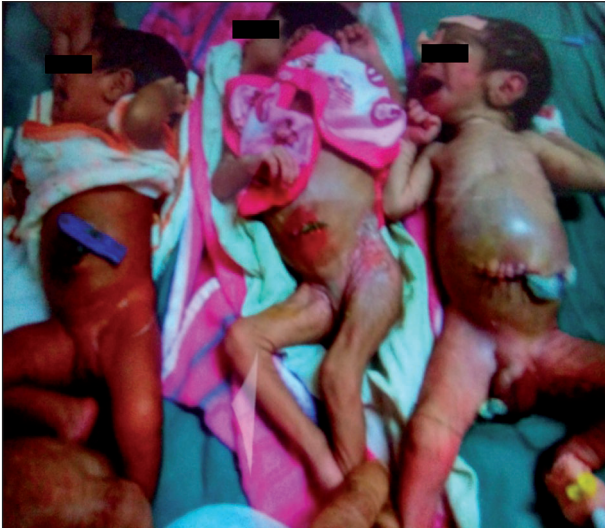

Figure 6. After reduction.

Owing to delayed presentation, in 8 patients the prolapsed gut was massively edematous and gangrenous and thus it was not possible to reduce the contents and perform primary closure. A staged procedure was adopted but patients died due to severe sepsis.

In one case the defect was on the left side which was also managed with manual reduction and primary closure without general anesthesia.

After the procedure, the infant was put on intravenous (IV) fluids, total parenteral nutrition (TPN) and IV antibiotics. After 7-8 days from procedure, once the child has passed stool and there were minimal nasogastric aspirates, the child was given feeds orally. The patient was discharged 10-14 days after the procedure. Stitches were removed after 14 days. Post procedure mortality was 40%, which was mainly due to septicemia.

Discussion

Gastroschisis is an anterior wall defect more common than omphalocele. Associated anomalies are more common with omphalocele than gastroschisis.

The lateral body folds fuse in the midline during the fourth week of development to form the anterior abdominal wall. A defect may result from incomplete fusion and the bowel herniates out, typically lying to the right of the umbilicus.

The management of neonates with gastroschisis depends on factors such as the amount of herniated bowel, size of abdominal cavity, age of presentation, associated anomalies. Prenatal diagnosis helps

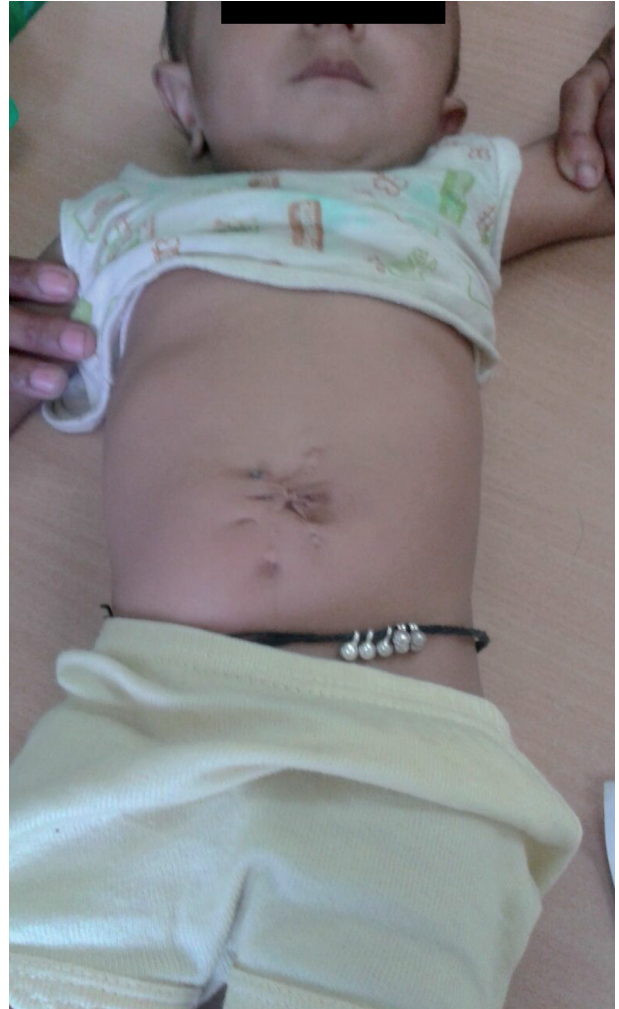

Figure 7. Patient at 6 months of age.

in transferring patients to tertiary care hospitals thus favoring early reduction, fewer ventilator requirements and complications. Reduction of the gut should be performed as early as possible to prevent loss of heat and water from the exposed bowel. Early reduction also decreases the risk of bowel edema, infarction, necrosis and sepsis.

In 1998, Bianchi and Dickson published a series of 14 cases, where bedside reduction was executed. Of these, 12 survived without anesthesia. They used umbilical cord sutured to rectus sheath to cover the defect and concluded that minimal interventional management of gastroschisis is safe [3]. In the index study, the procedure was performed without anesthesia and was safe in all cases. Kimble et al. reported the largest series of 35 infants and was able to perform ward reduction without anesthesia and ventilation in 29 infants [4]. In our study, we were able to perform ward reduction and closure without anesthesia and ventilation in 60 patients out of 68 (88%).

In our study, none of the patients required mechanical ventilation post procedure and could easily be managed on TPN and IV antibiotics. In his retrospective study, Davies compared in-ward reduction and repair under GA in 31 patients and concluded that in-ward reduction avoided ventilation in 62% of cases [5]. Dhiraj et al., in their retrospective analysis of 5 cases, concluded that primary closure of gastroschisis without anesthesia is a safe procedure and the infants were established on full feeds earlier and were discharged home significantly earlier than in the staged repair [6].

Eggink et al. also concluded that patients who underwent staged repair were ventilated longer after birth as compared with those who underwent primary closure. Patients managed with staged repair took significantly longer to reach full feeds and there was a trend of starting feeds later [7]. Patrick et al. also preferred primary closure as the procedure of choice as it avoided paralysis and required minimal sedation leading to shorter hospital stay [8].

Although staged repair with preformed silo is the preferred method at various institutes, it does have potential side-effects such as ischemic complications, dislodgement, bowel twisting, prolonged ileus, need for more surgery and difficulties with final closure [9].

Mortality in our patients was slightly higher (40%), and more so in complicated cases where primary repair was not possible. The important risk factors were septicemia, prematurity, low birth weight and associated defects.

Conclusion

Gastroschisis is a common anterior abdominal wall defect. Early presentation favors manual

reduction and primary closure which is a safe procedure and can be performed bedside without the need for general anesthesia and ventilator support.

Declaration of interest

The Authors declare that there is no conflict of interest.

References

1. Méndez-Martínez S, García-Carrasco M, Mendoza-Pinto C, García-Cano E, Montiel-Jarquín Á. Surgical complications of simple and complex gastroschisis in newborns. *Eur J Med.* 2016;13(2):88-93.
2. Hashish AAE, Elhalaby E. Evolution of management of gastroschisis. *Ann Pediatr Surg.* 2011;7:10-5.
3. Bianchi A, Dickson AP. Elective delayed reduction and no anesthesia 'minimal intervention management' for gastroschisis. *J Pediatr Surg.* 1998;33:1338-40.
4. Kimble RM, Singh SJ, Bourke C, Cass DT. Gastroschisis reduction under analgesia in the neonatal unit. *J Pediatr Surg.* 2001;36:1672-4.
5. Davies MW, Kimble RM, Cartwright DW. Gastroschisis: ward reduction compared with traditional reduction under general anesthesia. *J Pediatr Surg.* 2005;40(3):523-27.
6. Parihar D, Goel N, Raikwar P, Batra APS, Kaur J, Nandi S. Early primary repair of gastroschisis without general anesthesia. *J Evol Med Dental Sci.* 2015;4(98):16292-94.
7. Eggink BH, Richardson CJ, Malloy MH, Angel CA. Outcome of gastroschisis: A 20 years case review of infants with gastroschisis born in Galveston, Texas. *J Pediatr Surg.* 2006;41(6):1103-8.
8. Chesley PM, Ledbetter DJ, Meehan JJ, Oron AP. Contemporary trends in the use of primary repair for gastroschisis in surgical infants. *Am J Surg.* 2015;209(5):901-6.
9. Ionescu S, Andrei B, Tirlea S, Bunea BM, Licsandru E, Cirstoveanu C, Bizubac M, Ivanov M, Shelleh M, Gurita A, Tabacaru R. Considerations on gastroschisis repair. *Chirurgia (Bucur).* 2013;108:509-15.