

# *S. marcescens* sepsis with brain involvement: a fatal outcome

Sofia Aires, Simão Frutuoso, Carmen Carvalho

Neonatal Intensive Care Unit, Centro Hospitalar do Porto, Porto, Portugal

## Abstract

A growth restricted 30-week premature girl was admitted to the Neonatal Intensive Care Unit (NICU) with respiratory distress. In spite of a favorable respiratory evolution, she had a nosocomial sepsis at day 18. She was initially started on gentamicin and vancomycin, and then switched to meropenem due to clinical deterioration and a positive blood culture for *S. marcescens*. Brain ultrasound, initially only with a transitory periventricular echodensity, showed several echogenic foci throughout all parenchyma, strongly suggesting brain abscess. Hemodynamic and neurologic worsening ensued with a fatal outcome on day 21. *S. marcescens* is a Gram-negative bacterium frequently associated with infections. The occurrence of brain involvement, with abscess formation, greatly worsens the prognosis. This case report illustrates the severity of neonatal sepsis by *Serratia spp.*, documented by extensive brain involvement leading to a fatal outcome, despite a prompt and adequate therapy.

## Keywords

Meningitis, neonatal, sepsis, *Serratia*.

## Corresponding author

Sofia Aires, Neonatal Intensive Care Unit, Centro Hospitalar do Porto, Porto, Portugal; email: sofiaires@gmail.com.

## How to cite

Aires S, Frutuoso S, Carvalho C. *S. marcescens* sepsis with brain involvement: a fatal outcome. J Pediatr Neonat Individual Med. 2016;5(1):e050137. doi: 10.7363/050137.

## Introduction

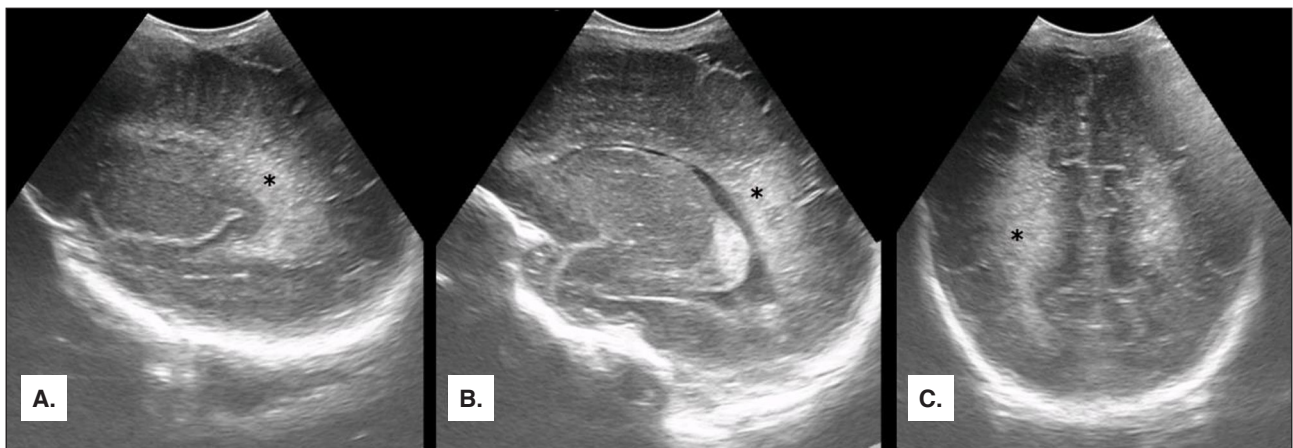
Bacterial sepsis in the newborn frequently evolves with meningitis, sometimes being difficult to distinguish one from the other in this setting. First signs of brain involvement are usually irritability or lethargy [1, 2]. In the

last decade, with availability of new antibiotics, significant progress was made in reducing mortality. Still, the disease remains devastating with high morbidity and mortality [1, 3].

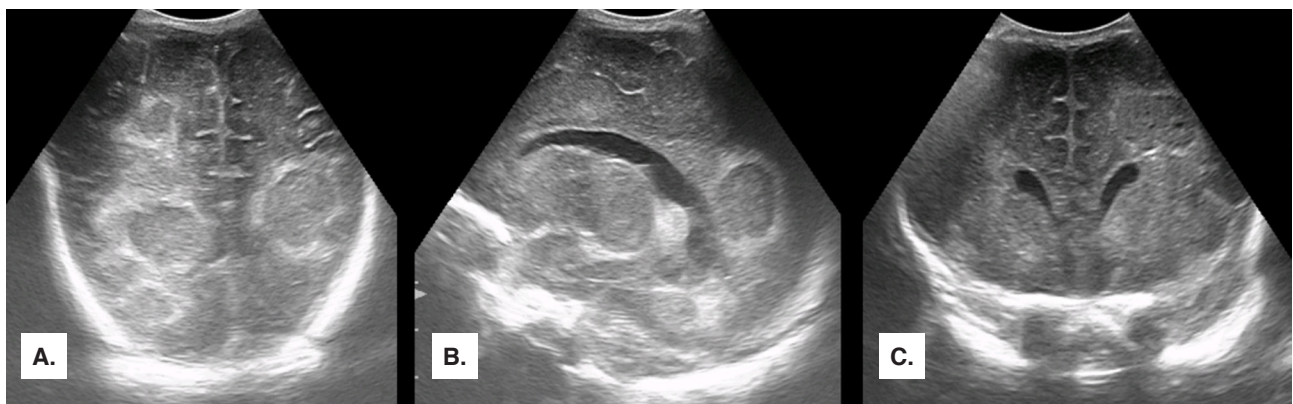
### Case report

A twin pregnancy was complicated with intrauterine growth restriction and pathological umbilical artery flow pattern that led to a cesarean section at 30 weeks of gestation. Good adaptation to the extrauterine life with 1<sup>st</sup> minute and 5<sup>th</sup> minute Apgar score 8 and 10, respectively. Birth weight: 1,400 grams (appropriate to gestational age). She presented with respiratory distress requiring non-invasive ventilation for ten days. Initial cerebral ultrasonography (**Fig. 1**) revealed periventricular echodensities that disappeared in the next few days.

Brain ultrasound on day 17 was normal. She had an epicutaneous-cava catheter since admission in the NICU. On day 18 she developed clinical signs of sepsis and, in spite of having negative reactive C protein, she was started on vancomycin (15 mg/kg every 12 hours) and gentamicin (4 mg/kg every 36 hours). Thirty-six hours later, due to clinical deterioration with irritability and positive blood culture for *S. marcescens* (sensitive to gentamicin and carbapenem), meropenem was started (40 mg/kg every 8 hours) (reactive C protein 62 mg/dl). Since day 20 her condition worsened, with periods of increased irritability and great hemodynamic instability. Meanwhile, brain ultrasound changed dramatically, revealing multiple parenchymal echogenic foci (2 x 2 cm), strongly suggestive of bacterial encephalitis complicated with brain abscesses (**Fig. 2**). Hemodynamic and neurological



**Figure 1.** Periventricular hyperechogenicity on day 2 of life (marked with \*). **A** and **B.** Right parasagittal plans. **C.** Posterior coronal plane.



**Figure 2.** Echographic images on day 21 indicative of brain abscesses. **A.** Image obtained in a posterior coronal section showing 3 abscesses on the right side, being the middle one larger than the other 2, and one abscess on the left side. **B.** Image obtained in a right sagittal section, showing an abscess posterior to the trigone of the lateral ventricle and another smaller one below. **C.** Image obtained in an anterior coronal section showing one abscess on the left side, above and lateral to the frontal horn of the left ventricle.

deterioration ensued, leading to death on day 21. The parents refused autopsy.

## Discussion

*S. marcescens* is a Gram-negative bacillus, of the Enterobacteriaceae family, sometimes responsible for NICU outbreaks. It is usually acquired from contact with environmental elements like water, soil, plants or animals, however in more than half of cases the source remains unknown. It is not a common device-related infection pathogen. The most usual clinical scenario includes eye and urinary infections, sepsis and pneumonia. Cerebral infections due to *S. marcescens* are frequently linked with prior cerebral instrumentation like central nervous system surgeries or simply a lumbar puncture, which was not the case, and has an increased risk of brain abscesses [4]. This was the first case of *S. marcescens* sepsis in our NICU.

*Serratia spp.* is usually susceptible to aminoglycosides, third and fourth generation cephalosporin and carbapenems [4]. Although the patient was initially treated with gentamicin, once the blood culture results were known, antibiotic therapy was promptly switched to meropenem, intended to last for 21 days or 14 days after cerebrospinal fluid sterilization as it is recommended in literature [4, 5]. In this case, brain abscesses were documented very early in the course of sepsis, although some literature refers to a latter onset of their formation [6].

Ultrasound is the best and the most readily available technic of neonatal brain imaging. This is particularly true in the NICU setting, with critically ill and instable babies that cannot be submitted to magnetic resonance imaging, though that would be, no doubt about it, extremely informative [6]. Unfortunately, this patient did not survive to allow for those suggestive ultrasound images to be confirmed by magnetic resonance to be (or not) brain abscesses.

Beside abscess formation, acute complications of neonatal bacterial meningitis include cerebral edema with increased intracranial pressure, ven-

triculitis, cerebritis, hydrocephalus and subdural effusion or empyema [1, 5, 7].

Meningoencephalitis in neonates, especially when associated with cerebral abscess, Gram-negative bacteria or very low birth weight, has a poor prognosis, associated with seizures, cerebral palsy, cognitive impairment or death [1, 5, 7, 8].

## Conclusion

Neonatal bacterial meningitis is still an important cause of mortality and morbidity, requiring early diagnosis and quick start of adequate treatment. This case report intends to remind the severity of neonatal sepsis by *S. marcescens*, documented by extensive and fulminant brain involvement leading to a rapid and fatal outcome.

## Declaration of interest

The Authors declare that there is no conflict of interest.

## References

1. Bentlin MR, Rugolo LMSS. Late-onset sepsis: epidemiology, evaluation and outcome. *NeoReviews*. 2010;11(8):e426-35.
2. Stallworth L, Mani C, Murray D. Index of suspicion in the nursery. *NeoReviews*. 2005;6(9):e436-8.
3. Kim KS. Neonatal Bacterial meningitis. *NeoReviews*. 2015;16(9):e535-43.
4. Moehring R. Infections due to *Serratia* species. Available at: <http://www.uptodate.com/contents/infections-due-to-serratia-species>, last access: October 2015.
5. Edwards M. Bacterial meningites in the neonate: neurologic complications. Available at: <http://www.uptodate.com/contents/bacterial-meningitis-in-the-neonate-neurologic-complications>, last access: October 2015.
6. Messerschmidt A, Prayer D, Olischar M, Pollak A, Birnbacher R. Brain abscesses after *Serratia marcescens* infection on a neonatal intensive care unit: differences on serial imaging. *Neuroradiology*. 2004;46(2):148-52.
7. Philip AGS. Neonatal meningitis in the new millennium. *NeoReviews*. 2003;4(3):e73-80.
8. Dessì A, Puddu M, Testa M, Marcialis MA, Pintus MC, Fanos V. *Serratia marcescens* infections and outbreaks in neonatal intensive care units. *J Chemother*. 2009;21(5):493-9.