

# Congenital melanocytic nevi management: question

Stefania Guida<sup>1</sup>, Giacomo Giovanni Urtis<sup>2</sup>, Giuseppe Rubino<sup>2</sup>, Giovanni Pellacani<sup>1</sup>, Francesca Farnetani<sup>1</sup>

<sup>1</sup>Dermatology Unit, University of Modena and Reggio Emilia, Modena, Italy

<sup>2</sup>Istituto DermoEstetico (IDE), Milan, Italy

*The answers can be found in the following article:*

*Guida S, Urtis GG, Rubino G, Pellacani G, Farnetani F. Congenital melanocytic nevi management: answer. J Pediatr Neonat Individual Med. 2016;5(1):e050128. doi: 10.7363/050128.*

## Keywords

Melanocytic nevi, congenital nevi, melanoma, management.

## Corresponding author

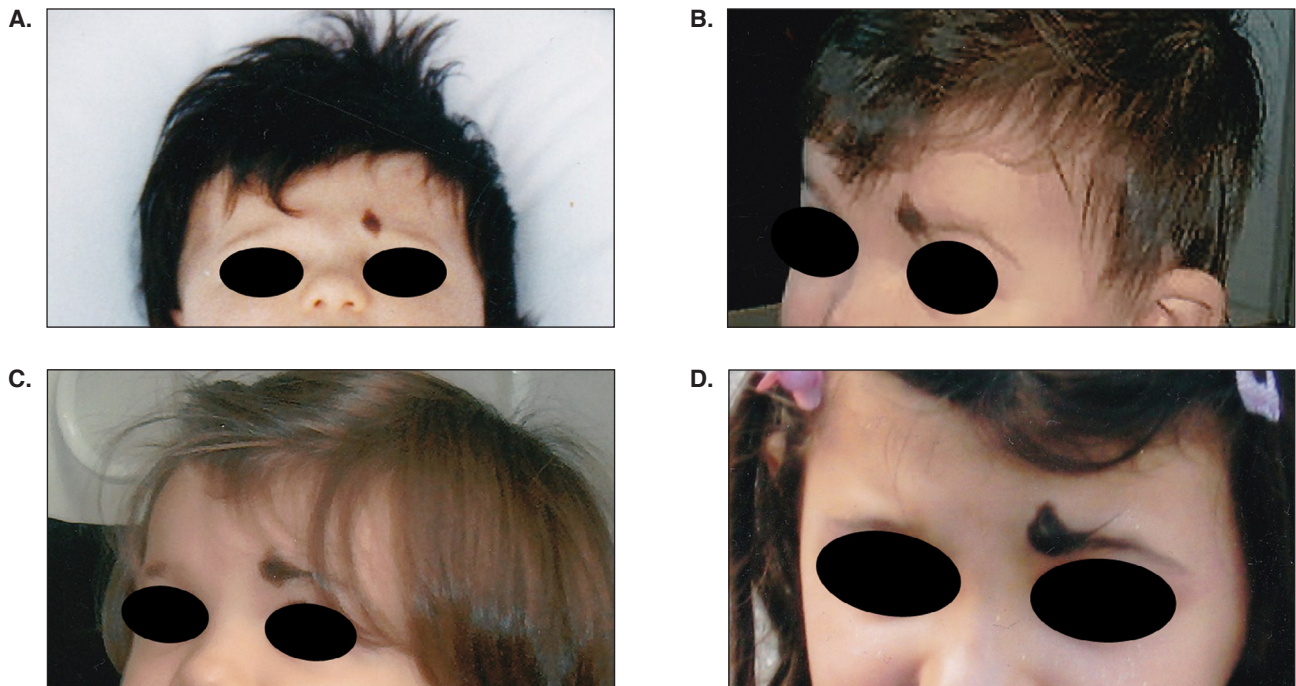
Stefania Guida, Dermatology Unit, University of Modena and Reggio Emilia, Modena, Italy; email: stefania.guida@alice.it.

## How to cite

Guida S, Urtis GG, Rubino G, Pellacani G, Farnetani F. Congenital melanocytic nevi management: question. J Pediatr Neonat Individual Med. 2016;5(1):e050127. doi: 10.7363/050127.

## Case summary

A 12-year-old girl presented to our attention for a pigmented lesion having greatest diameter of 2.5 cm, located on her left forehead, involving the ipsilateral eyebrow. This lesion had appeared as a flat brown macule at birth. With passing years, the lesion showed an increased diameter and thickness and it became progressively darker (**Fig. 1**).



**Figure 1.** Clinical pictures showing a pigmented lesion located on the face at different ages: **A)** at birth; **B)** 18-month-old; **C)** 4-year-old; **D)** 8-year-old.

### Questions

1. What reasons can justify the excision of congenital melanocytic nevi?
2. Which treatment do you think would be more appropriate?

3. Is there a right age to remove a congenital melanocytic nevus?

### Declaration of interest

The Authors declare that there is no conflict of interest.