

Pseudoxanthoma elasticum and reflectance confocal microscopy: report of two affected young sisters

Victor Desmond Mandel¹, Federica Boraldi², Giovanni Pellacani¹, Silvana Ciardo¹, Giovanna Mazzaglia¹, Francesca Farnetani¹

¹Department of Dermatology, University of Modena and Reggio Emilia, Modena, Italy

²Department of Biomedical Sciences, University of Modena and Reggio Emilia, Modena, Italy

Abstract

Pseudoxanthoma elasticum (PXE) is a rare inherited multisystem disorder that mainly affects skin, eyes and cardiovascular system. The associated clinical signs are due to progressive calcification of elastic fibres and blood vessels, despite normal levels of calcium and phosphorus in blood and urine. The first clinical description of the disease was done in 1881 by Rigal, and in 1896 it was named PXE by Darier. Transmission of the disease is autosomal recessive. PXE is caused by homozygous or compound heterozygous mutations in the ATP-binding cassette subfamily C member 6 (*ABCC6*) gene, which encodes a transmembrane transport ADP-dependent protein (MRP6). The gene is expressed predominantly in the liver and kidney, and found in low level in the tissue involved by PXE. The clinical expression of PXE is heterogeneous with considerable variation in age of onset, progression and severity of the disease, even in individuals of the same family with identical mutations.

We present the case of two young sisters affected by PXE and the correlation between the histopathology and the reflectance confocal microscopy (RCM). Parents and brother carry one copy of the mutated gene, without showing signs and symptoms of the disorder. We report the main clinical aspects of PXE and we highlight the importance of early diagnosis of the disease for adequate therapeutical management of associated complications.

Keywords

Pseudoxanthoma elasticum, connective tissue, elastic tissue, reflectance confocal microscopy.

Corresponding author

Dr. Victor Desmond Mandel, Department of Dermatology, University of Modena and Reggio Emilia, via del Pozzo 71, 41100 Modena, Italy; e-mail: victor.desmond.mandel@gmail.com.

How to cite

Mandel VD, Boraldi F, Pellacani G, Ciardo S, Mazzaglia G, Farnetani F. Pseudoxanthoma elasticum and reflectance confocal microscopy: report of two affected young sisters. *J Pediatr Neonat Individual Med.* 2015;4(1):e040125. doi: 10.7363/040125.

Case report

Two sisters (13 and 14 years old) came with their family to our Dermatology Department. Parents reported the onset of yellowish asymptomatic micropapules in the cervical region during infancy, which later involved the axillae and cubital fossae. At dermatological examination of both patients we observed that the skin in the cervical region appeared soft, lax, wrinkled and redundant hanging in folds (**Fig. 1**), while in the axillae and cubital fossae there were coalescent yellowish papules forming plaques with a symmetrically distribution. Ophthalmoscopy identified the presence of angioid streaks in both eyes of the two sisters, confirmed by retinography and angiography. Cardiovascular evaluation didn't show changes in the younger patient while mild mitral valve regurgitation was identified in the older patient.

In our two patients we made diagnosis of pseudoxanthoma elasticum (PXE) using clinical assessment and reflectance confocal microscopy (RCM, a non-invasive imaging technique that produces horizontal images of the skin with cellular level resolution, offering the opportunity to detect characteristic histologic features). The clinical and instrumental diagnosis was also confirmed by histopathological examination, which revealed calcification and fragmentation of elastic fibers in the dermis that appeared distorted.

The parents and the brother (20 years old) didn't show signs and symptoms of the disorder.

Moreover, we performed genetic test and counseling to all the family and we found a mutation of the *ABCC6* gene in the two sisters while parents and brother carried one copy of the mutated gene.

Discussion

PXE is an autosomal recessive disorder characterized by pathological and progressive calcification and fragmentation of elastic fibres, involving predominantly skin, eyes and cardiovascular system [1].

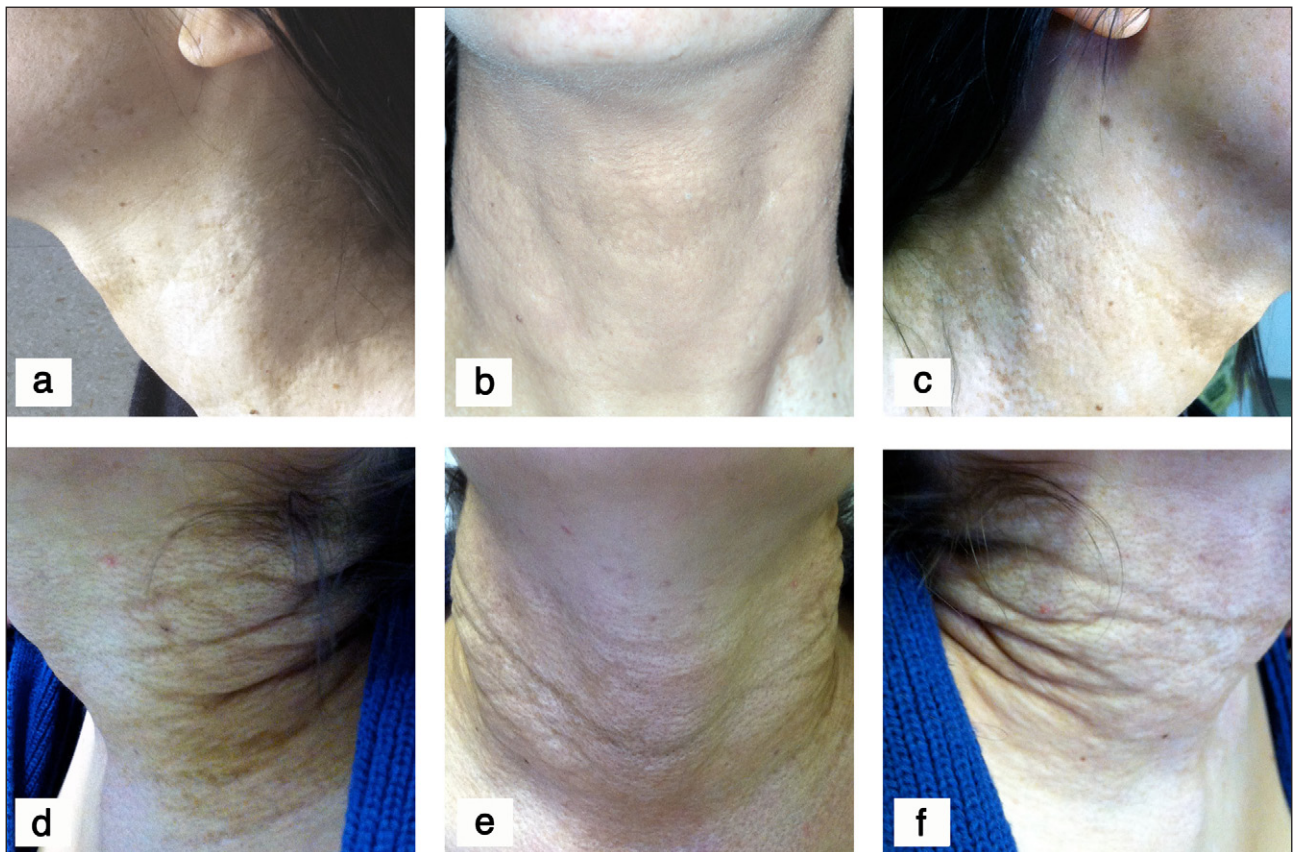


Figure 1. The skin of the cervical region of the younger (a-c) and of the older (d-f) patient appears soft, lax, wrinkled and redundant hanging in folds.

PXE is due to mutations in the *ABCC6* gene (16p13.1), which lead to reduction or absence of the MRP6, causing an accumulation of extracellular material and subsequent deposition of calcium and other minerals in the elastic tissue [2].

The physiological role and the pathogenesis of the disease are still unknown [3]. PXE is present in all world populations, with an estimated prevalence of 1 in 25,000-100,000 and a 2:1 female to male ratio [4].

The average age of onset is 13 years, although it can vary between infancy and oldness.

For evaluation of PXE patients, physicians employ an internationally standardized scoring system (Phenodex™) developed by the PXE International Consortium [3].

Skin lesions are usually the first manifestation of PXE, typically beginning in childhood or early adolescence, classically arising on the lateral aspect of the neck and in flexural areas such as armpits, antecubital and popliteal fossae, and later expanding in some cases to the inguinal region and the periumbilical area [5]. The cutaneous manifestations are round yellowish papules of 1-5 mm in diameter that may coalesce with time into larger protruding plaques. As the disease progresses, the skin becomes soft, lax, wrinkled and redundant hanging in folds. In some cases oral, genital and gastrointestinal mucosae can be involved.

The characteristic ocular manifestations of PXE are angioid streaks of the retina, which are greyish irregular lines radiating outward from the optic papilla corresponding to breaks of the calcified Bruch's membrane. Angioid streaks are often preceded by *peau d'orange* changes and, in the course of the disease, may become pale and give way to a generalized atrophy of the adjacent tissue. In later stages, fibrovascular tissue and choroidal neovascularization may develop. Neovascularization associated with retinal hemorrhages may lead to progressive loss of visual acuity [6].

Cardiovascular manifestations, mainly related to calcium deposition and degeneration of the elastic laminae of medium sized arteries, are intermittent claudication of the lower and/or upper limbs (often regarded as the first sign of accelerated atherosclerosis), hypertension, transitory ischemic events, angina pectoris, myocardial and cerebral infarction [7]. Moreover, mitral valve prolapse has a higher prevalence in PXE, but this may not be significant unless the murmur of mitral valve insufficiency is also present [8]. Gastrointestinal

hemorrhage with hematemesis, melena, evident bleeding or occult blood in the stool occur in 10-15% of patients affected by PXE, especially in the second to fourth decade [9].

The diagnostic criteria of PXE include characteristic clinical findings, together with histopathology of fragmented and distorted elastic fibers in the reticular and deep dermis, and the presence of mutations in the *ABCC6* gene.

RCM (VivaScope 1500®: Caliber I.D., Rochester, USA) is a novel technique, based on a laser light of 830 nm of wavelength (near-infrared), which allows the visualization of skin structures at a nearly histological resolution. A depth of 250 µm can be reached, enabling the examination of the skin up to the upper dermis or to the reticular dermis, in relation of the thickness of the epidermis [10, 11]. The collection of images includes three mosaics on a horizontal plane (VivaBlock modality, covering an area of 6 x 6 mm²), acquired at the spinous-granular layer, at the dermal-epidermal junction, at the upper dermis or even at reticular dermis. Furthermore, several images of small areas (0.5 x 0.5 mm²) showing the most important and diagnostic features, at an increasing depth, were collected according the VivaStack modality.

We performed RCM on the skin surface of the neck of our two young patients and we observed coarse collagen and short and highly curled fibers in reticular dermis on both patients (**Fig. 2**). The coarse collagen and the short and highly curled fibers upon confocal microscopy correspond respectively to the compact collagen and elastic fiber degeneration of the reticular dermis in histopathology. Therefore, RCM is able to detect specific PXE features that correlate with histopathology. Generally, it is very difficult or even not possible to discriminate between collagen fibers and elastic fibers in young skin because these structures present a similar reflectivity and morphology upon RCM [10]. In presence of elastorrhexis or marked elastosis, the fragmented elastic fibers in the upper and reticular dermis show up as highly reflective short and curled fibers that can be readily detected and discriminate within the dermal matrix constituted by variably amorphous and less reflective collagen.

Genetic test and counseling should be offered to PXE patients and their families and management should be carried out in specialized centers. Laboratory and imaging studies should be made whenever necessary. Dermatological, ophthalmological and cardiological evaluation and monitoring is essential for an early diagnosis of

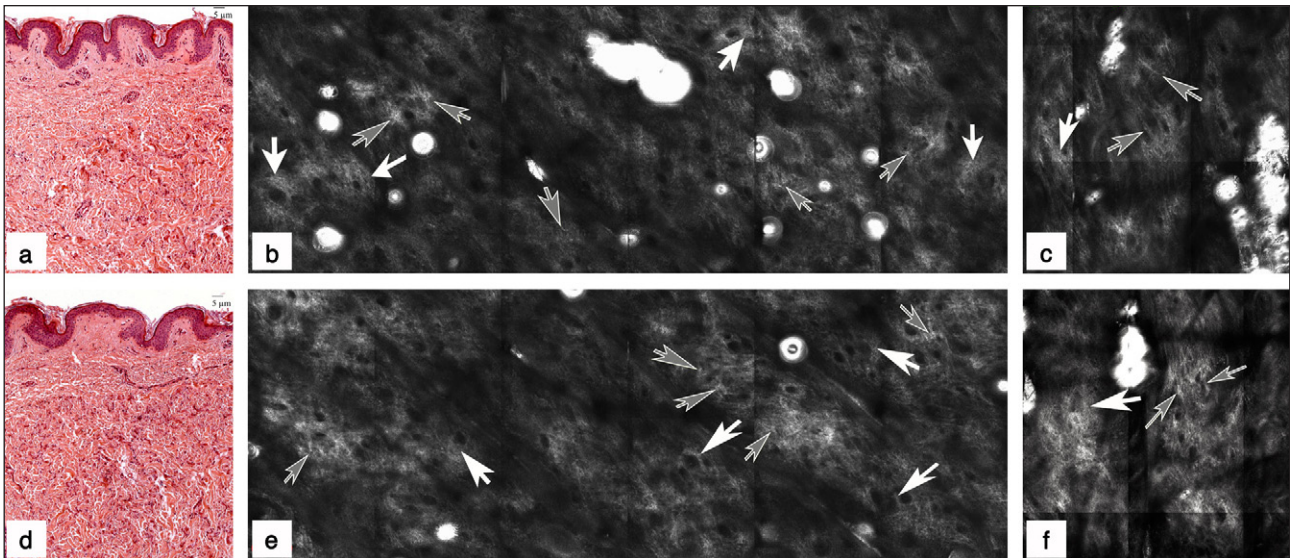


Figure 2. Histopathological findings of skin biopsy performed on the neck of the younger (a) and of the older (d) patient show the short and curled elastic fibers in the reticular dermis. Hematoxylin-eosin stain, original magnification: x5. RCM imaging performed on the skin surface of the neck of the younger (b) and of the older (e) patient shows the short and curled fibers that appear as short and undulated highly reflective fibers (grey arrows) and the coarse and thick collagen fibers (white arrows). The coarse collagen (white arrows) and short and highly curled fibers (grey arrows) upon confocal microscopy correspond respectively to the compact collagen and elastic fiber degeneration of the reticular dermis in histopathology. Instead, RCM imaging performed on the healthy skin surface of the younger (c) and of the older (f) patient shows the normal elastic fibers that appear as undulated fibers (grey arrows) and the coarse and thick collagen fibers (white arrows).

PXE, adequate handling and better management of the associated complications when these are present. We suggest that the use of RCM may be useful to detect PXE in an early stage.

There is yet no definitive therapy and the majority of the pathologic manifestations are irreversible, but prophylactic measures can be undertaken to prevent or minimize some of the signs and symptoms of PXE.

Declaration of interest

The Authors declare that there is no conflict of interest.

References

- Gheduzzi D, Sammarco R, Quaglino D, Bercovitch L, Terry S, Taylor W, Ronchetti IP. Extracutaneous ultrastructural alterations in pseudoxanthoma elasticum. *Ultrastruct Pathol.* 2003;27:375-84.
- Gheduzzi D, Guidetti R, Anzivino C, Tarugi P, Di Leo E, Quaglino D, Ronchetti IP. ABCC6 mutations in Italian families affected by pseudoxanthoma elasticum (PXE). *Hum Mutat.* 2004;24:438-9.
- Pfendner EG, Vanakker OM, Terry SF, Vourthis S, McAndrew PE, McClain MR, Fratta S, Marais AS, Hariri S, Coucke PJ, Ramsay M, Viljoen D, Terry PF, De Paepe A, Uitto J, Bercovitch LG. Mutation detection in the ABCC6 gene and genotype-phenotype analysis in a large international case series affected by pseudoxanthoma elasticum. *J Med Genet.* 2007;44:621-8.
- Bercovitch L, Terry P. Pseudoxanthoma elasticum 2004. *J Am Acad Dermatol.* 2004;51(1 Suppl):S13-4.
- Hacker SM, Ramos-Caro FA, Beers BB, Flowers FP. Juvenile pseudoxanthoma elasticum: recognition and management. *Pediatr Dermatol.* 1993;10:19-25.
- Georgalas I, Tservakis I, Papaconstantinou D, Kardara M, Koutsandrea C, Ladas I. Pseudoxanthoma elasticum, ocular manifestations, complications and treatment. *Clin Exp Optom.* 2011;94:169-80.
- Finger RP, Charbel Issa P, Ladewig MS, Götting C, Szliska C, Scholl HP, Holz FG. Pseudoxanthoma elasticum: genetics, clinical manifestations and therapeutic approaches. *Surv Ophthalmol.* 2009;54:272-85.
- Lebwohl MG, Distefano D, Prioleau PG, Uram M, Yannuzzi LA, Fleischmajer R. Pseudoxanthoma elasticum and mitral-valve prolapse. *N Engl J Med.* 1982;307:228-31.
- Spinzi G, Strocchi E, Imperiali G, Sangiovanni A, Terruzzi V, Minoli G. Pseudoxanthoma elasticum: a rare cause of gastrointestinal bleeding. *Am J Gastroenterol.* 1996;91:1631-4.
- Longo C, Casari A, Beretti F, Cesinaro AM, Pellacani G. Skin aging: in vivo microscopic assessment of epidermal and dermal changes by means of confocal microscopy. *J Am Acad Dermatol.* 2013;68:e73-82.
- Agazzino M, Berardesca E, Donadio C, Franceschini C, de Felice CM, Cavallotti C, Sperduti I, Ardigò M. Reflectance confocal microscopy features of seborrheic dermatitis for plaque psoriasis differentiation. *Dermatology.* 2014;229:215-21.