

# Seizures-like symptoms in an African child with life-threatening severe upper respiratory tract obstruction

Marco Zaffanello<sup>1</sup>, Emma Gasperi<sup>1</sup>, Paolo Biban<sup>2</sup>, Luigi Lubrano<sup>1</sup>, Elena Fiorini<sup>3</sup>, Giorgio Piacentini<sup>1</sup>

<sup>1</sup>Department of Life and Reproduction Sciences, Pediatric Division, University of Verona, Verona, Italy

<sup>2</sup>Department of Neonatal and Paediatric Intensive Care, Azienda Ospedaliera Universitaria Integrata, Verona, Italy

<sup>3</sup>Department of Life and Reproduction Sciences, Child Neuropsychiatry Division, University of Verona, Verona, Italy

## Abstract

Obstructive sleep apneas are characterized by episodes of complete or partial upper airway obstruction during sleep. Symptoms and signs are associated with sleep-related breathing disorders. Sometimes it can be clinically difficult to distinguish abnormal events related to sleep disorders from seizures. We report herein the case of a child with seizures-like symptoms during sleep. Epilepsy was excluded and symptomatology was referred to life-threatening upper respiratory obstruction from tonsils and adenoids hypertrophy that required persistent intubation before surgical removal.

## Keywords

Seizures-like symptoms, obstructive sleep apnea, upper respiratory tract obstruction, limited channel polysomnography.

## Corresponding author

Marco Zaffanello, MD, Department of Life and Reproduction Sciences, Pediatric Division, University of Verona, Piazzale L.A. Scuro, 10, 37134, Verona, Italy; telephone: +39 045 8124387; fax: +39 045 8124790; email: marco.zaffanello@univr.it.

## How to cite

Zaffanello M, Gasperi E, Biban P, Lubrano L, Fiorini E, Piacentini G. Seizures-like symptoms in an African child with life-threatening severe upper respiratory tract obstruction. *J Pediatr Neonat Individual Med.* 2015;4(1):e040105. doi: 10.7363/040105.

## Introduction

Obstructive sleep apneas (OSA) are characterized by episodes of complete or partial upper airway obstruction during sleep. During childhood, it is more frequently caused by tonsils and adenoid hypertrophy. The short-term effects of undetected sleep-disordered breathing in children include detrimental effects on school performance, behavior and cognition. OSA syndrome in the long-term may negatively affect growth, neurocognitive function, and cardiovascular physiology [1]. Screening and treatment recommendations are made in children with high-risk of sleep-related breathing disorders [2].

During sleep, symptoms and signs associated with sleep-related breathing disorders are odd sleeping position, snoring or snorts, gasping or labored breathing, witnessed apneas, sweating and enuresis; during the day, symptoms and signs are behavioral problems, failure to thrive, morning headaches and mouth breathing. Signs of nocturnal seizures can overlap with sleep respiratory events such as apnea, tachypnea, bradycardia, coughing, vocalizations, bruxism, and body or limb movements [3].

We report herein the case of a child hospitalized for suspected seizures, with severe life-threatening upper respiratory obstruction from tonsils and adenoid hypertrophy that needed persistent intubation before surgical removal.

## Case report

We present an African boy (3.5 year-old, body weight 22 kg) with unremarkable perinatal medical history. The child was carried out by the mother to the Hospital because of worsening of the symptoms characterized by nocturnal respiratory difficulties, snoring, drooling, revulsion of the eyes and tremors on all four limbs. On clinical examination, he showed severe bilateral tonsils hypertrophy. No facial anomaly and thoracic deformity have been reported. Urgent laboratory exams did not show signs of infection. Since during sleep he showed frequent waking and blood desaturations (up to 88%) he was hospitalized.

The clinical history initially agreed for seizures. The electroencephalogram (EEG) disclosed isolated sharp-waves. These anomalies increased in frequency and diffusion during sleep. During the recording, an episode of noisy breathing, drooling appearance of tachypnea and desaturation to 84%

occurred. The EEG reported a slow sleep pattern with fragmented arousal but no critical activities.

Electrocardiogram (ECG) and thorax X-ray resulted negative. Ultrasound of the neck confirmed multiple enlarged lymphnodes. Because of severe respiratory distress during sleep, the patient was transferred to the Pediatric Intensive Care Unit. Endoscopy examination of the airways showed edema of the nasal and turbinate mucosae, adenoids and tonsils hypertrophy. Finally, he was intubated.

After an elective extubation, he performed a limited-channel polysomnography (PSG) (SOMNOscreen™ PSG, SOMNOmedics GmbH, Randersacker, Germany). The channels included light sensor, body position, microphone, chest and abdomen movements, nasal pressure, SpO<sub>2</sub>, and ECG (2 channels). The measurements were suddenly interrupted (30 minutes) because of prolonged apneas and desaturations (**Tab. 1, Fig. 1**). During manual ventilation, before re-intubation, he showed eyes revulsion and legs tremor.

A magnetic resonance imaging confirmed the airway endoscopy findings; the brain was negative for ischemic lesions.

Adenotonsillectomy was performed 3 days after hospitalization. The patient was extubated at the 2<sup>nd</sup> post-operative day. He was discharged from the Hospital 11 days after admission.

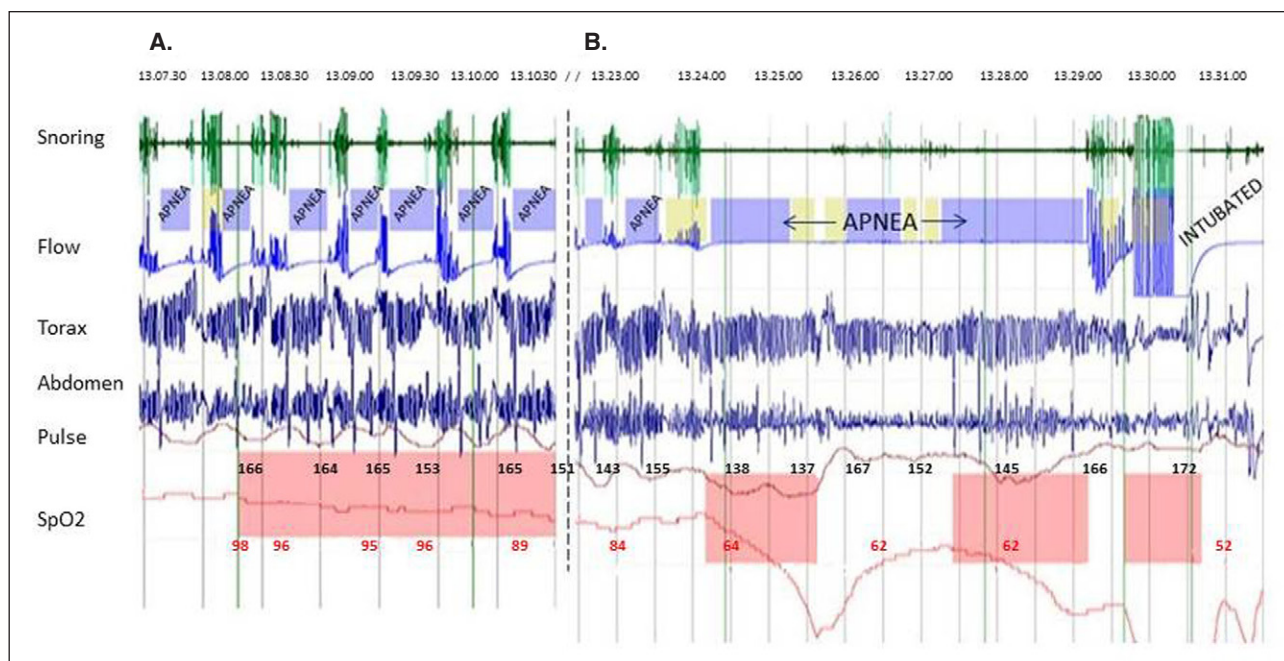
During follow-up examination, the same sleep study device was applied 2 months later (**Tab. 1**). At this time, the patient had an upper respiratory congestion (rhinitis) from mild viral infection.

## Discussion

OSA syndrome in children is defined as a disorder of breathing during sleep characterized

**Table 1.** Abbreviated and overnight sleep study in an African child with upper airway obstructions.

Sleep parameters	T = 0	2-months follow-up
Registration time (hours)	0.5	10
Obstructive apnea index (/hour)	62.5	0.4
Apnea-hypopnea index (/hour)	64.4	3.7
SpaO <sub>2</sub> mean (%)	85	99
SpaO <sub>2</sub> minimum (%)	36	88
Number of SpaO <sub>2</sub> < 90% (/hour)	14	0.4
Snoring (%)	17.3	3
Respiratory rate (/min)	8	13



**Figure 1.** Representative limited channel polysomnography recording that shows: the time sequence of recurrent events of obstructive sleep apneas (A); the final obstructive prolonged apnea followed by assisted ventilation and final intubation (B).

by prolonged partial upper airway obstruction and/or intermittent complete obstruction (obstructive apnea) that disrupts normal ventilation during sleep [4]. OSA syndrome is a common condition in childhood.

The internationally-recognized gold-standard of investigation is an attended, night-time, in-laboratory polysomnography [4]. Polysomnography is able to demonstrate the presence or absence of OSA syndrome, the severity of OSA syndrome, to planning treatment and postoperative short- and long-term management [5]. However, many centres (our own included) undertake cardiorespiratory sleep studies with effort bands (thorax and abdomen), airflow measures, heart rate and SpO<sub>2</sub> monitoring [6]. A technically-adequate data can be achieved using this device [7].

A case of a 3-year-old child with paradoxical breathing, desaturations and tonic-dystonic posture was recently reported. Following a cardiorespiratory polysomnography, the patient was initially misdiagnosed as having severe OSA syndrome. He had instead an atypical OSA syndrome from nocturnal seizures [3]. On the contrary, in our patient, the presenting signs during sleep agreed initially for seizures and finally he was diagnosed as having severe OSA syndrome.

Severe untreated OSA can result in serious morbidity and even death [8]. The early literature on OSA syndrome described children who presented

with cardiorespiratory failure or coma, some of whom died [9, 10]. Severe life-threatening OSA observed in our patient and characterized by sleep seizures-like presentation were linked to turbinate edema, adenoids and tonsils hypertrophy. Surgery was performed with complete resolution of the symptomatology.

Miano et al. recommended the video-PSG with extended EEG montage because found a close relationship between sleep breathing disorders and epilepsy: 4 out of 25 patients with suspected OSA syndrome had epilepsy. They were mainly older, had perinatal injuries and long history of OSA syndrome. The association among pediatric sleep breathing disorders, paroxysmal activity during sleep, and epilepsy may aggravate the prognosis of OSA [11].

In conclusion, it is important to screen, recognize and treat as early as possible the OSA condition. Seizures-like symptoms suggest an advanced stage of OSA syndrome at risk of death.

#### Declaration of interest

The Authors declare that there is no conflict of interest. No financial assistance was received to support this study.

#### References

1. Gozal D. Sleep-disordered breathing and school performance in children. *Pediatrics*. 1998;102:616-20.

2. Atkinson M; Clinical Standards Committee at the Royal College of Paediatrics and Child Health. Sleep, snoring and acute life-threatening events. *Arch Dis Child Educ Pract Ed.* 2010;95(6):190-3.
3. Vitelli O, Miano S, Tabarrini A, Mazzotta AR, Supino MC, Forlani M, Villa MP. Epilepsy and sleep-disordered breathing as false friends: a case report. *J Child Neurol.* 2014;29(10):NP114-7.
4. Iber C, Ancoli-Israel S, Chesson A, Quan SF. The AASM Manual for the Scoring of Sleep and Associated Events: Rules, Terminology and Technical Specifications, 1<sup>st</sup> ed. Westchester, IL, USA: American Academy of Sleep Medicine, 2007.
5. Marcus CL, Brooks LJ, Draper KA, Gozal D, Halbower AC, Jones J, Schechter MS, Ward SD, Sheldon SH, Shiffman RN, Lehmann C, Spruyt K; American Academy of Pediatrics. Diagnosis and management of childhood obstructive sleep apnea syndrome. *Pediatrics.* 2012;130:e714-55.
6. Collop NA, Anderson WM, Boehlecke B, Claman D, Goldberg R, Gottlieb DJ, Hudgel D, Sateia M, Schwab R; Portable Monitoring Task Force of the American Academy of Sleep Medicine. Clinical guidelines for the use of unattended portable monitors in the diagnosis of obstructive sleep apnea in adult patients. Portable Monitoring Task Force of the American Academy of Sleep Medicine. *J Clin Sleep Med.* 2007;3(7):737-47.
7. Rosen CL, Larkin EK, Kirchner HL, Emancipator JL, Bivins SF, Surovec SA, Martin RJ, Redline S. Prevalence and risk factors for sleep-disordered breathing in 8- to 11-year-old children: association with race and prematurity. *J Pediatr.* 2003;142(4):383-9.
8. Section on Pediatric Pulmonology, Subcommittee on Obstructive Sleep Apnea Syndrome. American Academy of Pediatrics. Clinical practice guideline: diagnosis and management of childhood obstructive sleep apnea syndrome. *Pediatrics.* 2002;109(4):704-12.
9. Kravath RE, Pollak CP, Borowiecki B, Weitzman ED. Obstructive sleep apnea and death associated with surgical correction of velopharyngeal incompetence. *J Pediatr.* 1980;96:645-8.
10. Ross RD, Daniels SR, Loggie JM, Meyer RA, Ballard ET. Sleep apnea-associated hypertension and reversible left ventricular hypertrophy. *J Pediatr.* 1987;111(2):253-5.
11. Miano S, Bachiller C, Gutiérrez M, Salcedo A, Villa MP, Peraita-Adrados R. Paroxysmal activity and seizures associated with sleep breathing disorder in children: a possible overlap between diurnal and nocturnal symptoms. *Seizure.* 2010;19(9):547-52.