

A novel SRY nonsense mutation in a case of Swyer syndrome

Clara Machado¹, Angela Pereira¹, José Matos Cruz², Alexandra Cadilhe², Albina Silva¹, Almerinda Pereira¹

¹Pediatrics Department, Braga Hospital, Portugal

²Fetal Medicine Unit, Obstetrics Department, Braga Hospital, Portugal

Abstract

Swyer syndrome is a condition in which individuals with one X chromosome and one Y chromosome in each cell have a female appearance. They generally have female external genitalia, a normal uterus and Fallopian tubes, but no functional gonads. Its prevalence is about 1 in 30,000 births. Mutations in the SRY gene have been identified in 15-20% of the cases.

The authors present the clinical case of a female fetus, who was the first child of young, healthy, unrelated parents, with increased nuchal translucency in first trimester ultrasonography and combined risk for Down syndrome of 1/20. Prenatal karyotype was 46,XY. Delivery occurred at 37 weeks gestation by cesarean section. Uneventful neonatal period. At birth she had adequate weight and height and presented complete female external genitalia with no other abnormalities. Pelvic ultrasound showed normal morphology of the uterus, ovaries were not visualized. Hormonal study was normal. Repeated postnatal karyotype confirmed 46,XY. Follow-up on Neonatology Consultation as outpatient. Abdomino-pelvic MRI (3 months old) showed presence of uterus with normal dimensions and appearance and ovaries not clearly defined. The molecular genetic testing revealed the Q 114X (c.340 C>T) mutation of the SRY gene, a nonsense mutation that has not been described.

Early diagnosis of Swyer syndrome in childhood is only possible if a karyotype is carried out for other reasons, such as for example as part of prenatal diagnosis (as it happened with our patient).

This prompt diagnosis is important for early institution of hormone replacement therapy and close monitoring, because of the risk of gonadal malignancy. Clinical and imaging surveillance is mandatory in order to program early gonadectomy if necessary. In our patient, the novel mutation detected in the SRY gene may be an aetiopathogenic factor in clinically defined 46,XY complete gonadal dysgenesis.

Keywords

Female, gonads, karyotype, mutation, syndrome, Swyer.

Corresponding author

Clara Machado, Pediatrics Department, Braga Hospital, Portugal;
email: clara.machado@gmail.com.

How to cite

Machado C, Pereira A, Matos Cruz J, Cadilhe A, Silva A, Pereira A. A novel SRY nonsense mutation in a case of Swyer syndrome J Pediatr Neonat Individual Med. 2014;3(1):e030107. doi: 10.7363/030107.

Introduction

Swyer syndrome was first recognized in 1955 when Gim Swyer described two cases of sex reversal that differed from the known forms of what was then termed “male pseudohermaphroditism”. The two women had a 46,XY karyotype and had primary amenorrhoea, tall stature, female external genitalia (although one had an enlarged clitoris) and normal – albeit hypoestrogenised – vagina and cervix [1]. This condition was later linked to dysgenetic gonads and is also known as complete gonadal dysgenesis (CGD) [2].

46,XY CGD is characterized by a 46,XY karyotype, normal female external genitalia, completely undeveloped (“streak”) gonads, no sperm production, hypergonadotropic hypogonadism (secondary to gonadal failure) and presence of normal Mullerian structures (uterus, fallopian tubes and vagina) [3]. These individuals are typically raised as females and have a female gender identity [4].

Swyer syndrome has been estimated to occur in approximately 1 in 30,000 people [4]. The diagnosis relies on clinical findings, gonadal history, chromosome analysis, and testing to detect changes in one of the following genes: SRY, NR5A1, DHH, NR0B1 or WNT4 [3].

Mutations in the SRY gene have been identified in between 15-20% of individuals with this condition. These mutations prevent production of the sex-determining region Y protein or result in the production of a nonfunctioning protein. A fetus whose cells do not produce functional sex-determining region Y protein will develop as a female, despite having a Y chromosome. In the remaining 80-90% of cases, the SRY gene is normal and mutations in other genes are probably implicated [4]. Swyer syndrome can be inherited in an autosomal dominant (NR5A1 mutations, heterozygous mutations in DHH, WNT4

duplications), autosomal recessive (homozygous [or compound heterozygous] mutations in DHH), X-linked (NR0B1 duplications) or Y-linked (SRY mutations) manner depending on the gene involved [3].

Most cases of SRY-related Swyer syndrome result from new mutations and occur in people with no history of the disorder in their family.

The condition usually first becomes apparent in adolescence with delayed puberty and primary amenorrhoea due to the fact that the gonads have no hormonal or reproductive potential [2].

Affected individuals usually begin hormone replacement therapy during adolescence to induce menstruation and development of female secondary sex characteristics such as breast enlargement and body hair. This therapy also helps prevent reduced bone density (osteopenia). Women with this disorder do not produce eggs, but may be able to become pregnant with a donated egg or embryo [4].

A high incidence of gonadoblastoma and germ cell malignancies has been reported, and therefore, the current practice is to proceed to a gonadectomy once the diagnosis is made [2]. If the patient is not able to undergo surgery or if she refuses it, a careful follow up is necessary. If gonads are removed early in life to prevent gonadal tumors, life span is not reduced. The cumulative risk of developing gonadoblastoma is 30% by age 40 years [3].

Presentation of the case

The authors describe the case of a healthy 33-years old pregnant (first pregnancy) with increased nuchal translucency in first trimester ultrasonography and combined risk for Down syndrome of 1/20. For this reason amniocentesis was performed and fetal karyotype was 46,XY. In the second trimester ultrasonography, nuchal fold was increased and normal female genitalia were found, despite fetal karyotype. Fetal echocardiogram was normal.

The pregnancy was uneventful, and the delivery occurred at 37 weeks gestation by cesarean section, due to breech presentation of the fetus. Apgar scored 1':10/5':10. At birth, the newborn had adequate weight and length (weight: 2,930 g, length: 47 cm, head circumference: 35 cm), and presented complete female external genitalia with no other abnormalities or dismorphic characteristics (**Fig. 1**). Her parents were young, healthy and unrelated and there are no cases of genetic syndromes in the family.

Pelvic ultrasound showed normal morphology of the uterus but ovaries were not visualized (**Fig. 2**).

The karyotype performed postnatally confirmed 46,XY. Hormonal study in the neonatal period was normal.

Neonatal period was uneventful. Pelvic magnetic resonance imaging (MRI) was made at 3 months of life and revealed the presence of uterus with normal dimensions and appearance, but ovaries not clearly defined (**Fig. 3**).

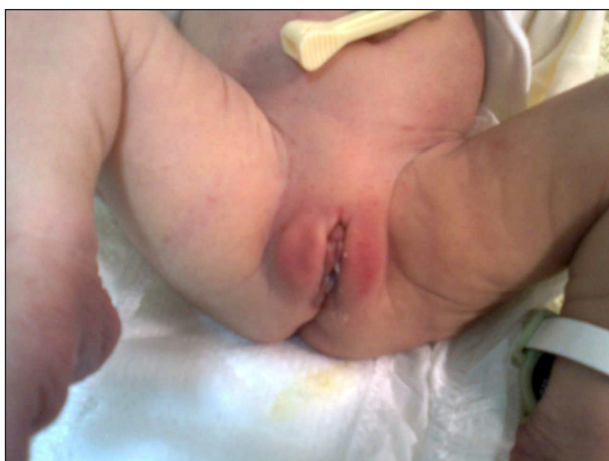


Figure 1. Complete female external genitalia at birth.

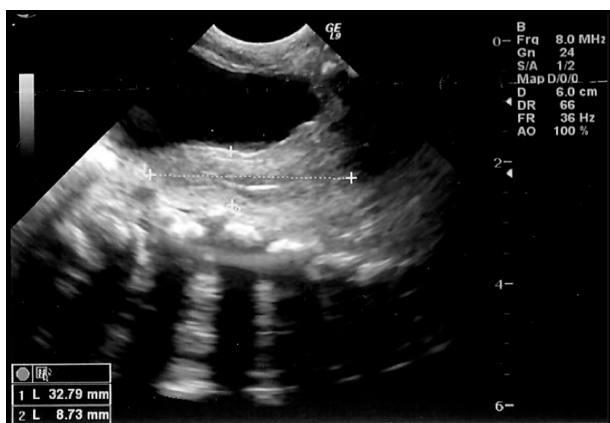

Figure 2. Pelvic ultrasound.

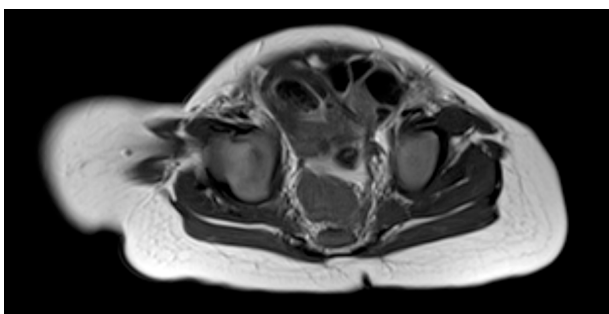


Figure 3. Abdomino-pelvic MRI (3 months old).

The molecular genetic testing was accomplished, with sequencing of the gene coding of the SRY gene, and revealed the Q 114X (c.340 C>T) mutation of the SRY gene, a nonsense mutation that has not been described.

She maintains follow-up on Neonatology and Pediatric Endocrinology consultation.

Discussion

In utero, sexual differentiation follows a sequential pattern. After fertilization there is establishment of the genotype of the embryo and under the influence of the single gene determinant (testes determining factor) on the short arm of the Y chromosome, there is differentiation of the primordial gonads into the testes. The ovaries develop by default, in the absence or nonfunctioning of the Y chromosome. This differentiation of the primordial gonads into the testes or ovary will lead to an alteration of the hormonal milieu of the fetus, which in turn results in the corresponding differentiation of the internal and external genitalia [5].

In complete gonadal dysgenesis patients, immature bi-potential gonads fail to differentiate along the male pathway, during early embryonic development [7]. Pivotal to this process is the SRY gene.

Most SRY mutations are *de novo* events affecting one family member, and 11 familial mutations have been described [13]. All lies in the DNA-binding high-mobility group (HMG) box. Six of the changes are missense mutations, three are nonsense mutations and two deletions causing frameshifts [8].

Our patient presented a SRY mutation consisting in the variant Q 114X (c.340 C>T) which we report for the first time in the literature.

Affected individuals are raised as females and usually are not diagnosed until puberty, when primary amenorrhea is evident because of the lack of estrogen and progesterone production by the streak gonads [3]. Early diagnosis of Swyer syndrome in childhood is only possible if a karyotype is carried out for other reasons, such as for example as part of prenatal or as part of family screening following the diagnosis of a sibling with the condition [2]. In the presented case, the results of nuchal translucency and fetal ultrasound induced to perform amniocentesis as a further examination which led to the diagnosis.

The prompt diagnosis has a crucial importance for several reasons like the early institution of hormone replacement therapy (for induction of

puberty, fertility and prevention of osteopenia) and close monitoring, because of the risk of gonadal malignancy [6], as the overall survival rate is 90-100% in cases diagnosed in the early stages but decreases to 54% in those diagnosed in the advanced stages [9].

The major risk is the development of gonadoblastoma which can be avoided with early diagnosis and surgical removal of streak gonads [3]. In this patient ovaries were not visualized in pelvic MRI and so we were not able to confirm the presence of streak gonads. Therefore clinical and imaging surveillance is mandatory in order to program early gonadectomy.

In conclusion, early diagnosis of Swyer syndrome is crucial in view of the high risk of malignancies that can develop at an early age. Although increased awareness has probably improved the management of these women, it is important that they continue to be followed up in tertiary centers by multidisciplinary teams. In fact, they are able to provide the multifaceted care that is required in terms of induction of puberty, prevention of osteopenia and fertility. It is also important for these centers to form larger databases to acquire a better understanding of the condition and improve their management.

Declaration of interest

The Authors declare that there is no conflict of interest.

References

1. Swyer GI. Male pseudohermaphroditism: a hitherto undescribed form. *Br Med J*. 1955;2:709-12.
2. Michala L, Goswami D, Creighton S, Conway G. Swyer syndrome: presentation and outcomes. *BJOG*. 2008;115:737-41.
3. Ostrer H. 46,XY Disorder of Sex Development and 46,XY Complete Gonadal Dysgenesis. In: Pagon RA, Adam MP, Bird TD, Dolan CR, Fong CT, Stephens K (Eds.). *GeneReviews™* [Internet]. Seattle (WA): University of Washington, Seattle; 1993-2013. Available from: <http://www.ncbi.nlm.nih.gov/books/NBK1547/>; initial posting: May 2008; last revision: September 2009.
4. <http://ghr.nlm.nih.gov/condition/swyer-syndrome>, last access: October 2013.
5. Panicker R, Srinivas S. Swyer's Syndrome: An Uncommon Cause of Primary Amenorrhoea. *MJAFI*. 2009;65:186-7.
6. Temime RB, Chechia A, Attia L, Ghodbane I, Boudaya F, Makhoulouf T, Koubaa A. Syndrome de Swyer : à propos de cinq cas. *J Gynecol Obstet Biol Reprod (Paris)*. 2009;38:220-5.
7. Battaglia F, Plotti F, Angelucci M, Aloisi A, Angioli R. Novel mutation of the sex-determining region on the Y chromosome in a 46,XY female patient with monolateral dysgerminoma: A case report. *J Obstet Gynaecol Res*. 2013;39(1):442-5.
8. Ross Hawkins J. Mutational analysis of SRY in females. *Hum Mutat*. 1993;2:347-50.
9. Ayhan A, Bildirici I, Günalp S, Yuce KI. Pure dysgerminoma of the ovary: A review of 45 well staged cases. *Eur J Gynaecol Oncol*. 2000;21:98-101.
10. Behtash N, Karimi Z M. Dysgerminoma in three patients with Swyer syndrome. *World J Surg Oncol*. 2007;5:71-2.
11. Hughes IA, Houk C, Ahmed SF, Lee PA; LWPE/ESPE Consensus Group. Consensus statement on management of intersex disorders. *Arch Dis Child*. 2006;91:554-63.
12. Biason-Lauber A, Konrad D, Meyer M, deBeaufort C. Ovaries and Female Phenotype in a Girl with 46,XY Karyotype and Mutations in the CBX2 Gene. *Am J Hum Genet*. 2009;84:658-63.
13. Ságodi L, Ladányi E, Kiss Á, Tar A, Lukács V, Minik K, Vámosi I. [Pure 46,XY gonadal dysgenesis]. [Article in Hungarian]. *Orv Hetil*. 2010;151(48):1991-5.