

Congenital syphilis: a revision of the cases over the last 18 years in a referral hospital in Lisbon

Francisca Costa, Maria Mendes, Marta Ferreira, Rosalina Barroso

Hospital Professor Doutor Fernando da Fonseca, EPE. Lisbon, Portugal

Abstract

Introduction: Congenital syphilis is a preventable disease and its persistence reflects a failure in prenatal care delivery systems.

Objectives: To identify demographic maternal characteristics, risk factors and clinical features of congenital syphilis. The secondary outcome was to describe the symptomatic cases of congenital syphilis.

Methods: Retrospective study of all the children born, between 1997-2015, to syphilis seropositive women. We collected data regarding sociodemographic characteristics, maternal VDRL (Venereal Disease Research Laboratory) titers, co-infections and treatment during pregnancy, clinical features, treatment and follow-up.

Results: From a total of 80,639 newborns, 310 mothers and 225 babies had positive VDRL titers. The prevalence risk for congenital syphilis was 0.27%, higher between 2003-2008. Observed maternal characteristics were: 3.9% young mothers (< 20 y), 45.2% African origin, 12.5% basic educational levels, 14.5% unemployed, 6.5% co-infected with human immunodeficiency virus (HIV), 4.7% drug abuse. Prenatal care coverage was provided in 82.9% of the mothers, with only 52.9% adequately treated. Maternal syphilis was classified in: 21.6% early, 21.6% late, 56.8% undetermined. The newborns were classified in: 13.2% highly probable, 41.6% possible and 45.2% less likely. There were four cases of symptomatic congenital syphilis, 3 of them with neurosyphilis. 96% were treated with penicillin. 165/310 (53%) had an adequate follow-up, and the mean age for a negative VDRL titer was at 5.6 months of age.

Conclusions: The high percentage of women inadequately treated alerts to the importance of improving prenatal care. Neurosyphilis is a rare and severe presentation of congenital syphilis; screening is essential to avoid late cases or sequels.

Keywords

Epidemiology, diagnostic testing, congenital syphilis, neurosyphilis, complications.

Corresponding author

Francisca Costa, Departamento de Pediatria, Hospital Professor Doutor Fernando da Fonseca, EPE, IC 19, 2720-276, Amadora, Lisboa, Portugal; telephone number: 00351 916917366; fax number: 00351 21 434 55 66; e-mail: francisca88costa@gmail.com.

How to cite

Costa F, Mendes M, Ferreira M, Barroso R. Congenital syphilis: a revision of the cases over the last 18 years in a referral hospital in Lisbon. *J Pediatr Neonat Individual Med.* 2019;8(1):e080119. doi: 10.7363/080119.

Introduction

Syphilis is a sexually and vertically transmitted disease caused by the spirochete *Treponema pallidum*. It can affect pregnant women at any gestational age, but the risk of affecting the fetus is higher from 20 weeks [1, 2]. Treatment with penicillin is efficient. Congenital syphilis is a preventable disease and its persistence reflects a failure in prenatal care systems. Global statistics indicate that there are 10 million new cases every year [1]. Low socio-economic background and education, late prenatal screening, born of African descent and co-infections have been pointed out to be important risk factors [2, 3].

The primary outcome of the study was to identify newborns at risk of congenital syphilis. The secondary outcome was to describe the symptomatic cases of congenital syphilis.

Methods

We performed a retrospective study of all children born to women with positive non-treponemal tests (VDRL, Venereal Disease Research Laboratory) at a referral hospital in Lisbon, between 1997 and 2015. Data was analyzed by consulting medical charts, and it included: socio-demographic characteristics, maternal VDRL titers, co-infections and treatment during pregnancy, newborn clinical features and laboratory results, treatment and follow-up.

Portuguese national guidelines define adequate prenatal coverage as: at least 6 consultations during pregnancy (1 every six weeks till 30 weeks of gestation, 1 every three weeks between 30-36 weeks and 1 every two weeks until delivery); at least 2 analytic (1st and 3rd trimester) screenings for sexually transmitted diseases, rubella and

toxoplasmosis, gestational diabetes, blood type and Coombs test; at least 3 gestational ultrasounds (one per trimester). Inadequate prenatal coverage was considered when at least one of these criteria was not fulfilled [4].

The definition of maternal syphilis and classification of the risk for congenital syphilis (proven or highly probable, possible, less likely or unlikely) was determined by using the Centres for Disease Control and Prevention guidelines [2]. Maternal syphilis was classified as: a) early – evidence of primary or secondary syphilis, latent infection documented by a nonreactive syphilis serology within the past year, history of symptoms of early syphilis within the past year; b) late – evidence of tertiary syphilis or late latent syphilis. All cases where medical history was unknown previously to the pregnancy or serologic testing was insufficient to differentiate between late or early syphilis were classified as undetermined maternal syphilis. Portuguese guidelines for the surveillance of maternal syphilis support testing with VDRL in the 1st and 3rd trimester and, if positive, confirmation with *Treponema pallidum* hemagglutination assay (TPHA) or fluorescent treponemal antibody absorption (FTA-abs) [5]. Treatment of maternal syphilis was considered inadequate when there was: an inappropriate regime for the stage of infection, no documentation of treatment; a non-penicillin G regime; treatment less than 4 weeks before delivery.

Congenital syphilis was classified as proven or highly probable when the newborn was symptomatic or had a non-treponemal serologic titer fourfold higher than the mother's. Possible congenital syphilis was defined in asymptomatic neonates, whose mothers were inadequately treated, with VDRL titers inferior or equal to the mother's. If the mothers were adequately treated and there was no evidence of reinfection or relapse, the risk for congenital syphilis was considered less likely. Unlikely syphilis was considered in the cases where the mother was adequately treated before pregnancy and had low and stable VDRL titers throughout pregnancy.

We identified five cases of symptomatic congenital syphilis: 4 that are further described, 1 was excluded for insufficient data to describe the case.

Statistical analysis was performed using SPSS® (version 23.0). Chi-square function was applied when necessary.

Results

From a total of 80,639 live births, 310 mothers and 225 newborns had positive VDRL titers, with an estimated prevalence of 0.27% risk for congenital syphilis. In 2008 the risk was 0.64%, the highest of the 19 years of the study.

The median maternal age was 29.5 years (min 17 years, max 46 years). **Tab. 1** summarises the main maternal characteristics. 45.2% of mothers were from African origin and 10.6% completed only primary education.

Risk factors identified for maternal syphilis included: human immunodeficiency virus (HIV) (6.5%); hepatitis B (5.4%); drug abuse (4.7%); hepatitis C (2.2%); prostitution (0.9%). There was no statistically significant difference in prenatal care coverage among Portuguese or immigrant mothers.

The mean gestational age was 38 weeks (standard deviation: 3.6 weeks) and the median birth weight was 3,160 g (maximum 4,950 g, minimum 1,220 g). Preterm (< 37 weeks) delivery occurred in 10% of the cases and low birth weight (< 2,500 g) in 11.4% newborns.

Newborns were classified into three groups: proven or highly probable (13.2%), possible (41.6%) and less likely (45.2%). There were no cases of unlikely congenital syphilis. In the highly probable group, 68.3% of the mothers had an inadequate treatment (p 0.000) and 53.9% were premature (p 0.000). There were five cases of symptomatic congenital syphilis, including three with neurosyphilis. Most (96%) newborns were treated with penicillin (85% intravenously and 11% intramuscularly), 53% had an adequate follow-up and the mean age for a negative VDRL titer was 5.6 months.

Case reports

We report four cases of congenital syphilis. Clinical details are summarized in **Tab. 2**.

Case 1

A twenty-four-year-old healthy woman, Gravida 2 Para 1 (G2P1) with no prenatal care. Premature birth at 35 weeks of gestation, birth weight 2,420 g. Apgar score 8/6/9. The newborn presented at birth with petechial rash, hepatosplenomegaly and generalized edema, evolution to septic shock with disseminated intravascular coagulation and

nephrotic syndrome. Maternal serologies were VDRL 1/32 and TPHA 1/20,480, the same as the newborn. After birth, other congenital infections were excluded: Cytomegalovirus (CMV), Toxo-

Table 1. Maternal demographic and clinical characteristics.

	N	%
Maternal age		
< 20 years	12	3.9
20-34 years	216	71
≥ 35 years	76	25
Unknown	6	1.9
Level of education		
Illiterate	6	1.9
Primary school	33	10.6
5 th -6 th grade	42	13.5
7 th -9 th grade	42	13.5
10 th -12 th grade	59	19
College	6	1.9
Unknown	122	39.4
Professional status		
Unemployed	45	14.5
Unqualified work	125	40.3
Technicians	16	5.2
Customer services	62	20
Administrative work	13	4.2
Student	10	3.2
High qualified work	4	1.3
Industry, construction and army	2	0.6
Retired	1	0.3
Unknown	32	10.3
Origin		
Portuguese	109	35.2
African	140	45.2
Brazilian	17	5.5
Eastern European Countries	6	1.9
Unknown	38	12.3
Prenatal care coverage		
Complete	257	82.9
Incomplete/No coverage	53	17.1
Maternal syphilis		
Early	67	21.6
Late	67	21.6
Undetermined	176	56.8
Co-infections		
Yes	46	14.8
No	257	82.9
HIV	20	6.5
Treatment in pregnancy		
Inadequate	146	47.1
Adequate	164	52.9

Table 2. Clinical details of the cases.

	Case 1	Case 2	Case 3	Case 4
Year	2005	2011	2012	2014
Maternal age (y)	24	20	36	27
Risk factors	No	No	Drug abuse/prostitution/ hepatitis B	No
Prenatal care	No	No	No	Yes
Classification of maternal syphilis	Undetermined	Early	Late	Early
Maternal treatment	No	No	No	No
Gestational age (w)	35	32	33	35
Birth weight (g)	2,420	1,820	1,750	2,350
Presenting symptoms	Septic shock, hepatosplenomegaly, anasarca	Dry, scaly skin rash, hepatosplenomegaly	Petechiae, hepatosplenomegaly, microcephaly	Hydrops fetalis, haemorrhagic dyscrasia
Maternal VDRL	1/32	Negative	1/32	1/128
Child VDRL	1/32	1/1,024 Prozone reaction	1/8	1/64
Age of presentation	Birth	Birth	Birth	Birth
Penicillin treatment	14 days	18 days	14 days	14 days
Outcome	Healthy after treatment	Right arm hemiparesis	Healthy after treatment	Cerebral palsy

VDRL: Venereal Disease Research Laboratory.

plasmosis, Rubella, HIV and hepatitis B/C. Radiography of long bones showed metaphyseal bands characteristic of congenital syphilis. Cerebrospinal fluid (CSF) showed no pleocytosis or increased protein levels and VDRL in CSF was negative. Transfontanellar ultrasound was normal. Hepatic enzymes, platelet count and ophthalmology observation were normal. Treatment was completed with 14 days of intravenous penicillin. The patient did not attend any follow-up consultations.

Case 2

A twenty-year-old healthy woman, G2P1, with inadequate prenatal coverage. Premature delivery by urgent cesarean at 32 weeks of gestation, due to fetal distress. Birth weight 1,820 g. Apgar score 2/7/8, needing advanced life support measures. Presented at birth with dry, scaly skin rash on the palms and soles and hepatosplenomegaly. Laboratory tests revealed acute renal insufficiency and thrombocytopenia, VDRL 1/1,024 with a positive TPHA and IgM anti *Treponema pallidum*. After birth, other congenital infections were excluded (CMV, Toxoplasmosis, Rubella, HIV and hepatitis B). CSF examination: pleocytosis, high proteins, and positive VDRL. Transfontanellar ultrasound revealed a lenticulostriatal vasculopathy and periventricular stroke. The magnetic resonance imaging (MRI) confirmed hemorrhagic stroke and

myelination delay of the cerebral hemispheres. Long bone radiography showed epiphyseal osteochondrosis. Ophthalmology observation was normal. At birth maternal VDRL was negative but due to the newborn's result further dilutions were made and the final VDRL titer was 1/64. Treatment was completed with 18 days of intravenous penicillin.

CSF VDRL was negative after 18 days of treatment, and VDRL/TPHA were negative at 11 months. As a sequel he presents hemiparesis of the right arm, which has improved with physical rehabilitation. In this case, both parents were treated.

Case 3

A thirty-six-year-old woman, G2P0, with a history of drug abuse and prostitution, inadequate prenatal coverage, with positive VDRL (1/32) and AgHBs, having received no treatment. Birth at 33 weeks of gestation, birth weight 1,750 g. Apgar score 9/10/10. The newborn presented at birth, with petechial rash, hepatosplenomegaly and microcephaly. After birth, other congenital infections were excluded (CMV, Toxoplasmosis, Rubella, HIV and hepatitis B). A laboratory test revealed thrombocytopenia and positive VDRL and TPHA (1/8; 1/10,240). Urine antigen detection of CMV in the newborn was negative. CSF

showed pleocytosis and increased protein levels with negative VDRL. Transfontanelar ultrasound revealed grade I periventricular hemorrhage, which resolved at 39 days of life. Long bone radiography and ophthalmology observation were normal. Treatment was completed with 14 days of intravenous penicillin. The newborn also received treatment with immunoglobulin for hepatitis B in the first 6 hours of life and the first dose of hepatitis B vaccine. Follow-up without long-term complications/sequels and negative VDRL at 7 months. The patient was adopted and, to our knowledge, the biological parents were not treated.

Case 4

A healthy twenty-seven-year-old woman, A Rh negative, G5P4, with inadequate prenatal coverage (negative VDRL in the first trimester). Premature delivery by cesarean at 35 weeks of gestation, due to fetal distress. Birth weight 2,350 g. Apgar score 3/5/7, needing advanced life support measures. Presented at birth with hydrops fetalis (negative Coombs test) and a petechial rash that evolved to septic shock with multiple organ failure with active early gastric, urinary and central nervous system (CNS) bleeding. Laboratory tests revealed positive maternal and newborn serologies: VDRL 1/128, TPHA 1/1,280 and VDRL 1/64, TPHA 1/640, respectively. After birth, other congenital infections were excluded (CMV, Toxoplasmosis, Rubella, HIV and hepatitis B). Due to the

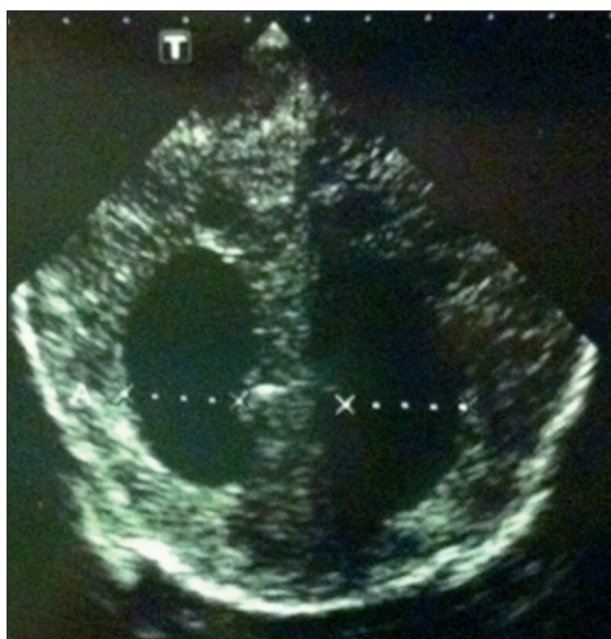

Figure 1. Intraventricular, parenchyma and subarachnoid haemorrhage in the transfontanelar ultrasound of case 4.

hemodynamic instability, lumbar puncture was not performed. Transfontanelar ultrasound revealed an extensive intraventricular, parenchyma and subarachnoid hemorrhage causing an important mass effect that later evolved to multicystic encephalomalacia (**Fig. 1**). The cranial computed tomography confirmed an extensive multicystic encephalomalacia associated with hydrocephaly. (**Fig. 2**) Long bone radiography was normal. Ophthalmology observation showed pale optic discs and vasculopathy. Treatment was completed with 14 days of intravenous penicillin. There was a poor outcome with cerebral palsy currently in palliative care. Both parents were referred to the public health doctor, for follow-up and treatment with very poor compliance.

Three years later (2017), the same mother gave birth to a premature boy at 32 weeks gestation, birth weight 1,900 g, Apgar score 8/8/8. Prenatal coverage was inadequate due to non-compliance to appointments and therapy, having received 1 dose of penicillin. At birth, positive maternal serologies: VDRL 1/64 and TPHA 1/20,480. The newborn presented, at birth, scaly skin rash on the palms and soles and axial hypotonia (**Fig. 3**). Laboratory tests revealed anemia and positive VDRL 1/508 with positive VDRL in CSF. Transfontanelar ultrasound revealed ventriculomegaly. Long bone radiography and ophthalmology observation were normal. Treatment was completed with 14 days of intravenous penicillin. On follow-up at 3 months there was neurologic improvement although transfontanelar ultrasound revealed an augmented ventriculomegaly. He is currently 5 months and will repeat lumbar puncture at 6 months.

Notification to the public health delegate was made after the first sibling with congenital syphilis was born and repeated after the latest. Social

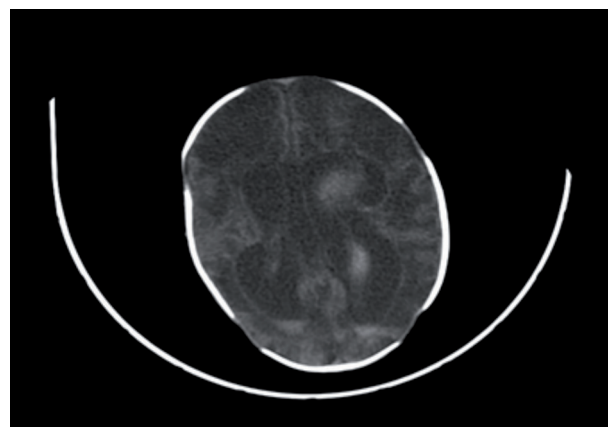


Figure 2. Multicystic encephalomalacia in the cranial tomography of case 4.

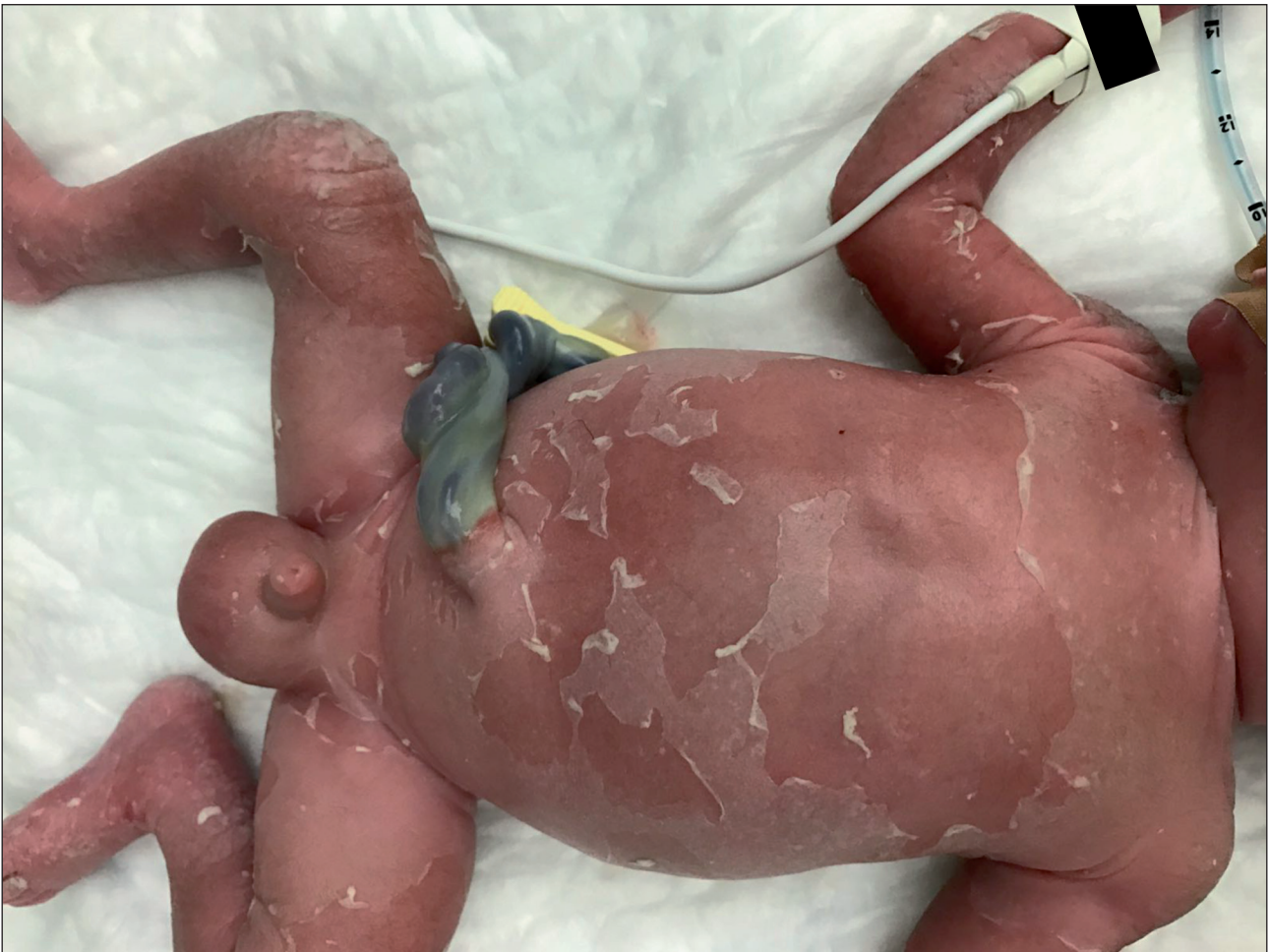

Figure 3. Dry scaly exanthema in the sibling of case 4.

services were also contacted and mother and father were appropriately treated.

Discussion

In 2014, The World Health Organization (WHO) published a program for eliminating mother to child transmission of HIV and syphilis by 2015. The goal was to reduce the number of cases of congenital syphilis to a rate of ≤ 50 cases per 100,000 live births by increasing prenatal coverage, syphilis testing of pregnant women and treatment of syphilis-seropositive pregnant women to $\geq 95\%$ [6]. There is not much data available regarding the incidence of congenital syphilis in Portugal. The last report (2014) from the European Centre of Diseases Control shows an overall European rate of 2.3 cases per 100,000 live birth, Portugal and Bulgaria reporting the highest rates: 12.1 cases per 100,000 (higher than 2013) and 36 cases per 100,000 live births respectively [7]. In our study, 2008 was the year with the highest prevalence risk for congenital syphilis, 0.64%, the highest of the 19

years of the study. When compared with a previous Portuguese study, that reported data relating to the period between 1993 and 2004, the estimated prevalence risk for congenital syphilis was 5.6%, higher than the one of the present study (0.27%) [1]. Although we verified a high percentage of prenatal care coverage, there is still 47.1% of syphilis-seropositive women that received none or inadequate treatment during pregnancy, which is similar to national and international data [1, 8, 9]. Tridapalli et al. highlight the inadequate treatment of syphilis in pregnancy as a major risk factor for congenital syphilis [10]. Our study showed a higher prevalence of maternal syphilis in women originally from Africa or Brazil (50.7%) and 6.5% were co-infected with HIV. Although, we found no significant differences in prenatal care between Portuguese and immigrant mothers, the high prevalence of immigrants suggests that prenatal strategies that aim to increase surveillance and prenatal syphilis testing should include facilitated access to health services and information easily understandable for these mothers.

More than 50% of the newborns were classified as highly probable or possible cases of congenital syphilis. Tridapalli et al. refer a similar percentage, 65%, but a British survey reports only 17 cases in 175 subjects [10, 11]. This could be related to the use of different classification systems.

The severity of the four cases described illustrates the importance of preventing mother to child transmission. Congenital syphilis is associated with late-term stillbirth in 30% to 40% of cases and a higher rate of prematurity/low birth (6%) when compared with mothers without syphilis. Newborns may be asymptomatic or symptomatic [12, 13]. Recent literature reviews indicate that 60% are asymptomatic at birth and two-thirds develop symptoms by 3 to 8 weeks [14]. The four cases described were symptomatic at birth and case 4 presented with hydrops fetalis, a severe and rare complication of congenital syphilis, resulting from anemia-related congestive heart failure associated with a poor outcome [12, 15]. Congenital syphilis should be suspected in a neonate presenting with hydrops fetalis non-related to Rh or ABO isoimmunisation or alpha-thalassemia [15].

Common early signs of congenital syphilis are hepatosplenomegaly and mucocutaneous involvement, classically a maculopapular rash that affects palms and soles and desquamates over a period of 1 to 3 weeks [12]. Skeletal lesions are frequently found in congenital syphilis, predominantly diaphysitis and metaphyseal changes and in 30% of the cases combined lesions: osteitis, periostitis and metaphysitis [16]. Osteochondritis affects primarily knees, ankles, wrists and elbows [12]. We had only one case with the typical rash, but skeletal and osteoarticular lesions were found in half of the cases.

Neurosyphilis can result from dissemination after the neonatal period if the infection is not treated and most often is asymptomatic diagnosed only by an abnormal CSF [12]. Clinical features of congenital neurosyphilis can be divided in: acute syphilitic meningitis, rarely complicated by a vascular involvement in which the middle cerebral artery and its branches are commonly affected; and chronic meningovascular syphilis usually manifesting at the end of the first year. Acute meningitis occurs at the same time as the rash in 10% of the cases, case 3 being an example [17-19]. Three of the cases presented had neurosyphilis, two of them with clinical signs suggestive of CNS involvement and another with

an abnormal CSF and clinical signs of congenital syphilis. We highlight case 2 and 4 for its rare presentation with meningovascular involvement at birth. Case 4 evolved for an extensive multicystic encephalomalacia usually observed in chronic manifestations of neurosyphilis. There are very few cases of neurosyphilis described in the literature. Silva et al. describe the case of a child born to a mother adequately treated: both mother and child had negative VDRL tests, but the newborn was symptomatic at birth (hypotonia and seizures) and a positive PCR for *Treponema pallidum* in CSF confirmed neurosyphilis [20]. An abnormal CSF suggestive of neurosyphilis may include: a reactive VDRL, pleocytosis defined as > 25 white blood cells and increased protein levels (> 150 mg/dL in term neonates and > 170 mg/dL in premature neonates) [2]. However, a recent observational study supports the evidence that CSF VDRL test, white-cell count, and measurement of protein content have low sensitivity to detect congenital neurosyphilis and suggests the use of PCR as a more sensitive and specific method [21]. Case 3 had a negative VDRL in CSF with pleocytosis and increased protein levels and clinical signs of early congenital syphilis suggesting that it was most probably a false negative. Darkfield tests or PCR are not available in our hospital. In case of untreated mothers that give birth to newborns exhibiting signs of congenital syphilis, despite the absence of a positive VDRL in CSF or neurological symptoms, the newborns should be treated as a presumed neurosyphilis due to the risk of later manifesting irreversible signs of congenital neurosyphilis [2]. Mental retardation, hydrocephalus, seizures, cranial nerve palsies and paresis are late manifestations of congenital syphilis [22]. Case 4 is an example of severe complications of congenital neurosyphilis.

As stated before in this study, non-treponemal tests, as VDRL, are used for screening of maternal syphilis. False negatives can occur in three situations: testing long after treatment, late-latent syphilis and the prozone phenomenon. This phenomenon occurs when the amount of antibody in a particular serum sample is too high to allow the formation of the antibody-antigen complex necessary to visualize flocculation or agglutination [23]. A recent study showed a low incidence (0.83%) of this phenomenon and a higher prevalence of prozone phenomenon in pregnancy and neurosyphilis [24]. Case 2 is an example of this phenomenon.

The last case presented is an example of the failure of the prenatal coverage. Notification to the public health system was made after the first sibling with congenital syphilis was born; nevertheless, the system failed to prevent the second case within the same family.

Limitations of this analysis include the retrospective nature of the study and limitations in the selection of the sample, as we did not analyze stillbirths possibly related to congenital syphilis. We would like to point out the inability to differentiate in this study if inadequate treatment of the mothers was due to a failure in diagnosis, treatment, or parental compliance.

Despite appropriate prenatal care coverage, there is still a significant percentage of inadequately treated women and highly probable cases of congenital infection, highlighting the importance of alerting physicians to the disease and adequate treatment and follow-up of maternal syphilis. Due to the elevated prevalence of maternal syphilis among the African communities in the area of our hospital, we suggest a personalized approach to increase prenatal coverage and treatment facilitating access to these women and their partners to the health system. More epidemiological studies regarding prenatal care in Portugal are needed in order to access general knowledge about maternal syphilis screening and treatment, so that risk groups are identified and the incidence of congenital syphilis is reduced. Congenital syphilis with neurologic involvement is a rare and very severe manifestation of the disease. We presented 3 representative cases of neurosyphilis at birth, showing the importance of a high level of clinical suspicion since CSF abnormalities can be unspecific.

Declaration of interest

The Authors declare that there is no conflict of interest. No financial support was given.

References

- Jacinto S, Henriques M, Ferreira T, Carvalhosa G, Costa T, Valido AM. Congenital syphilis still exists! A 12-years retrospective analysis of a reference maternity. *Acta Paediatr Port.* 2007;38(2): 65-8.
- Centers for Disease Control and Prevention [Internet]. Sexually transmitted diseases treatment guidelines. Available at: <https://www.cdc.gov/std/tg2015/>, date of publication: 2015, last access: October 1, 2017.
- Domingues RMSM, Leal, MC. [Incidence of congenital syphilis and factors associated with vertical transmission: data from the Birth in Brazil study]. [Article in Portuguese]. *Cad Saúde Pública.* 2016;32(6):e00082415.
- Direção-Geral da Saúde. Programa Nacional para a Vigilância da Gravidez de Baixo Risco. Lisboa: DGS, 2015.
- Direção-Geral da Saúde. Norma DGS n° 037/2011 de 30/09/2011 atualizada a 20/12/2013. Lisboa: DGS, 2013.
- World Health Organization. Global guidance on criteria and processes for validation: elimination of mother-to-child transmission (EMTCT) of HIV and syphilis. Geneva: World Health Organization, 2014.
- European Centre for Disease Prevention and Control (ECDC). Annual epidemiological report 2014 – sexually transmitted infections, including HIV and blood-borne viruses. Stockholm: ECDC, 2015.
- Feliz MC, Prizybicien AR, Rossoni AM, Tahnus T, Pereira AMVB, Rodrigues C. Adherence to the follow-up of the newborn exposed to syphilis and factors associated with loss to follow-up. *Rev Bras Epidemiol.* 2016;19(4):727-39.
- Magalhães M, Basto L, Areia AL, Franco S, Malheiro ME, Afonso ME. Syphilis in Pregnancy and Congenital Syphilis: Reality in a Portuguese Central University Hospital. *Rev Bras Ginecol Obstet.* 2017;39:265-72.
- Tridapalli E, Capretti MG, Reggiani MLB, Stronati M, Faldella G; The Italian Neonatal Task Force of Congenital Syphilis for the Italian Society of Neonatology – Collaborative Group. Congenital syphilis in Italy: a multicenter study. *Arch Dis Child Fetal Neonatal Ed.* 2012;97:F211-3.
- Simms I, Tookey PA, Goh BT, Lyall H, Evans B, Townsend CL, Fifer H, Ison C. The incidence of congenital syphilis in the United Kingdom: February 2010 to January 2015. *BJOG.* 2017;124:72-7.
- Woods CR. Syphilis in Children: Congenital and Acquired. *Semin Pediatr Infect Dis.* 2005;16:245-57.
- Gomez G, Kamb ML, Newman LM, Mark J, Broutet N, Hawkes SJ. Untreated maternal syphilis and adverse outcomes of pregnancy: a systematic review and meta-analysis. *Bull World Health Organ.* 2013;91:217-26.
- Herremans T, Kortbeek LD, Notermans W. A review of diagnostic tests for congenital syphilis in newborns. *Eur J Clin Microbi Infect Dis.* 2010;29(5):495-501.
- Tan KL. The re-emergence of early congenital syphilis. *Acta Paediatr Scand.* 1973;62:601-7.
- Rassol ML, Govender S. The skeletal manifestations of congenital syphilis. A review of 197 cases. *J Bone Joint Surg.* 1989;71-B:752-5.
- Simon RP. Neurosyphilis. *Arch Neurol.* 1985;42:606-13.
- Wiggelinkhuizen J, Med M, Mason R. Congenital Neurosyphilis and Juvenile Paresis. A Forgotten Entity? *Clin Pediatr.* 1980;19(2): 142-45.
- Wolf B, Kalangu K. Congenital neurosyphilis revisited. *Eur J Pediatr.* 1993;152:493-5.
- Silva S, Henriques R, Gomes JP, Borrego MJ, Afonso E. Could we miss congenital neurosyphilis? *Lancet Infect Dis.* 2012;12:816.

21. Michelow IC, Wendel GD Jr, Norgard MV, Zeray F, Leos K, Alsaadi R, Sánchez PJ. Central Nervous System Infection in Congenital Syphilis. *N Engl J Med.* 2002;346(23):1792-8.
22. Arnold SR, Ford-Jones EL. Congenital syphilis: A guide to diagnosis and management. *Pediatr Child Health.* 2000;5(8):463-9.
23. Berkowitz K, Baxi L, Fox HE. False-negative syphilis screening. The prozone phenomenon, nonimmune hydrops, and diagnosis of syphilis during pregnancy. *Am J Obstet Gynecol.* 1990;163:975-7.
24. Liu LL, Lin LR, Tong ML, Zhang HL, Huang SJ, Chen YY, Guo XJ, Xi Y, Liu L, Chen FY, Zhang YF, Zhang Q, Yang TC. Incidence and risk Factors for the Prozone Phenomenon in Serologic Testing for Syphilis in a Large Cohort. *Clin Infect Dis.* 2014;59(3):384-9.