

# Hyponatremic hypertensive syndrome secondary to renal ischemia – Case report

Joana Cunha Oliveira<sup>1</sup>, Mariana Matos Martins<sup>2</sup>, Esmeralda Martins<sup>3</sup>, Gustavo Rocha<sup>4</sup>, Cláudia Moura<sup>5</sup>, Helena Pinto<sup>6</sup>, Ana Teixeira<sup>6</sup>

<sup>1</sup>Pediatrics Unit, Hospital de Braga, Braga, Portugal

<sup>2</sup>Pediatrics Unit, Hospital Pedro Hispano, Matosinhos, Portugal

<sup>3</sup>Metabolic Diseases Unit, Serviço de Pediatria, Centro Hospitalar São João, Porto, Portugal

<sup>4</sup>NICU, Centro Hospitalar São João, Porto, Portugal

<sup>5</sup>Pediatric Cardiology Unit, Centro Hospitalar São João, Porto, Portugal

<sup>6</sup>Pediatric Nephrology Unit, Pediatric Unit, Centro Hospitalar São João, Porto, Portugal

## Abstract

Hyponatremic hypertensive syndrome (HHS) is characterized by hypertensive crisis, and hyponatremia secondary to unilateral renal damage with glomerular and tubular dysfunction. Elevated plasma levels of renin in most cases suggest that the stimulation of renin release from the ischemic kidney plays an important pathophysiologic role. Activation of the renin-angiotensin system results in hypertension and causes secondary hyperfiltration, pressure diuresis and sodium loss from contralateral non-damaged kidney. An elevated renin level is a pathognomonic finding in HHS. Potassium deficiency from hyperaldosteronism may further stimulate renin secretion and intensify this vicious circle.

We report a female term newborn, who presented with hypertensive crisis on the seventh day after traumatic birth. The first three days of life were uneventful. Initial treatment with captopril resulted in severe hypotension and hemodynamic instability. Lab work revealed hyponatremia, hypokalemia, and elevated peripheral renin activity and aldosterone levels. Complementary sonography and magnetic resonance confirmed right adrenal gland hematoma and several ischemic areas in the upper pole of the right kidney. The diagnosis of HHS secondary to renal ischemia was evoked.

HHS is a rare condition in the neonatal period, though still under-recognized. In the neonatal and early infancy period, renovascular disease is the most common cause of secondary hypertension. In this case, there was no sign of vascular disease, the renin-angiotensin system was activated secondary to direct renal ischemia and infarction. The intense renin stimulation and pressure through the contralateral normal kidney results in high pressure natriuresis facilitating a severe volume-depleted state. Although the use of renin-angiotensin system inhibitors is the treatment of choice, it is imperative to re-establish hydration and renal perfusion before starting this antihypertensive medication. We aimed to improve awareness

of HHS diagnosis and prompt treatment, to prevent continuous renal damage and other life-threatening complications.

### Keywords

Hypertension, hyponatremia, hyponatremic hypertensive syndrome, newborn, renin-angiotensin system, tubular dysfunction.

### Corresponding author

Joana Cunha Oliveira, Serviço de Pediatria, Hospital de Braga, Braga, Portugal; email: joana.cunha.de.oliveira@gmail.com.

### How to cite

Oliveira JC, Martins MM, Martins E, Rocha G, Moura C, Pinto H, Teixeira A. Hyponatremic hypertensive syndrome secondary to renal ischemia – Case report. *J Pediatr Neonat Individual Med.* 2018;7(1):e070110. doi: 10.7363/070110.

### Introduction

Hyponatremic hypertensive syndrome (HHS), at first reported in adults, is still considered a rare condition in children [1, 2]. The combination of hypertension and hyponatremia can be observed in a number of disorders [1, 3-5]. In the neonatal period, acute renal failure, renovascular disorders with secondary renal hypoperfusion and ischemia, and renin-secreting tumours must be ruled out [1].

Renovascular hypertension accounts for up to 25% cases of severe hypertension in children [1, 2, 4, 6]. In the Neonatal Intensive Care Unit, renal artery thrombosis secondary to umbilical catheters is the most common cause [6-8]. HHS is a manifestation of severe hypertension related to unilateral renal ischemia and infarction [1, 3, 4, 7]. An excessively stimulated renin-angiotensin-aldosterone system in the ischemic kidney causes hypertension, and a counteracting effect on the contralateral healthy kidney [7-11]. Hyperfiltration and secondary polyuria leading to volume depletion (heavy polyuria) and renal electrolyte loss with natriuresis in the contralateral kidney are the main cause of hypovolemia, also responsible for secondary hyperreninemia, increased angiotensin II, and consequent secondary hyperaldosteronism [7-14]. A vicious cycle of salt and water loss, leading to malignant hypertension [7-14].

We describe the case of a newborn who presented with HHS secondary to unilateral renal

ischemia following a traumatic birth, with no endovascular previous intervention or recognized vascular disease.

### Case report

A three-day-old female newborn, born after a 39 weeks pregnancy complicated by gestational diabetes. Vaginal traumatic delivery complicated with unilateral brachial palsy (Apgar score 7 at first minute, 8 at fifth minute requiring positive pressure re-ventilation and oxygen; birth weight 3,925 g). Transferred on the third day of life from a secondary hospital to Neonatal Intensive Care Unit due to suspected congenital heart disease. She presented respiratory distress, hepatomegaly (4 cm below the right costal grid), systolic murmur, marbled skin and hypoglycaemia (31 mg/dL). An echocardiogram revealed dilatation of the right cavities, left ventricular hypertrophy and global systolic dysfunction. At admission, she was awake and alert but with poor peripheral perfusion and muscular tonus. Blood pressure 124/78 mmHg. With sepsis suspicion, antibiotic therapy was started with ampicillin and gentamicin, plus furosemide. Umbilical venous and peripheral arterial catheters were placed for monitoring and therapy. Red blood cells transfusion was performed (haemoglobin 12.3 g/dL and haematocrit 35%). Abdominal ultrasound showed probable haemorrhage of the right adrenal gland.

On the seventh day of life, there was a progressive respiratory distress requiring mechanical ventilation, severe tachycardia and hypertension (176/121 mmHg); labetalol perfusion (maximum dose 3 mg/kg/hour) was started, with partial response. Combination therapy with captopril was initiated (0.1 mg/kg/dose), followed by severe hypotension and hemodynamic instability needing inotropic dopamine for two days.

Laboratory analysis revealed transient acute renal failure (urea 41 mg/dL, creatinine 1.16 mg/dL), hyponatremia (Na 128 mEq/L), hypochloremia (Cl 86 mEq/L), hypokalemia (K 3.3 mEq/L) and metabolic alkalosis (HCO<sub>3</sub> 28.8 mEq/L), in combination with polyuria (urine output 7 mL/kg/hour).

After volemia and electrolytic abnormalities correction, on the twenty-sixth day of life, the patient stabilized, and continued treatment with captopril (0.2 mg/kg/dose, orally twice daily) for blood pressure normalization.

In this context of hypertensive crisis, an aetiological investigation was carried out. Urinary catecholamine assays and thyroid function were normal, thrombophilia (ATIII, protein C, protein S and homocysteine) and inborn errors of metabolism screen were negative. Peripheral renin activity and aldosterone levels were elevated (renin 79 pg/ml, reference values 5-55; aldosterone 45.8 ng/mL, reference values < 30). There was no evidence of haematuria. Abdominal magnetic resonance imaging (MRI) showed haemorrhage of the right adrenal gland and several areas of contrast hypocaptation in the upper pole of the right kidney. Renal Doppler study confirmed diffuse hypovascularisation of the right kidney upper pole, without right renal artery stenosis. Cerebral ultrasound revealed right subependymal haemorrhage, probably related to birth trauma. Ten days later, MRI showed posterior intraventricular haemorrhage, a small left ventricular right focus, and hematologic remnants along the posterior inter-hemispheric and bilateral pericerebellar fissures in probable correlation to traumatic delivery and hypertension. Fundoscopy was normal.

The patient was discharged home 50 days after admission, continuing treatment with captopril (0.1 mg/kg/day, twice daily). Six months later, with blood pressure normalization, the antihypertensive treatment was progressively decreased and discontinued.

Follow-up echocardiography and central nervous system sonography showed completed recovery. Renal sonography at 18 months maintains renal asymmetry (right kidney 46 mm; left kidney 72 mm). The right kidney has less cortical thickness and increased echogenicity in the upper pole, and diffuse hypovascularisation, suggestive of previous vascular insult. Renal scan confirmed right kidney hypofunction (20.8%), with no dimercaptosuccinic acid uptake on upper pole. At present, the patient is 2 years old, is asymptomatic, has normal blood pressure, and normal psychomotor development.

## Discussion

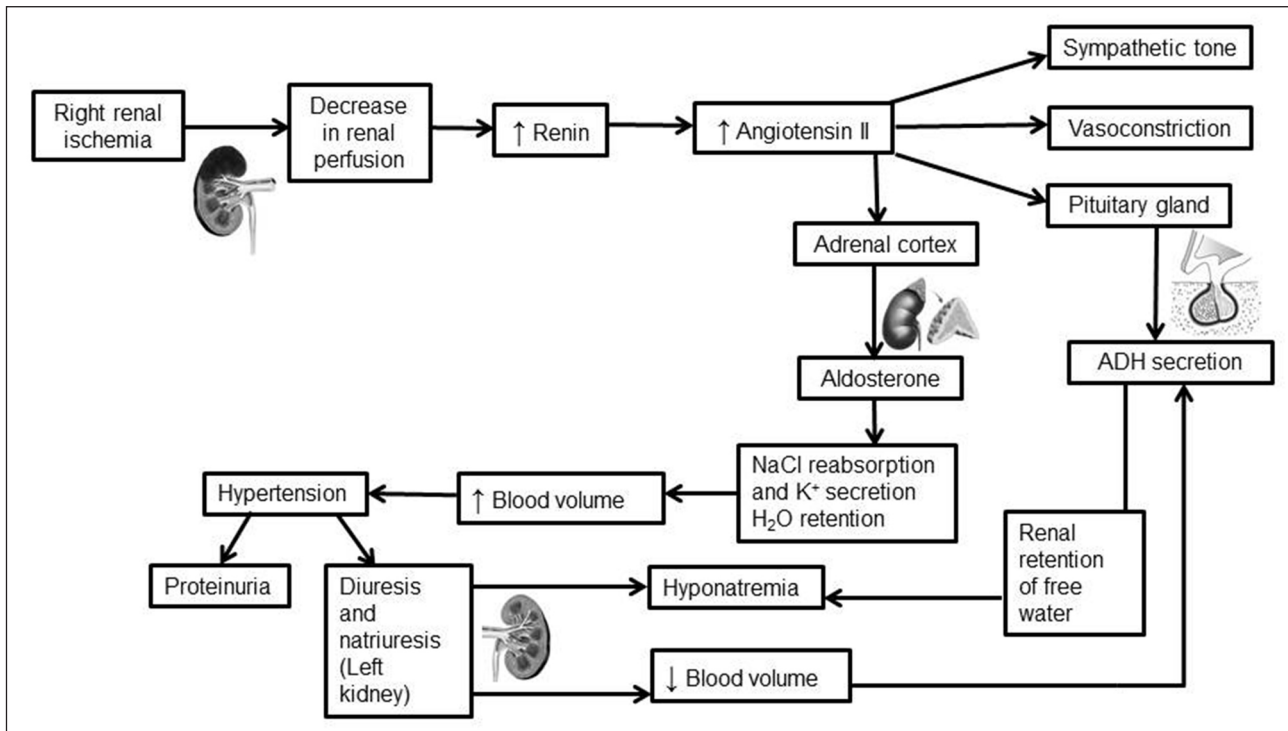
HHS is not such a rare condition in children, especially during the neonatal period [2, 8]. The under-recognition of HHS in children with renovascular hypertension may reflect a lack of knowledge of this entity [1-3, 6, 8, 14]. In this case, there was no sign of vascular disease; right renal ischemia, together with haemorrhage of the

right adrenal gland, was secondary to the traumatic birth. Renal Doppler study confirmed diffuse hypovascularisation of the right kidney upper pole, without right renal artery stenosis.

The pathophysiology of HHS involves a unilateral renovascular disease, the renin-angiotensin system is activated secondary to direct renal ischemia and infarction [2, 5, 6, 9, 13]. An elevated renin level is a pathognomonic finding in HHS [2, 7]. The increased renin secretion leads to high angiotensin II levels, aldosterone secretion and hypertension [4, 5, 8, 13, 14]. An excessively stimulated renin-angiotensin-aldosterone system in the ischemic kidney causes a sudden rise in arterial blood pressure with consequent high pressure natriuresis in the normal functioning contralateral kidney leading to volume depletion and hyponatremia [1, 3, 6-11, 13, 14]. A decrease in intravascular volume causes further release of renin from the hypo-functioning kidney, thus perpetuating a vicious cycle [2, 6]. Hypokalemia, a result of hyperaldosteronism, may further stimulate renin secretion and intensify this cycle [2-4, 8, 13]. This condition is further complicated by the stimulation of thirst and release of ADH (antidiuretic hormone) because of the dual stimuli of angiotensin II and volume depletion (**Fig. 1**) [1, 2, 5, 6, 8]. The metabolic alkalosis is also a consequence of the renin-angiotensin-aldosterone system activation [2, 4, 8]. Proteinuria, sometimes into the nephrotic range, can also be reported in patients with unilateral renal ischemia [2-4, 8]. Angiotensin can be responsible for alterations of both glomerular hemodynamic and intrinsic selective properties of the glomerular membrane [6, 9].

Initial management includes antihypertensives acting on the renin-angiotensin system (mainly angiotensin-converting enzyme inhibitors or angiotensin receptor blocking drugs), though careful volume repletion and adequate renal perfusion are mandatory to avoid first-dose hypotension [1, 6-8, 10, 11]. Except for potent diuretics which may exacerbate the disorder, other additional antihypertensive agents can also be used [6, 8].

Late recognition of HHS without adequate management and treatment can perpetuate hydro-electrolytic disorders and cause severe kidney injury related to ischemia, hypoperfusion and later infarction [6]. The diagnostic delay is also responsible for other end organ damage, as left ventricular hypertrophy, and increases the risk of severe irreversible neurological damage owing



**Figure 1.** Pathophysiology of the hyponatremic hypertensive syndrome (HHS). ADH: antidiuretic hormone.

to the sequential effect of the hypertensive and hyponatremic encephalopathy, aggravated by a diminished cerebral circulation due to hypovolemia [6, 7].

## Conclusion

The presence of hyponatremia and severe hypertension should raise the suspicion of unilateral renal damage, even without renovascular recognized disease [4]. We aim to improve awareness of HHS diagnosis and prompt treatment, to prevent continuous renal damage and other life-threatening complications [2, 4, 6, 7, 11, 13].

This case report emphasizes our current thought that routine screening of blood pressure in the newborn, especially after traumatic birth, any eventful or abnormal neonatal stay, should be recommended. Early recognition of hypertension in the neonatal period can able us to detect most secondary, mainly treatable, and reversible causes.

This report was written for the educational benefit of other medical professionals, and patients best treatment.

## Declaration of interest

The Authors declare that there is no conflict of interest. No financial support.

## References

- Pandey M, Sharma R, Kanwal SK, Chhapola V, Awasthy N, Mathur A, Kumar V. Hyponatremic-Hypertensive Syndrome: Think of Unilateral Renal Artery Stenosis. *Indian J Pediatr.* 2013;80(10):872-4.
- Kovalsku Y, Cleper R, Krause I, Dekel B, Belenky A, Davidovits M. Hyponatremic hypertensive syndrome in pediatric patients: is it really so rare? *Pediatr Nephrol.* 2012;27:1037-40.
- Agrawal M, Lynn K, Richards AM, Nicholls MG. Hyponatremic-Hypertensive Syndrome with Renal Ischemia. An Underrecognized Disorder. *Hypertension.* 1999;33:1020-4.
- Parikh P, Duhame D, Monahan L, Wooniecki R. Renal artery stenosis precipitates hyponatremic hypertensive syndrome and posterior reversible leucoencephalopathy. *Front Pediatr.* 2015;3:40.
- Dixit MP, Hughes JD, Theodorou A, Dixit NM. Hyponatremic hypertensive syndrome (HHS) in an 18-month-old-child presenting as malignant hypertension: a case report. *BMC Nephrol.* 2004;5:5.
- Yilmaz D, Sönmez F, Kaya M, Durum Y, Özkisacik S. Hyponatremic-hypertensive syndrome in an 18-month-old male child. *J Clin Anal Med.* 2015;6(Suppl 6):883-5.
- van Tellingen V, Lilien M, Bruinenberg J, Vries WB. The hyponatremic hypertensive syndrome in a preterm infant: a case of severe hyponatremia with neurological sequelae. *Int J Nephrol.* 2011;2011:406515.
- Rosendahl W, Ranke M, Mentzel H. Sodium loss as leading symptom of renovascular hypertension in the newborn. *Klin Wochenschr.* 1980;58(18):953-4.

9. Micholls M. Unilateral renal ischemia causing the hyponatremic hypertensive syndrome in children – more common than we think? *Pediatr Nephrol.* 2006;21(7):887-90.
10. Uchiyamada J, Meseguer Carrascosa A, Cuñat A, Sanchis Garcia JMM, Dualde-Beltrán D, Dosdá-Muñoz R, Palmero J, Julve Parreño AM. Hyponatremic hypertensive syndrome in childhood. Radiologic Manifestations. Poster No.: C-1923, Congress: ECR 2012. Available at: [http://posterng.netkey.at/esr/viewing/index.php?module=viewing\\_poster&doi=10.1594/ecr2012/C-1923](http://posterng.netkey.at/esr/viewing/index.php?module=viewing_poster&doi=10.1594/ecr2012/C-1923), date of publication: 2012, last access: December 2017.
11. Peco-Antic A. Hyponatremic hypertensive syndrome. *Med Pregl.* 2007;60(Suppl 2):48-52.
12. Machado V, Pontes T, Mota T, Afonso A. [Hyponatremic and hypertensive syndrome in a 4-years-old child]. [Article in Portuguese]. *Acta Pediatr Port.* 2007;38(2):82-4.
13. Daftary AS, Patole SK, Whitehall J. Hypertension-hyponatremia syndrome in neonates: case report and review of literature. *Am J Perinatol.* 1999;16(8):385-9.
14. Bouchier D. Hyponatraemic hypertensive syndrome in two extremely low birthweight infants. *J Paediatr Child Health.* 2003;39:312-4.